

## Manual loop in laparoscopic appendectomy: A retrospective cohort study and literature review

Priyanka Ramesh,<sup>1</sup> Aniq Saeed,<sup>2</sup> Muniza Nusrat,<sup>3</sup> Sehrish Batool,<sup>4</sup> Hina Khan,<sup>5</sup> Ghulam Murtaza<sup>6</sup>

### Abstract

**Objective:** To determine the incidence of complications [Surgical site infection (SSI), intra-abdominal abscess (IAA), stump leak] related to stump ligation with manual loop of sliding extracorporeal suture knot in laparoscopic appendectomy.

**Methods:** This cohort study was conducted on patients who underwent laparoscopic appendectomy from June 2014 to November 2020 performed by the same surgeon with almost similar technique. Stump was ligated with manual loops, applied by the surgeon or trainee or both (one by surgeon and other by trainee). SSI and IAA were classified according to Centers for Disease Control and Prevention (CDC) criteria.

**Results:** Total 120 patients were included with median (Interquartile range, IQR) age of 24 (19-35) years and male predominance i.e. 81 (67.5%). Median (IQR) for the duration of symptoms, time from presentation to surgery and duration of surgery was 2(1-4) days, 10 (4-15) hours and 60 (44-70) minutes, respectively. SSI was documented in 9(7.5%) patients, managed by wound hygiene and antibiotics. IAA was observed in one(0.8%) patient who required readmission for antibiotics and radiology guided drain placement. No stump leak was observed.

**Conclusion:** Manual endo-loop is a safe, reliable and cost effective technique for stump ligation in LA, and can safely be incorporated into teaching of surgical trainees.

**Keywords:** Surgical Site Infection, Intra Abdominal Abscess, Endoloop, Stump leak, Clips, Stapler.

(JPMA 72: S-10 [Suppl. 1]; 2022) DOI: <https://doi.org/10.47391/JPMA.AKU-03>

### Introduction

Acute appendicitis is a common abdominal emergency dealt by general surgeons<sup>1</sup> with cumulative incidence of 7% in general population.<sup>2</sup> Appendectomy is the standard of care. First reported<sup>1</sup> by a German gynecologist Kurt Semm in 1983, laparoscopic appendectomy (LA) has been gaining widespread acceptance due to various reasons i.e. accurate diagnosis, less morbidity and early return to activity. However, the main limiting factors are the equipment (availability & cost), learning curve and surgeons' resistance to acquire a new technique.

Apart from the laparoscopic equipment; trocars (if disposable), energy devices and ligation of the base of appendix determine the cost of treatment. Reusable metallic trocars and bipolar devices can curtail much of the cost. The stump can be dealt with any one of the several ways like staplers, clips (titanium, Hem-o-lok), commercial endo-loop, manual loop, intracorporeal ligation, extracorporeal sliding knot, bipolar cautery and ligasure. The decision of choosing any one of these tools is based on several factors i.e. reliability, cost, technique,

.....  
<sup>1,3-6</sup>Department of General Surgery, Patel Hospital, Karachi, <sup>1</sup>Department of Neurosurgery, Liaquat National Hospital, Karachi, <sup>2</sup>Department of Urology, Aga Khan University Hospital, Karachi, <sup>5</sup>Department of Surgery, Dr. Ruth K. Pfau Civil Hospital, Karachi, Pakistan.

**Correspondence:** Ghulam Murtaza. Email: gms786@gmail.com

duration of surgery and applicability to distended appendix.<sup>3</sup> In a meta-analysis by Antoniou et al.,<sup>4</sup> suture ligation was found superior to others.

Since presently, LA is the first step of a surgical trainee in the world of minimally invasive surgery; a mentor/supervisor has to be vigilant about patient safety and cost. In general, one commercial endo-loop is applied at the base of appendix and supervisor feels comfortable in applying it with himself / herself to avoid a leakage. If one extra endo-loop is applied for the training purpose, it would increase the cost and poses an ethical dilemma. Hence, a manual loop can serve that purpose, where more than one manual loops can be prepared from a single polyglactin (vicryl) suture. Manual loop has been compared to commercial endo-loop with no significant difference in morbidity.<sup>5</sup> This improves the knotting technique as well as hand eye coordination of the trainee while applying the loop and also encourages the mentor to train the future surgeon without additional cost and concerns.

The objective of this study was to determine the incidence of complications (SSI, IAA, stump leak) after appendiceal stump ligation with manual loop of sliding extracorporeal suture knot in laparoscopic appendectomy at a tertiary care hospital.

### Patients and Methods

This cohort study was conducted at the Department of

General Surgery, Patel Hospital Karachi, Pakistan. Patel hospital is 200 bedded; not-for-profit tertiary care hospital and an academic institution with post graduate programme in general surgery and other disciplines. Patients (12 years and above) who underwent LA between June 2014 and November 2020 were included in the study. Exclusion criteria was: a) LA with stump closure other than manual extracorporeal suture knot i.e. intracorporeal knot, stapler or clip; b) conversion to open; c) other concomitant abdominal surgery; d) any other pathology encountered during surgery; e) lost to follow up.

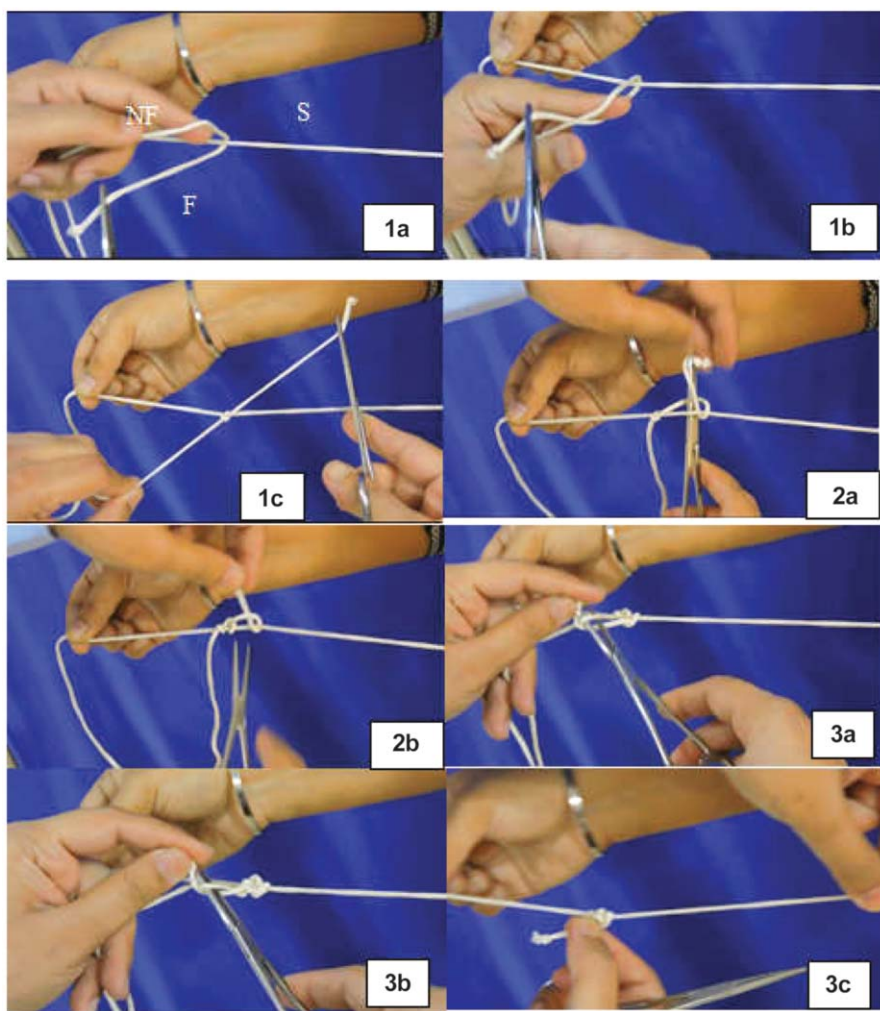
After the approval by Ethical Review Committee of Patel

Hospital Karachi in May 2016, the data collection commenced and had to be continued till December 2020 in order to collect a substantial number of cases. The data of the patients i.e. demographics, operative details, histopathology and clinic follow up were maintained in the HIMS (Hospital Information management System) and intermittently recorded on a proforma by surgical residents.

The cases were performed under general anaesthesia by the same general surgeon with almost a uniform technique. Patient was asked to void just before the procedure. Ceftriaxone (3rd general cephalosporin) was used in majority of patients. After skin preparation with

povidine iodine, a 10-mm optical port was inserted above the umbilicus, followed by a 5-mm port in the suprapubic midline region. The second 10-mm port was inserted either in the midway between the first 2 ports and to the left of the rectus abdominis muscle in left iliac fossa or in right upper quadrant, depending on the body habitus. Patient was placed in Trendelenburg's position with leftward tilt and terminal ileum was swept medially. Appendix was located by either following the ligament of Traeves or taeniae coli. Depending on the variety of findings, the meso-appendix was dealt with combination of blunt dissection, diathermy and clipping. The manual loop with extracorporeal knot on 'O' size polyglycolic acid (Vicryl) suture was prepared by surgeon or trainee as shown in Figure-1. A trainee had to practice the knot till the knot preparation time was within 20 seconds. Manual loops (upto three in number) were applied either by the surgeon or trainee or both (one by surgeon and other by trainee).

Suture knot was pushed via port through a fascial dilator (14F, 25cm, Boston Scientific) or Johan forceps. First loop was tightened around the base of appendix, approximately 2-5mm distal to cecum, with a slow and steady pressure till the appendicular tissues started blanching. In most of the cases, one more loop was applied



**Figure-1:** Showing the steps of manual endo-loop formation.

**Step 1 a-c:** Assistant holds the suture straight and taut (S) with two hands. The surgeon loops the free end of suture around S to create a complete knot between Non Functional (NF) and Functional (F) segments of suture with the help of a fine artery forceps.

**Step 2 a and b:** The surgeon throws two more knots of F around S.

**Step 3 a-c:** The surgeon throws two knots of F around NF and tightens to secure all the previous knots. The surgeon then checks the knot adequacy by sliding it over S.

few millimeters distal to the first one. After transacting the appendix above the sutures, specimen was withdrawn into the 10 mm port and retrieved out of the body. If the specimen was too thick to be retrieved via 10mm port, a glove bag was used to retrieve it after dilating the optical port. Wounds were closed with vicryl 3-0 subcuticular or prolene 3-0 interrupted vertical mattress sutures.

Post operatively, patients were kept nil per os upto 6-24 hours depending on the findings and the course. Antibiotics were discontinued after two post-operative doses in clean cases or continued for three post-operative days in contaminated or dirty cases with frank pus or perforation or gangrene. Daily surgical sites were assessed by the registrar of surgery and/or consultant surgeon till discharge from hospital. Patients were discharged once they were mobilized, passed flatus/stool and tolerated soft diet. After discharge, there was a weekly follow up at the outpatient clinic by the consultant surgeon till the wounds healed completely. If SSI was found in closed wounds, the sutures were removed, daily dressing was done either by the patient, family or a visiting home health care provider till the wound healed completely.

The primary outcome variable was intra-abdominal abscess (IAA) or stump leak. IAA labelled if the patient had persistent fever  $>100^{\circ}$  F, abdominal tenderness, diarrhoea or ileus (vomiting, constipation, abdominal distension and absent bowel sounds); and ultrasound or CT scan reported a fluid collection. Leak was labelled if contrast study (CT scan or follow through) confirmed the stump leak or if stump leakage was confirmed on re-exploration.

The secondary outcome variables were SSI and duration of surgery. SSI was assessed according to criteria of the Centers for Disease Control and prevention (CDC)<sup>6</sup>, within a period of at least 30 days postoperatively. Duration of surgery was recorded as time from incision to dressing.

Data was checked for wild codes and internal consistency with frequency tables and cross tabulations. Continuous variables were analyzed as means  $\pm$  standard deviation for data with normal distribution and median with interquartile ranges for skewed data. Categorical variables were analyzed as proportions and percentages.

## Results

Total of 120 patients were included in the study (Figure-2) with median (Interquartile range, IQR) age of 24 (19-35) years and male predominance i.e. 81 (67.5%). Median (IQR) for the duration of symptoms, time from presentation to surgery and duration of surgery was 2(1-4) days, 10 (4-15) hours and 60 (44-70) minutes,

**Table-1:** Summarizes the baseline and outcome variables of the study cohort (n=120).

<b>Baseline variables</b>	
Age (years) <sup>1</sup>	24 (19-35)
Male gender	81 (67.5%)
Onset of symptoms (Days) <sup>1</sup>	2 (1-4)
<b>Mode of diagnosis</b>	
Clinical	44 (36.7%)
Clinical+ultrasound	38 (31.7%)
Clinical+CT scan	38 (31.7%)
Presentation to start of surgery (hours) <sup>1</sup>	10 (4-15)
<b>Free fluid</b>	
No	67 (55.8%)
Clear/amber	22 (18.3%)
Purulent	29 (24.2%)
Haemorrhagic	2 (1.7%)
Perforation	15 (12.5%)
Gangrene	13 (10.8%)
<b>Adhesions</b>	
No	44 (36.7%)
Flimsy	41 (34.2%)
Dense	35 (29.2%)
Time for manual loop formation <sup>2</sup>	20 $\pm$ 1.9 seconds
<b>Number of manual loops</b>	
Single	20 (16.7%)
Double	96 (80%)
Triple	04 (3.3%)
<b>Wound closure</b>	
Interrupted, non absorbable suture	90 (75%)
Subcuticular, absorbable sutures	30 (25%)
Duration of Surgery (minutes) <sup>1</sup>	60 (44-70)
<b>Final histopathology</b>	
Normal Appendix	1 (0.8%)
Acute appendicitis	114 (95%)
Obliterated lumen, fibrosed appendix	2 (1.7%)
Follicular hyperplasia	3 (2.5%)
<b>Outcome variables</b>	
Superficial SSI	9 (7.5%)
Intra-Abdominal Abscess	1 (0.8%)

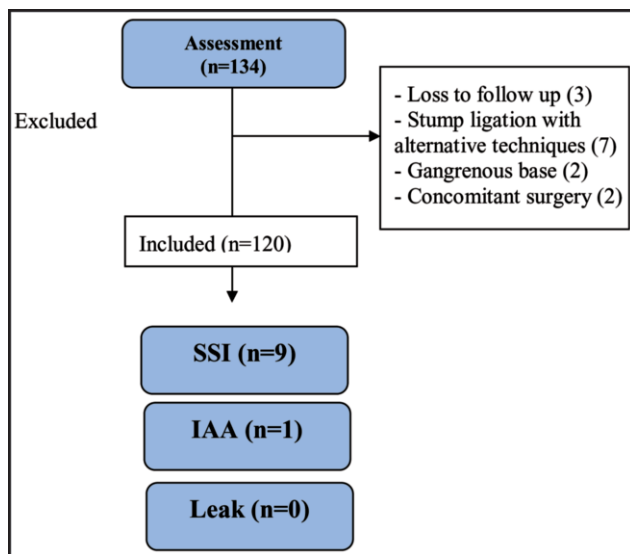
<sup>1</sup>Median (inter quartile range). <sup>2</sup>Mean $\pm$ Standard deviation.  
SSI=Surgical site infection.

respectively (Table-1) Median (IQR) hospital stay was 1 (1-2) days. Average time required to prepare a manual loop was 20 $\pm$ 1.9 seconds.

Nine out of 120 patients developed complications. SSI was documented in 9(7.5%) patients in supra-umbilical port, managed by wound hygiene and antibiotics. One patient, who had perforated appendix with purulent fluid around it, developed SSI as well as IAA at 6th post-operative day. CT scan with oral and intravenous contrast confirmed the IAA without a stump leak, that was managed by radiology guided drain placement. He was readmitted due to a need for intravenous antibiotics (Piperacillin/tazobactam) to cover multi drug resistant

**Table-2:** Summarizing studies on different methods of stump closure in laparoscopic appendectomy.

Study	Groups (sample size)		Complications		Operative time (minutes)		Leak/abscess	
	A	B	A	B	A	B	A	B
Arcovedo et al. <sup>20</sup> (2007) Retrospective	Manual Loop (63)	Stapler (63)	13 (20.6%)	11(17.4%)	77	50	1	0
Yildiz et al. <sup>5</sup> (2009) Prospective	Manual Loop (57)	Endo-loop (41)	2 (3.5%)	3 (7.3%)	44	43	0	0
Sahm et al. <sup>17</sup> (2011) Prospective	Endoloop (1670)	Stapler(46)	--	--	47	76	27 (1.6%)	1(2.2%)
Ates et al. <sup>13</sup> (2012) RCT	Intracorporeal knot tying (31)	Titaneum clip (30)	4 (13%)	6 (20%)	62	41	1	0
Hue et al. <sup>8</sup> (2013) Retrospective	Endoloop (66)	Haem-o-lock (39)	2 (3%)	1(2.5%)	NA	NA	0	0
Rakic et al. <sup>6</sup> (2014)	Endoloop (229)	Stapler (104)	13 (5.6%)	11(10.5%)	48	55	5 (2.1%)	3 (2.8%)
Luchi et al. <sup>10</sup> (2017) Retrospective	Endoloop (158)	Haem-o-lock (121)	2 (1.2%)	3 (2.4%)	40	36	0	0
Our Study (2020)	Manual Loop (120)	-	9 (7.5%)	-	60	-	1 (0.8%)	-

**Figure-2:** Flow diagram of the patients.

organism. Stump leak was not encountered in any of the patients.

## Discussion

In this study, SSI was observed in 7.5% patients after LA with manual loop and IAA in only one patient; neither stump leak nor re-operation was reported in any of the patients; thus, reiterating the safety and cost effectiveness of manual loop

In LA, there are several ways of closing the base of appendix. Different variables are to be considered while choosing the best technique i.e. safety, applicability, duration, reliability and cost. Stapler is easy to use, has the least complications of all and applicable to inflamed appendiceal base; however, the cost limits its utility in most of the healthcare systems.<sup>6,7</sup> Besides, it requires a 12mm port to apply the stapler, which is more costly and painful than a 5mm port. On the other hand, hem-o-lock clips are feasible and cost effective;<sup>8-10</sup> however, in these studies the patients with wide base were ligated with

alternate techniques like stapler or endo-loop and excluded. Hue CS et al found that hem-o-loks are unsafe for severely inflamed appendiceal base >10mm,<sup>8</sup> where it increases the risk of pressure necrosis and leak owing to forceful application to lock the clips.

Titanium clips (TC) are also investigated with results comparable to the suture ligation;<sup>11,12</sup> however, possess the same drawback of hem-o-lock clips especially in a distended, thickened or friable appendix. In the light of a prospective study, the average size of the base of appendix in acute appendicitis was 12mm (ranging from 6 to 23 mm); the authors suggested use of Hem-o-lock or TC for small diameter and endo-loop or staplers for wider ones. Another factor is slippage of TC reported by Ates et al.<sup>13</sup> in a patient with repeated abdominal pain following LA. They also reported one patient with IAA and re-exploration with intact stump in TC group.

In a systematic review, suture ligation was considered superior to other techniques for stump closure.<sup>4</sup> The suture ligation can be performed with any of these techniques i.e. intra-corporeal knotting, needle invagination, commercial endo-loop and manual loop. For the safety and cost effectiveness, Kiudelis M<sup>14</sup> stated that intra-corporeal invagination is cheaper than endo-loop but it increases the duration of surgery. Also it requires expertise of intra-corporeal knot tying and the pressure of knot varies from person to person i.e. it may be too tight a knot to cut through the tissues or a loose knot that makes the stump prone to leak.

The manual loop requires a short period of training and its application is smooth and controlled. The knot does not loosen after application and can be applied to any type and size of appendix as shown in our study. It requires an average of 20±1.9 seconds to prepare a knot. One commercial endo-loop costs around 80 USD and applying two loops means 160 USD. On the other hand, one vicryl suture is around 4USD and as many as four loops can be prepared from a single suture. Therefore, manual loop is a

safe, reliable and cost effective technique of stump closure<sup>5,15-17</sup> with a negligible rise in operative time i.e. 40 seconds for two loops in our study. Moreover, these manual loops can also be used in other areas i.e. gallbladder, fallopian tube.

Manual loop can be slipped through several instruments i.e. through the fenestrated prongs of Johan forceps,<sup>18</sup> a fascial dilator or laparoscopic metallic knot pusher. We used one fascial dilator in as many as 10 cases after re-sterilization with ETO (Ethylene Oxide) or CIDEX (Activated Glutaraldehyde). One possible reservation would be a theoretical risk of SSI following reuse of a disposable fascial dilator. We observed Superficial SSI in 7.5% patients, which is well within the range reported in a systematic review on appendectomy.<sup>19</sup> However, if a new disposable 14 F fascial dilator is used every time, it would cost 3-5 USD per case; which is still much lower vis-à-vis commercial endoloops.

As the strengths of this study, all the procedures were performed and followed by a single surgeon with a uniform technique and postoperative follow up. The data from June 2014 to May 2016 was collected retrospectively after ERC approval, while the data collection continued till December 2020 to collect a substantial number of cases. The limitation of the study was not having calculated the sample size according to statistical methods. However, a multi-center and effectiveness randomized controlled trial, adequately powered by a priori sample size calculation, having direct comparison of manual loop with commercial endo-loop, and involvement of various surgeons and trainees at different levels is required to reach at an evidence based conclusion and recommendation.

## Conclusion

In conclusion, the stated facts, figures and logical reasoning corroborate that almost all the methods of stump closure are safe and effective. However, manual loop is additionally cost effective, reproducible, trainee friendly and readily available tool. These qualities encourage a surgeon to adopt it in the day to day practice as well as teach and train without any additional cost of healthcare or risk to the patient.

## Highlights

- Manual loop is safe, cost effective, trainee friendly and reproducible tool to secure appendicular stump in Laparoscopic appendectomy.

It encourages a surgeon to adopt it in the day to day practice as well as teach and train without any additional

cost of healthcare or risk to the patient.

**Acknowledgements:** Dr. Hassaan Khan Niazi & Aniq Saeed for file review, Ms. Bushra for data entry.

**Disclaimer:** None

**Conflict of Interest:** None

**Source of Support:** None

## References

1. Eubanks S, Phillip S. L Laparoscopic Appendectomy. In: Fischer JE, editor. *Mastery of Surgery*. 5 ed: Lippincott Williams & Wilkins; 2007. p. 1607-09.
2. Vellani Y, Bhatti S, Shamsi G, Parpio Y, Ali TS. Evaluation of laparoscopic appendectomy vs. open appendectomy: a retrospective study at Aga Khan University Hospital, Karachi, Pakistan. *J Pak Med Assoc*. 2009;59:605-8.
3. Mayir B, Ensari CO, Bilecik T, Aslaner A, Oruc MT. Methods for closure of appendix stump during laparoscopic appendectomy procedure. *Ulus Cerrahi Derg*. 2015;31:229-31.
4. Antoniou SA, Mavridis D, Hajibandeh S, Antoniou GA, Gorter R, Tenhagen M, et al. Optimal stump management in laparoscopic appendectomy: A network meta-analysis by the Minimally Invasive Surgery Synthesis of Interventions and Outcomes Network. *Surgery*. 2017;162:994-1005.
5. Yildiz F, Terzi A, Coban S, Zeybek N, Uzunkoy A. The handmade endoloop technique. A simple and cheap technique for laparoscopic appendectomy. *Saudi Med J*. 2009;30:224-7.
6. Rakic M, Jukic M, Pogorelic Z, Mrklic I, Klicek R, Druzijanic N, et al. Analysis of endoloops and endostaples for closing the appendiceal stump during laparoscopic appendectomy. *Surg Today*. 2014;44:1716-22.
7. Makaram N, Knight SR, Ibrahim A, Patil P, Wilson MSJ. Closure of the appendiceal stump in laparoscopic appendectomy: A systematic review of the literature. *Ann Med Surg (Lond)*. 2020;57:228-35.
8. Hue CS, Kim JS, Kim KH, Nam SH, Kim KW. The usefulness and safety of Hem-o-lok clips for the closure of appendicular stump during laparoscopic appendectomy. *J Korean Surg Soc*. 2013;84:27-32.
9. Varghese G. Feasibility and Efficacy of Using Hem-o-lok Polymeric Clips in Appendicular Stump Closure in Laparoscopic Appendectomy. *Cureus*. 2018 ;10:e2871.
10. Lucchi A, Berti P, Grassia M, Siani LM, Gabbianelli C, Garulli G. Laparoscopic appendectomy: Hem-o-lok versus Endoloop in stump closure. *Updates Surg*. 2017 ;69:61-5.
11. Strzalka M, Matyja M, Rembiasz K. Comparison of the results of laparoscopic appendectomies with application of different techniques for closure of the appendicular stump. *World J Emerg Surg*. 2016;11:4.
12. Gonenc M, Gemici E, Kalayci MU, Karabulut M, Turhan AN, Alis H. Intracorporeal knotting versus metal endoclip application for the closure of the appendiceal stump during laparoscopic appendectomy in uncomplicated appendicitis. *J Laparoendosc Adv Surg Tech A*. 2012;22:231-5.
13. Ates M, Dirican A, Ince V, Ara C, Isik B, Yilmaz S. Comparison of intracorporeal knot-tying suture (polyglactin) and titanium endoclips in laparoscopic appendiceal stump closure: a prospective randomized study. *Surg Laparosc Endosc Percutan Tech*. 2012;22:226-31.
14. Kiudelis M, Ignatavicius P, Zviniene K, Grizas S. Analysis of intracorporeal knotting with invaginating suture versus

- endoloops in appendiceal stump closure. *Wideochir Inne Tech Maloinwazyjne*. 2013;8:69-73.
15. Mayir B, Bilecik T, Ensari CO, Oruc MT. Laparoscopic appendectomy with hand-made loop. *Wideochir Inne Tech Maloinwazyjne*. 2014;9:152-6.
  16. Elgendy A, Khirallah MG. Hem-o-lok clip versus hand-made loop in base closure during laparoscopic appendectomy in children. *J Pediat Endoscopic Surg*. 2019;1:127-32.
  17. Sahm M, Kube R, Schmidt S, Ritter C, Pross M, Lippert H. Current analysis of endoloops in appendiceal stump closure. *Surg Endosc*. 2011;25:124-9.
  18. Siddique K, Siddiqi N, Sedman P. Use of Johan forceps as endoloop pushers for laparoscopic appendectomy. *Ann R Coll Surg Engl*. 2012;94:533-4.
  19. Danwang C, Bigna JJ, Tochie JN, Mbonda A, Mbanga CM, Nzalie RNT, et al. Global incidence of surgical site infection after appendectomy: a systematic review and meta-analysis. *BMJ Open*. 2020;10:e034266.
  20. Arcovedo R, Barrera H, Reyes HS. Securing the appendiceal stump with the Gea extracorporeal sliding knot during laparoscopic appendectomy is safe and economical. *Surg Endosc*. 2007;21:1764-7.
-