

## Low cost reconstructive options after musculoskeletal tumour resection in developing countries. Affordable, effective and durable alternatives

Arif Ali, Obada Hasan, Ahmed Habib, Masood Umer

### Abstract

Over the last two, three decades, the overall survival rates for non-metastatic malignant tumours of the bone have dramatically improved. This has become possible due to the recent advances and multidisciplinary approach towards these diseases, specifically the advent of multi-agent chemotherapy and radiotherapy. Limb salvage has now become the norm in the treatment of musculoskeletal tumours without compromising on the overall survival and recurrence of the disease. In the era of metal, prosthetic reconstruction has become the standard procedure specifically in the large tumours which involve the joints as this method of reconstruction helps in joint mobility and early weight-bearing. Considering the costs and resource constraints, multiple cost-effective, stable, durable reconstruction options have evolved over the last decade and these have also shown favourable functional outcomes without compromising on the amount of resection and risk of local recurrence. The current literature review was planned to discuss various cost-effective, durable reconstructive options and their advantages and disadvantages. These include Van ness rotationplasty, allograft, autograft, devitalised tumour bone and Masquelet or induced membrane technique.

**Keywords:** Musculoskeletal, Tumour, Orthopaedic, Oncology, Reconstruction, Developing country

### Introduction

We have seen rapid strides in the field of musculoskeletal oncology in the last two decades. Limb salvage surgeries are now the standard operations due to the multidisciplinary approach, without compromising on overall disease survival.<sup>1,2</sup> Specialised orthopaedic oncology services, indigenous prostheses and the development of tissue banking have made limb salvage affordable.<sup>3</sup>

Department of Surgery, Aga Khan University, Karachi, Pakistan

**Correspondence:** Obada Hasan. e-mail: obada.husseinali@aku.edu

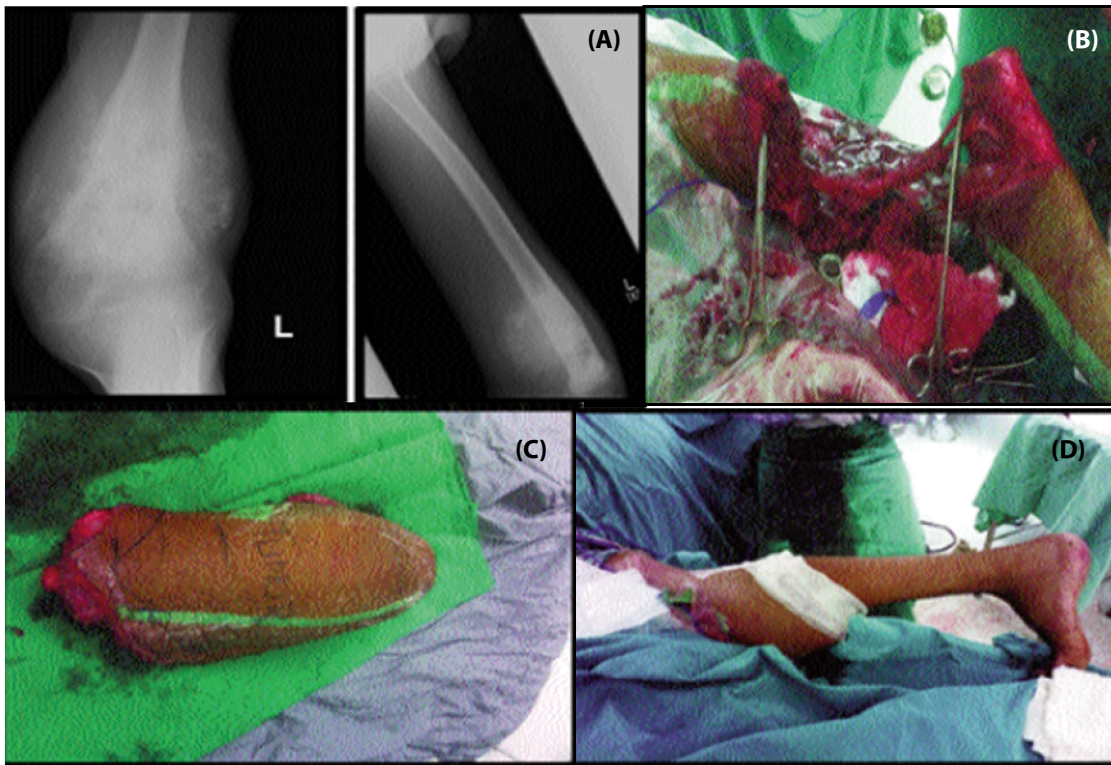
Use of endoprosthesis for reconstruction has advantage of early rehabilitation and weight-bearing. Aseptic loosening and revision surgeries are the problems frequently encountered in young patients. Implant infection is another challenging problem encountered.<sup>4,5</sup> The cost of mega-prosthesis on average is more than 1.5 million Pakistani rupees (PKR) which is usually out of the reach for most of the population. In the face of these affordability issues, multiple low-cost reconstructive options have been evolved over the years to make limb salvage a viable option in developing countries.<sup>6,7</sup> Reconstruction options include Van ness rotationplasty (usually in young children), allografts, autografts (vascularised or non-vascularised), use of devitalised tumour-bearing bone, and Masquelet technique.<sup>5,8-13</sup> Van ness rotationplasty is biological reconstruction in skeletally immature patients and it is usually done in the tumours which involve the area of distal femur and proximal tibia region. Allograft is usually effective in patients who have intercalary defects after tumour resection. Autograft is one of the most commonly used methods for reconstruction of bone defects after the resection. Another effective low-cost option is the use of the same tumour bone after the tumour has been irradiated from them. Induced membrane technique, also known as Masquelet technique, is another alternative for reconstruction done in two stages.

The current literature review was approved by the ethical review committee of Aga Khan University Hospital (AKUH), Karachi, and informed consent is always taken from the patients for using clinical data under all circumstances.

### Literature Review

#### Van ness rotationplasty

It is durable biological reconstruction after tumour resection in skeletally immature patients after an intercalary limb resection. It is usually done in the tumours which involve the area of distal femur and proximal tibia region. In this



**Figure-1 (A) (B) (C) (D):** (A) Preoperative X-ray showing the tumour involving the distal femur. (B) Intraoperative picture of tumour resection. (C) Postoperative X-ray of resected specimen. (D) Postoperative picture after van ness rotationplasty.

procedure after the tumour resection distal limb is rotated 180 degrees and it is fixed with the proximal part and by this way ankle works as the knee joint. Dorsiflexion of ankle acts as flexion and plantar flexion acts as extension of the knee joint. Below-knee prosthesis then can be fitted into the limb<sup>11</sup> (Figure 1).

A study with more than a decade of follow-up in patients undergoing rotationplasty stated that there was no problem is psychological adaptation and similar happiness as in healthy persons.<sup>14</sup> Another long-term follow-up study concluded that patients after rotationplasty have a reasonably good quality of life and they are satisfied regarding their daily activities of life.<sup>15</sup>

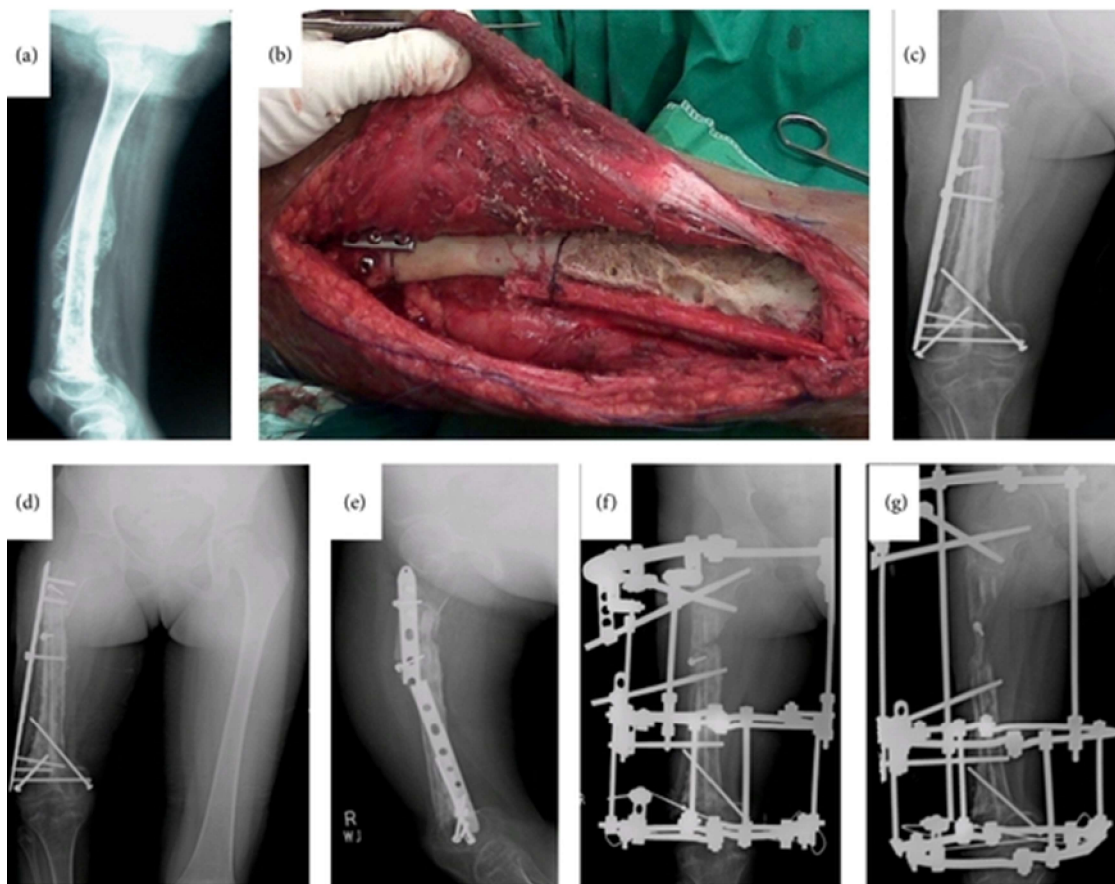
### Allograft reconstruction

It is usually effective in patients who have intercalary defects after tumour resection (intercalary defect is defined as the resected metaphyseal or diaphyseal part of the bone which does not involve the joint). Multiple studies done in recent years have reported good clinical outcomes of allograft reconstruction and there has not been much difference in outcomes of allograft vs. endoprosthetic reconstruction.<sup>16,17</sup>

Apart from its advantages, there are some limitations with the use of allografts. For allografts one needs to have a developed bone bank for its usage and storage, and these facilities are usually not available in most of the developing countries due to lack of resources. Another challenge is, like organ donations, bone donations are also difficult to obtain due to religious and social barriers. Risk of transmission of disease is associated with allografts. Exclusive use of allografts can have complications like fracture, non-union and resorption of the graft, so the current practice is that allograft is generally used in combination with endoprosthesis, or a combination of allograft and autograft are used to provide more stability.<sup>18</sup> A study showed that the use of parental allograft in paediatric patients had no tissue reaction locally or systemically.<sup>8</sup>

### Autograft

Most common autograft used for reconstruction is fibula. It is used as both vascularised and non-vascularised. Articular geometry of the head of fibula is somewhat similar to that of the distal radius and that is why it is the most



**Figure-2:** A 10-year-old girl with Ewing's sarcoma. (a) Suspicious lesion in mid and distal right femur with periosteal reaction and extending to soft tissue. (b) Intraoperative picture after placing the autoclaved bone and augmented with fibular graft. (c) Immediate postoperative X-ray (d) 26-month postoperative X-ray shows graft and bone union at both distal and proximal ends; however, there is considerable shortening of right femur. (e) Breakage of locking compression plate (f). Considering the limb length discrepancy and plate breakage, patient underwent Ilizarov application to right femur. (g) One year post-Ilizarov X-ray showing 2.5cm gain in right femur length.

common bone to be used for reconstruction of the articular surface of the distal radius after resection of tumours. Isolated vascularised or non-vascularised fibula usually provides adequate strength in reconstruction of the bones of upper limb i.e. proximal humerus and distal radius as these are usually the non-weight-bearing areas, but in lower extremity weight-bearing areas, they are usually used in combination with allografts, because they are associated with fatigue fracture, non-union and resorption of the graft if used in isolation.<sup>19</sup> Bilateral vascularised fibula graft has also been utilised for the reconstruction of lower extremity after tumour resection.<sup>20</sup> Use of vascularised and non-vascularised fibular graft and strut iliac crest graft is used commonly for the arthrodesis of the wrist.

#### Devitalised Tumour Bone

Another exciting low-cost option is the use of the same tumour bone after the tumour has been irradiated from them as a result of some forms of treatments such as radiotherapy (extra-corporeal radiotherapy), pasteurisation, autoclaving, liquid nitrogen and microwave. These techniques are very useful in conditions which preclude the use of an allograft, such as there is no requirement of a blood bank and usually there is no problem in the match of the graft size as it has been taken from the same defect area and there is no risk of disease transmission.<sup>21</sup> It consists of excision, sterilisation and re-implantation. After the resection of the tumour, bone is taken out and soft tissue attachments are stripped out. Bone can be sterilised by different methods as described above. Sterilised bones are

**Table:** Common complications of different re-constructive options.

Method	Author/year	Patients	Complications
Van-ness rotationplasty	Sawamura et al (2008)(27, 28)	25	3 patients underwent amputation due to vascular compromise, one infection and one developed non union
Allograft	Gharedaghi M et al (2016)(18)	113	Deep infection <sup>8</sup> Fracture <sup>6</sup> Local recurrence <sup>6</sup>
Auto-graft	Ghoneimy et al (2018)(29)	41	Fracture (12) Non union <sup>5</sup>
Devitalized tumour bone	H Qu et al (2015)(30)	27	Non union <sup>4</sup> Fracture <sup>1</sup> Deep infection <sup>3</sup>
Masquet technique	X Wang et al (2016)(31, 32)	33	Infection <sup>5</sup>

then fitted back in the defect and stabilised with intramedullary (IM) nails or plates. A study done<sup>13</sup> included 40 paediatric patients who underwent reconstruction with autoclaved tumour-bearing bone after resection of the tumour and 2 patients had local recurrence. Local recurrence was due to aggressive disease nature. Distraction osteogenesis utilising Ilizarov apparatus can be added if there is significant shortening (Figure 2).

Multiple studies using different procedures like pasteurisation,<sup>22</sup> freezing<sup>23</sup> and extracorporeal irradiation<sup>24</sup> have shown good clinical and functional outcomes without compromising on the resection and risk of recurrence of the disease.

#### **Masquelet Technique (Induced membrane technique):**

Induced membrane technique, also known as Masquelet technique, is another alternative for reconstruction and in recent years it has gained more popularity. It is done in two stages. In the first stage, after the resection of bone, the defect is filled with cement spacer for stabilisation and soft tissue repair is done. As there is formation of biological membrane over a few weeks, after cement spacer is removed four to six weeks later, corticocancellous bone graft is placed. The biological membrane formed possesses rich capillary network and has adequate concentration of growth and osteo-inductive factors.<sup>25</sup> The disadvantage with this procedure is requirement of two surgical interventions.

As a rule of thumb, managing musculoskeletal tumours require a highly experienced team in this field to give the best outcome.<sup>3,26</sup>

Complications of the different reconstructive options were

reviewed separately.<sup>18,27-32</sup>

#### **Conclusion**

Reconstruction after tumour resection has always been a challenging task for surgeons. Different biological and non-biological options have evolved over the last two decades, leading to about 80% tumour surgeries being done with limb salvage. Selection of the reconstructive procedure should be based on the involved bone area, amount of resection done and availability of infrastructure and bearing cost issues in mind. Biological methods are more cost-effective and provide durable reconstruction options in properly selected patients. Low-cost reconstructive options provide hope to tumour patients in underdeveloped countries where infrastructure and cost constraints rule out costly prosthesis after tumour resection

**Disclaimer:** None.

**Conflict of Interest:** None.

**Source of Funding:** None.

#### **References**

- Mason GE, Aung L, Gall S, Meyers PA, Butler R, Krüg S, et al. Quality of life following amputation or limb preservation in patients with lower extremity bone sarcoma. *Front Oncol* 2013;3:210. doi: 10.3389/fonc.2013.00210.
- Byregowda S, Puri A, Gulia A. Biological methods of reconstruction after excision of extremity osteosarcoma. *J Bone Soft Tissue Tumors* 2016;2:5-9.
- Hasan O, Zubairi A, Nawaz Z, Umer M. Establishing musculoskeletal oncology service in resource constrained country: challenges and solutions. *Int J Surg Oncol (N Y)* 2017;2:e50. doi: 10.1097/IJ9.000000000000050.
- Racano A, Pazionis T, Farrokhhyar F, Dehesi B, Ghert M. High infection rate outcomes in long-bone tumor surgery with endoprosthetic reconstruction in adults: a systematic review. *Clin Orthop Relat Res* 2013;471:2017-27.
- Sigmund IK, Gamper J, Weber C, Holinka J, Panotopoulos J, Funovics PT, et al. Efficacy of different revision procedures for infected megaprotheses in musculoskeletal tumour surgery of the lower limb. *PLoS One* 2018;13:e0200304. doi: 10.1371/journal.pone.0200304.
- Agarwal M, Puri A, Anchan C, Shah M, Jambhekar N. Hemicortical excision for low-grade selected surface sarcomas of bone. *Clin Orthop Relat Res* 2007;459:161-6.
- Qadir I, Umer M, Baloch N. Functional outcome of limb salvage surgery with mega-endoprosthetic reconstruction for bone tumors. *Arch Orthop Trauma Surg* 2012;132:1227-32.
- Kadir MM, Askari R, Baz S. Use of fresh parental fibular allograft for reconstruction of skeletal defects after limb salvage surgery. *J Pak Med Assoc* 2014;64(Suppl 2):S151-3.
- Khattak MJ, Umer M, Haroon-ur-Rasheed, Umar M. Autoclaved tumor bone for reconstruction: an alternative in developing countries. *Clin Orthop Relat Res* 2006;447:138-44.
- Rashid H, Abbas K, Umer M. Single stage oncologic resection and reconstruction: a step toward development of sarcoma service in resource constrained country. *Mod Plast Surg* 2013;3:134-41.
- Askari R, Umer M, Mohsin-e-Azam, Rashid H. Our experience with Van Nes Rotationplasty for locally advanced lower extremity

- tumours. *J Pak Med Assoc* 2014;64(Suppl 2):S139-43.
12. Umer M, Abbas K, Khan S, Rashid HU. Locking compression plate in musculoskeletal oncology 'a friend in need'. *Clin Orthop Surg* 2013;5:321-6.
  13. Umer M, Umer HM, Qadir I, Rashid H, Awan R, Askari R, et al. Autoclaved tumor bone for skeletal reconstruction in paediatric patients: a low cost alternative in developing countries. *Biomed Res Int* 2013;2013:698461. doi: 10.1155/2013/698461.
  14. Rödl RW, Pohlmann U, Gosheger G, Lindner NJ, Winkelmann W. Rotationplasty - quality of life after 10 years in 22 patients. *Acta Orthop Scand* 2002;73:85-8.
  15. Gradl G, Postl LK, Lenze U, Stolberg-Stolberg J, Pohlig F, Rechl H, et al. Long-term functional outcome and quality of life following rotationplasty for treatment of malignant tumors. *BMC Musculoskelet Disord* 2015;16:262. doi: 10.1186/s12891-015-0721-0.
  16. Donati D, Colangeli M, Colangeli S, Di Bella C, Mercuri M. Allograft-prosthetic composite in the proximal tibia after bone tumor resection. *Clin Orthop Relat Res* 2008;466:459-65.
  17. van de Sande MAJ, Dijkstra PDS, Taminiau AHM. Proximal humerus reconstruction after tumour resection: biological versus endoprosthetic reconstruction. *Int Orthop* 2011;35:1375-80.
  18. Gharedaghi M, Peivandi MT, Mazloomi M, Shoorin HR, Hasani M, Seyf P, et al. Evaluation of clinical results and complications of structural allograft reconstruction after bone tumor surgery. *Arch Bone Jt Surg* 2016;4:236-42.
  19. Rabitsch K, Maurer-Ertl W, Pirker-Frühauf U, Wibmer C, Leithner A. Intercalary reconstructions with vascularised fibula and allograft after tumour resection in the lower limb. *Sarcoma* 2013;2013:160295. doi: 10.1155/2013/160295.
  20. Niethard M, Tiedke C, Andreou D, Traub F, Kuhnert M, Werner M, et al. Bilateral fibular graft: biological reconstruction after resection of primary malignant bone tumors of the lower limb. *Sarcoma* 2013;2013:205832. doi: 10.1155/2013/205832.
  21. Wang T, Chan CM, Yu F, Li Y, Niu X. Does wrist arthrodesis with structural iliac crest bone graft after wide resection of distal radius giant cell tumor result in satisfactory function and local control? *Clin Orthop Relat Res* 2017;475:767-75.
  22. Guo X, Li X, Liu T, Shuai C, Zhang Q. Pasteurized autograft reconstruction after resection of periacetabular malignant bone tumours. *World J Surg Oncol* 2017;15:13. doi: 10.1186/s12957-016-1065-4.
  23. Higuchi T, Yamamoto N, Nishida H, Hayashi K, Takeuchi A, Kimura H, et al. Knee joint preservation surgery in osteosarcoma using tumour-bearing bone treated with liquid nitrogen. *Int Orthop* 2017;41:2189-97.
  24. Krieg A. [Extracorporeal irradiation : Reimplantation of bone segments in the treatment of malignant bone tumours]. *Orthopäde* 2017;46:681-7. [German]
  25. Chotel F, Nguiabanda L, Braillon P, Kohler R, Bérard J, Abelin-Genevois K. Induced membrane technique for reconstruction after bone tumor resection in children: a preliminary study. *Orthop Traumatol Surg Res* 2012;98:301-8.
  26. Umer M, Hasan OHA, Khan D, Uddin N, Noordin S. Systematic approach to musculoskeletal benign tumors. *Int J Surg Oncol (N Y)* 2017;2:e46. doi: 10.1097/IJ9.0000000000000046.
  27. Ackman J, Altiock H, Flanagan A, Peer M, Graf A, Krzak J, et al. Long-term follow-up of Van Nes rotationplasty in patients with congenital proximal focal femoral deficiency. *Bone Joint J* 2013;95-B:192-8.
  28. Veenstra KM, Sprangers MA, van der Eyken JW, Taminiau AH. Quality of life in survivors with a Van Ness/Borggreve rotationplasty after bone tumour resection. *J Surg Oncol* 2000;73:192-7.
  29. Paul L, Docquier P-L, Cartiaux O, Delloye C, Banse X, eds. Patient-specific guides for bone tumor surgery. From in-vitro validation to clinical cases. 25th Annual Meeting of the European Musculo-Skeletal Oncology Society (EMSOS); 2012 May 15-16; Bologna, Italy: EMSOS; 2012.
  30. Qu H, Guo W, Yang R, Li D, Tang S, Yang Y, et al. Reconstruction of segmental bone defect of long bones after tumor resection by devitalized tumor-bearing bone. *World J Surg Oncol* 2015;13:282. doi: 10.1186/s12957-015-0694-3.
  31. Morelli I, Drago L, George DA, Gallazzi E, Scarponi S, Romanò CL. Masquelet technique: myth or reality? A systematic review and meta-analysis. *Injury* 2016;47(Suppl 6):S68-S76.
  32. Wang X, Luo F, Huang K, Xie Z. Induced membrane technique for the treatment of bone defects due to post-traumatic osteomyelitis. *Bone Joint Res* 2016;5:101-5.