

## SHORT REPORT

**Intravesical Foreign Body: Tertiary care center experience from Pakistan**

Hussam Uddin Soomro, Imran Jalbani, Nuzhat Faruqui

**Abstract**

Foreign body in bladder is relatively uncommon condition with variable presentations. Literature is limited to case reports and small series from region. Therefore, we planned this study to review our experience regarding intravesical foreign body. This retrospective study was conducted at the Aga Khan University Hospital, Karachi, and comprised 14 patients having intravesical foreign bodies from March 1989 to March 2013. Demographics, presentation, mode of insertion, type of foreign body and management were noted. Of the 11(78.6%) patients included in the study, 10(90.9%) patients were male and 1(9.1%) was female. The mean age was  $51 \pm 20$  years. In 5(45.5%) patients, foreign bodies reached bladder by iatrogenic route followed by self-insertion in 4(36.4%) patients. Retrieved foreign bodies included piece of Foley's catheter, electric wire, ureteric stent, plastic material, double-J stent pusher, Endo gastrointestinal (GI) staples, sticks of broom and bomb shrapnel. All patients were managed successfully with endoscopic removal. However, 5(45.5%) patients required additional urological procedures. This could represent a urologic challenge. Careful history and symptoms could lead to further investigations.

**Keywords:** Intravesical foreign body, Endoscopy, Minimally invasive.

**Introduction**

Intravesical foreign body (FB) is an uncommon, but significant, cause of urologic consultation. A great variety of FBs have been removed and reported from the lower urinary tract and male urethra.<sup>1</sup> FB may reach bladder by self-insertion, iatrogenic means, ballistic injury and migration from the neighbouring organs.<sup>2</sup> The motive behind self-insertion is either sexual gratification or as a consequence of psychiatric illness in some cases. FBs inserted in the urinary bladder include light bulb, glass rod, thermometer and battery.<sup>3</sup> Sometimes objects are inadvertently inserted in urethra for inducing abortion or to avoid conception. Living objects or parts of animals like leech, snails and squirrels may enter the urinary bladder

through urethra.<sup>4</sup> Pieces of Foley's catheter, surgical gauzes (gossypibioma) or sponges, tip of resectoscope sheath, pieces of double-J (JJ) stents, cold knife, staples or suture materials from open bladder surgeries are also reported in literature.<sup>5,6</sup> Among migrated FBs, intrauterine contraceptive devices (IUCDs) are the most common objects that perforate through uterus and reach bladder wall. Other rare objects include chicken, fish bone, wooden stick, knife blade and a piece of gauze that perforate through gastrointestinal tract leading to enterovesical fistula.<sup>7</sup> FBs reaching urinary bladder by traumatic route include bullets and pieces of shells.<sup>5,8</sup> Presentation is usually with variety of lower urinary tract symptoms (LUTS) which may include dysuria, haematuria, pyuria and recurrent infections.<sup>2</sup> The physical examination is almost always unremarkable, and urine microscopy usually reveals pus cells and red blood cells. Radiopaque objects can easily be seen on radiographs, while others are identified by the ultrasonography.<sup>9</sup> Cystoscopy is often required to confirm the diagnosis and plan removal of objects. Complications of intravesical FB consist of recurrent urinary tract infections (UTIs), retention, stone formation, obstructive uropathy, scrotalgangrene, vesicovaginal fistula, squamous cell carcinoma, and even death secondary to sepsis.<sup>9</sup> FB may be expelled spontaneously per urethra while micturition.<sup>10</sup> Most intravesical FBs can be removed endoscopically but in some cases open removal may be necessary.<sup>1,10</sup> The current study was planned to report our experience of patients with FB in the urinary bladder.

**Methods and Results**

This retrospective study was conducted at the Aga Khan University Hospital (AKUH), Karachi, and comprised 14 patients having intravesical foreign bodies from March 1989 to March 2013. Of them, 2(14.3%) patients were excluded due to missing records and 1(7.1%) was excluded as he had hair growth inside urethra following urethroplasty. Clinical features, mode of insertion, diagnosis, management and complications were noted.

Of the 11(78.6%) patients included, 10(90.9%) were males and 1(9.1%) was female. The overall mean age was  $51 \pm 20$  years (range: 19-77 years).

Furthermore, 9(82%) patients presented with variable

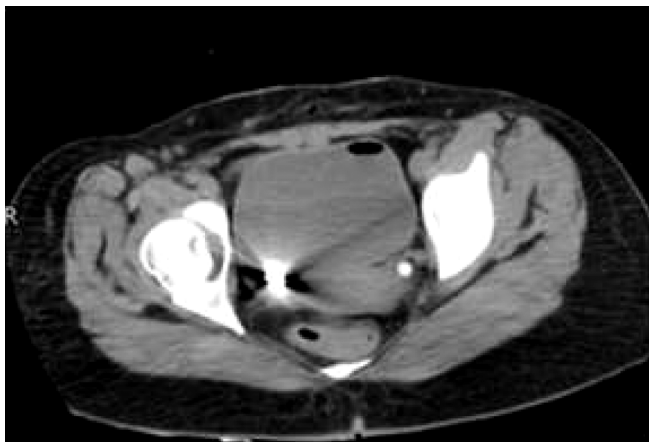
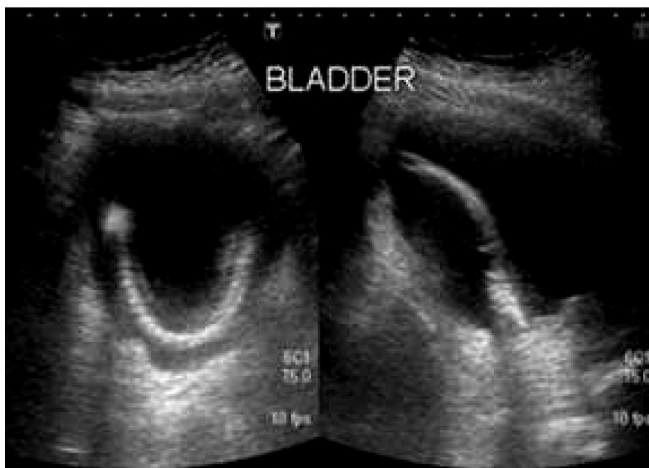
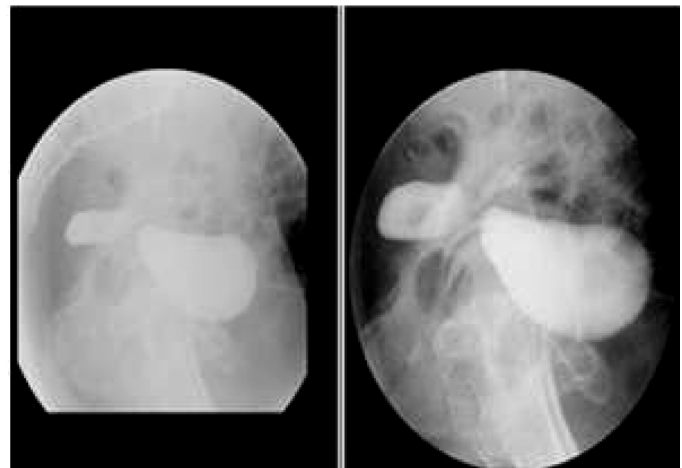
.....  
Department of Urology, The Aga Khan University Hospital, Karachi, Pakistan.

**Correspondence:** Nuzhat Faruqui Email: nuzhat.faruqui@aku.edu

**Table:** Detail of patients.

No.	Age (years)	Gender	Foreign Body	Cause	Presentation	Treatment
1	56	M	Piece of Foley	Iatrogenic	LUTS, Recurrent UTI	Cystoscopy, Removal of FB, OIU, Bladder Biopsy
2	69	M	Plastic Material	Self-Insertion	LUTS, Recurrent UTI	Cystoscopy, Removal of FB, TURP, Bladder Biopsy
3	19	M	Electric Wire	Self-Insertion	LUTS, Recurrent UTIs, Hematuria, Stone formation	Cystoscopy, Cystolitholapaxy, Removal of FB
4	55	M	Piece of Ureteric Stent	Iatrogenic	Asymptomatic	Cystoscopy, Removal of FB
5	40	M	Electric Wire	Self-Insertion	Dysuria, Hematuria	Cystoscopy, Removal of FB
6	25	M	Broom Stick	Self-Insertion	Dysuria	Flexible Cystoscopy, Removal of FB
7	72	M	Piece of Foley	Accidental	LUTS	Cystoscopy, Removal of FB, BNI, TURP
8	77	M	Piece of Foley	Accidental	LUTS	Cystoscopy, Removal of FB
9	51	M	Staples	Migration from adjacent viscera	Perianal pain, Colovesical fistula	Cystoscopy, Removal of FB, Suprapubic Cystostomy
10	39	M	DJ Stent Pusher	Iatrogenic	Dysuria, Suprapubic Pain	Cystoscopy, Removal of FB
11	27	F	Shrapnel	Traumatic	Blast Injury with Urine leak from suprapubic wound	Cystoscopy, Removal of FB

LUTS: Lower urinary tract symptoms. OIU: Optical internal urethrotomy. BNI: Bladder neck incision  
TURP: Transurethral resection of prostate. UTI: Urinary tract infections. FB: Foreign body. DJ: Double J.

**a****b****c****d**

**Figure:** (a) CT (Axial images) of pelvis showing foreign body at right posterior wall of bladder, air inside subcutaneous tissue and inside bladder. (b) Shrapnel removed with cystoscopy, (c) Ultrasound Bladder showing retained part of Foley catheter and (d) Lateral View of Cystogram showing communication between colon and bladder following Hartman's procedure (caused by staple used during procedure).  
**CT: Computed tomography.**

urinary symptoms, including increased frequency, nocturia, urgency, poor stream, sense of incomplete emptying, dysuria and purulent urethral discharge; 2(18.2%) patients also had gross haematuria. However, 3(27.3%) patients had positive urine culture (staphylococcus aureus, escherichia coli and pseudomonas) that was treated accordingly.

The only female patient (case # 11) had extraperitoneal bladder perforation secondary to bomb blast injury. On presentation, urine leak was noted from small suprapubic wound. Iatrogenic mode of insertion was used in 5(45%) cases, followed by self-insertion in 4(36.4%), and migration from outside the bladder and external trauma in 1(9%) patient each. In self-insertion group, only 1(9%) patient had history of psychiatric illness. Ultrasound, X-ray of kidney, ureter and bladder (KUB), intravenous urogram (IVU), computed tomography (CT) of KUB and cystogram were the radiological imaging procedures used for diagnosis.

Endoscopic removal of foreign body was carried out by cystoscopy in all patients. Rigid cystoscopy was performed in 9(82%) patients and flexible cystoscopy was used in 2(18%) patients. Objects retrieved were part of Foley's catheter, electric wire, piece of plastic, broomstick, JJ stent pusher, JJ stent, endo-gastrointestinal staples and shrapnel of bomb.

We did not encounter any pre-/post-operative complication. None of our patients required open surgery or laparoscopy.

A total of eight procedures were performed on 5(45.5%) patients, including transurethral resection of prostate; bladder biopsy was performed on 2(18%) patients, whereas bladder neck incision, optical internal urethrotomy, cystolitholapaxy and suprapubic cystostomy were performed on 1(9%) patient each.

Suprapubic catheter was placed in the patient with colovesical fistula (case # 9), as his condition was persistent and he was planned for colovesical fistula repair. The patient with blast injury had isolated extraperitoneal bladder injury that was managed with indwelling Foley catheter for two weeks after removal of foreign body (case # 11).

Histopathology of prostate and bladder tissue showed benign prostate hyperplasia and chronic inflammation, respectively. However, the 2(18%) patients were on regular urethral calibration for urethral stricture and bladder neck contracture (case # 1 and 8) (Table).

The bomb blast victim underwent CT KUB as she was allergic to contrast, which confirmed intravesical shrapnel (Figure). One patient presented with perianal pain and was diagnosed to have colovesical fistula secondary to migrated endo-gastrointestinal staple after colon surgery.

## Conclusion

Although not very common, intravesical FB could be considered in differential diagnoses of a patient with refractory lower urinary tract symptoms, especially when clinical history is suspicious. The type and nature of the foreign body should be ascertained by appropriate radiological studies, which direct the decision of removal of a particular foreign body. The most suitable method of removal of intravesical FB is endoscopic, but certain foreign bodies may require open/laparoscopic surgery for removal.

## References

1. Levine MA, Evans H. Open removal as a first-line treatment of magnetic intravesical foreign bodies. *Can Urol Assoc J* 2013; 7: E25-8.
2. Kochakarn W, Pummanagura W. Foreign bodies in the female urinary bladder: 20-year experience in Ramathibodi Hospital. *Asian J Surg* 2008 Jul; 31: 130-3.
3. Gogus C, Kilic O, Haliloglu A, Gogus O. A very unusual intravesical foreign body in a male. *Int Urol Nephrol* 2002; 34: 203-4.
4. Robinson D. Foreign body in the bladder. *J Emerg Med* 2005; 29: 215.
5. Habermacher G, Nadler RB. Intravesical holmium laser fragmentation and removal of detached resectoscope sheath tip. *J Urol* 2005; 174: 1296-7.
6. Mylarappa P, Srikantaiah HC. Calcified intravesical gossypiboma following abdominal hysterectomy: a case report. *J Clin Diagn Res* 2011; 5: 645-7.
7. Mustafa M. Erosion of an intrauterine contraceptive device through the bladder wall causing calculus: management and review of the literature. *Urol Int* 2009; 82: 370-1.
8. Halkic N, Wisard M, Abdelmoumene A, Vuilleumier H. A large bullet in the bladder. *Swiss Surg* 2001; 7: 139-40.
9. Eckford SD, Persad RA, Brewster SF, Gingell JC. Intravesical Foreign Bodies: Five year Review. *BJU Int* 1992; 69: 41-5.
10. DiDomenico D, Guinan P, Sharifi R. Spontaneous expulsion of an intravesical bullet. *J Am Osteopath Assoc* 1997; 97: 415-6.