

PLASTIC SURGERY

SHORT REPORT

Versatility of the Anterolateral Thigh Flap: An AKUH experience

M. Fazlur Rahman, Muhammad Asif Ahsan, Muhammad Ubaid Khan, Sami Ullah, Sara Khan

Abstract

Anterolateral thigh flap is used for reconstruction of various soft tissue defects. We planned the study to evaluate the versatility of the anterolateral thigh flap as it may be used for reconstruction of head and neck, torso and extremities with minimal donor-site morbidity. The retrospective study was conducted at Aga Khan University Hospital, Karachi, and comprised date from October 2012 to December 2015. Of the 75 patients in which anterolateral thigh flap was used for reconstruction, 6(8%) flaps did not survive. The overall flap survival was 69(92%). Anterolateral thigh flap was versatile enough to provide soft tissue coverage to defects of various soft tissue and bulk requirements. Adequate outcomes were achieved pertaining to the reconstruction of the soft tissue defects. Anterolateral thigh flap can be used to reconstruct soft tissue defects almost anywhere and almost of any complexity.

Keywords: Reconstruction, Flap, Soft-tissue.

Introduction

Anterolateral thigh flap, first introduced in 1984¹ based on perforators of branches of lateral circumflex femoral artery,^{2,3} has evolved to be the workhorse for soft tissue reconstruction for a spectrum of pathologies. Studies have accepted the versatility of this unique flap owing to certain significant advantages and minimal donor-site morbidity.² In our experience, anterolateral thigh flap is the most versatile free flap as it can be used for various spectrum of soft tissue defects. The current study was planned to review our clinical experience regarding the reconstruction of various soft-tissue defects using an anterolateral thigh flap.

Methods and Results

The retrospective study was conducted at Aga Khan

Department of Surgery, Aga Khan University Hospital, Karachi, Pakistan.

Correspondence: M. Fazlur Rahman. Email: fazli.rahman@aku.edu

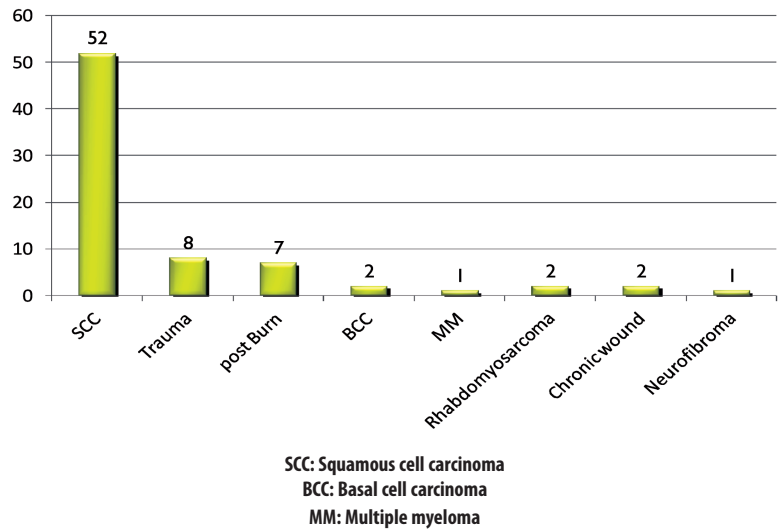


Figure-1: Cause of defects.

University Hospital, Karachi, and comprised date from October 2012 to December 2015. All patients who underwent anterolateral thigh flap were included. Data was collected by reviewing medical records. Patients with missing data or patients who were lost to follow-up were excluded. SPSS 17 was used for data analysis.

A total of 75 patients were studied out of whom 62(82.6%) were males. The overall mean age was 47 (± 19.3) years.

The most common cause of soft tissue defect was squamous cell carcinoma (SCC) followed by trauma and post-burn defects (Figure-1).

In terms of defect site, the head and neck region was the most frequent site reconstructed 53(50.6%).

In terms of size, the mean length of the flap was 16.4 (±4) cm and the mean width was 8.3 (±1.5)cm. Besides, 39(52%)flaps were raised on two perforators and 36(48%)were raised on a single perforator. The mean length of the pedicle was 12(±2) cm. In 41(54.6%) patients, the donor site was closed primarily and the other 34(45.3%) patients required split thickness skin graft for

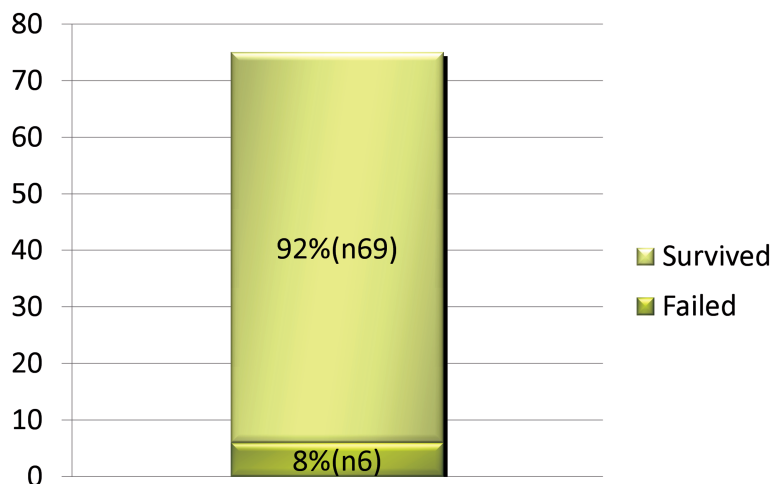


Figure-2: Flap Survival.

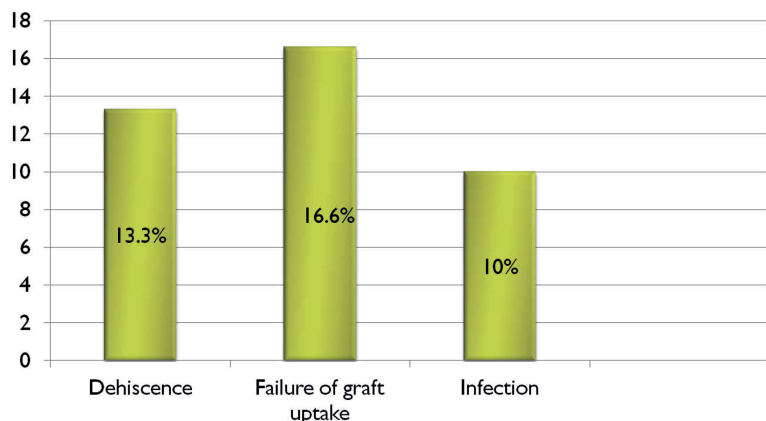


Figure-3: Donor-site morbidity.

closure of the donor site.

The overall flap survival rate was 69(92%)(Figure-2). Of the 6(8%) failed flaps, trauma seemed to have a higher failure rate as 2(25%) of 8 such flaps failed as apposed to malignancy where only 4(7%) out of 57 flaps failed. The causes identified were latrogenic or infection in trauma patients and arterial and venous thrombosis in patients with malignancy.

Donor-site morbidity included 13(17%) patients with wound dehiscence, 17(23%) had failure of graft uptake, and 10(13%) had post-surgical infection at the donor site (Figure-3).

Conclusion

Reconstruction of soft tissue defect presents a challenge in terms of the anatomy of the recipient site and composite losses. However, in this study, application of

anterolateral thigh flap for coverage of defects of extremity and torso have been described adequately with good outcomes.

The recipient site in our study varied from head and neck to torso to both upper and lower extremities.

Anterolateral thigh flap is suitable for reconstruction of defects of the oral cavity floor and skin defects of the face.⁴

Radial forearm flap is considered ideal for small and thin defects as an anterolateral thigh flap of less than 4cm is technically difficult to harvest, but the anterolateral thigh flap has superseded the radial forearm flap for head and neck reconstruction in the Asian population because the defects are usually large.⁵ An anterolateral thigh flap raised with two skin paddles based on widely separated perforators allows for eccentrically aligned tissue defects to be reconstructed with a single flap and a single anastomosis.

Partial glossectomy is ideally reconstructed using a large, relatively pliable fasciocutaneous anterolateral thigh flap as it can be moulded as per the requirement of the defect. The thinness of the flap helps in maintaining the movement of the tongue. In our study, we had three glossectomy defects which were adequately reconstructed using anterolateral thigh flap.

The reconstructive goals in a limb trauma are salvage of limb, preservation of function and maintenance of aesthetics. Traumatic wound have variable soft tissue requirements and anterolateral thigh flap can provide almost all types of donor tissue. A long vascular pedicle is an added advantage in reconstruction of traumatised limb. Malleolar wounds require thin coverage to facilitate footwear,⁶ whereas deeper wounds or osteomyelitis requires bulk for obliteration of dead space.⁷

Primary closure of the donor site results in minimal pain, acceptable scar, good thigh contour, and rapid mobilisation. Skin graft may be used to cover the donor-site defects when they cannot be closed primarily. There is minimal restriction in daily activities post-anterolateral thigh flap harvest. Various studies have demonstrated a 10% to 30% reduction in strength of knee extension on objective assessment.⁸ Tethering of the underlying muscle has been described with the use of skin grafts for coverage of the donor site.⁹ There have been reports of

donor-site complications, including wound infection, dehiscence, bulging and herniation of the thigh, seroma, paresthesia, and scar cosmesis,¹⁰ some of which were also evident in our study.

References

1. Song YG, Chen GZ, Song YL. The free thigh flap: A new free flap concept based on the septocutaneous artery. *Br J Plast Surg* 1984; 37: 149-59.
2. Jeng SF, Kuo YR, Wei FC, Su CY, Chien CY. Reconstruction of concomitant lip and cheek through-and-through defects with combined free flap and an advancement flap from the remaining lip. *Plast Reconstr Surg* 2004; 113: 491-8.
3. Kimata Y, Uchiyama K, Sekido M, Sakuraba M, Iida H, Nakatsuka T, et al. Anterolateral thigh flap for abdominal wall reconstruction. *Plast Reconstr Surg* 1999; 103: 1191-7.
4. Koshima I, Fukuda H, Yamamoto H, Moriguchi T, Soeda S, Ohta S. Free anterolateral thigh flaps for reconstruction of head and neck defects. *Plast Reconstr Surg* 1993; 92: 421-8.
5. Demirkan F, Chen HC, Wei FC, Chen HH, Jung SG, Hau SP, et al. The versatile anterolateral thigh flap: A musculocutaneous flap in disguise in head and neck reconstruction. *Br J Plast Surg* 2000; 53: 30-26.
6. Yang WG, Chiang YC, Wei FC, Feng GM, Chen KT. Thin anterolateral thigh perforator flap using a modified perforator microdissection technique and its clinical application for foot resurfacing. *Plast Reconstr Surg* 2006; 117: 1004-8.
7. Hong JP, Shin HW, Kim JJ, Wei FC, Chung YK. The use of anterolateral thigh perforator flaps in chronic osteomyelitis of the lower extremity. *Plast Reconstr Surg* 2005; 115: 142-7.
8. Kuo YR, Kuo MH, Lutz BS, Huang YC, Liu YT, Wu SC, et al. One-stage reconstruction of large midline abdominal wall defects using a composite free anterolateral thigh flap with vascularized fascia lata. *Ann Surg* 2004; 239: 352-8.
9. Kimata Y, Uchiyama K, Ebihara S, Sakuraba M, Iida H, Nakatsuka T, et al. Anterolateral thigh flap donor-site complications and morbidity. *Plast Reconstr Surg* 2000; 106: 584-9.
10. Lipa JE, Novak CB, Binhammer PA. Patient-reported donor-site morbidity following anterolateral thigh free flaps. *J Reconstr Microsurg* 2005; 21: 365-79.