

SHORT REPORT

Rotational Mal-Alignment after Reamed Intramedullary Nailing for tibial shaft fracture

Sher Baz Khan, Yasir Mohib, Rizwan Haroon Rashid, Haroonur Rashid

Abstract

Intra-medullary (IM) nailing is standard of care for unstable tibial shaft fractures. Malrotation is very common but it is under-recognised, in part because of variation in normal anatomy and partly due to difficulty in accurately assessing rotation. This study was planned to evaluate the frequency of rotational mal-alignment after reamed tibia IMnailing. This cross-sectional study was conducted at Aga Khan University Hospital, Karachi, and comprised patients with tibia shaft fractures managed with IMnailing from January to December 2014. All the patients were assessed intra-operatively for rotational alignment using the knee and ankle fluoroscopic images. There were 81 patients with a mean age of 38 ± 16.9 years. There were 64 (79%) male patients. Overall the incidence of malrotation was in 20 (24.7%) cases. Rotational mal-alignment is one of the preventable complications after IMnailing which can be assessed intra-operatively under fluoroscope.

Keywords: Tibial shaft fracture, Nailing, Malrotation, Rotational mal-alignment.

Introduction

Tibial diaphyseal fractures are the most common long-bone fractures. The goal of treatment in these cases is to attain rapid union with acceptable axial and rotational alignment while preserving the initial bone length. Several studies have shown that tibial nailing is associated with superior outcomes and less complication compared to those obtained with open reduction and internal fixation (ORIF), external fixation, or non-operative treatment in case of closed stable or unstable fractures.¹

Tibial torsion is the anatomical twist of the proximal versus distal articular axis of the tibial bone in the transverse plane around the longitudinal axis. Any change in the tibial torsion, either in the internal or in the external direction, is considered a mal-rotation and can be seen after fixation of the tibial shaft fractures by closed intra-medullary (IM) nailing.

.....
Orthopedics, Aga Khan University Hospital, Karachi.

Correspondence: Sher Baz Khan. Email: ajizbrooshali@gmail.com

In many studies, tibial malrotation has been measured clinically and the incidence is reported to be 0-6%; whereas such incidence is reported to be 22-36% by using other measurement methods such as computerised tomography (CT) scanning.² One study found an incidence of 30% of rotational mal-alignment.³

The current study was planned to evaluate the frequency of rotational mal-alignment after reamed IMnailing of tibia.

Methods and Results

This cross-sectional study was conducted at Aga Khan University Hospital, Karachi, from January 1 to December 31, 2014. The sample size was calculated using the World Health Organisation (WHO) sample size calculator. Confidence level ($1-\alpha$ %) was taken as 95%, with precision (d) of 0.1. Taking the frequency of mal-alignment from literature as 30%,³ the sample size was calculated. Considering the largest sample size that was calculated for the frequency of mal-alignment, we achieved a sample size of 81. All patients between aged 15-80 years presenting to the emergency room (ER) or outpatient department (OPD) with traumatic tibial shaft fractures planned for closed IMnailing of tibia by a single consultant orthopaedic surgeon were included. Patients with pathological fracture, comminuted fracture requiring additional stability, non-unions, fractures reduced by open method, fractures extending to knee and ankle joints were excluded. All the patients were assessed intra-operatively for rotational alignment using the fluoroscopic images of knee and ankle of the same limb, as described in literature.⁴ First, a true lateral of the knee was obtained by superimposing the medial and lateral femoral condyles. With the leg held stationary, the fluoroscopic unit was rotated 90 degrees, which provided a true antero-posterior (AP) view. If the tibial fracture was accurately reduced, rotation of an additional 10 to 15 degrees provided an accurate mortise view of the ankle. If it was more than 15 degrees, it was taken as external malrotation and if it was less than 10 degrees, it was declared internal malrotation (Figure).

SPSS 19 was used for data analysis. Mean \pm standard

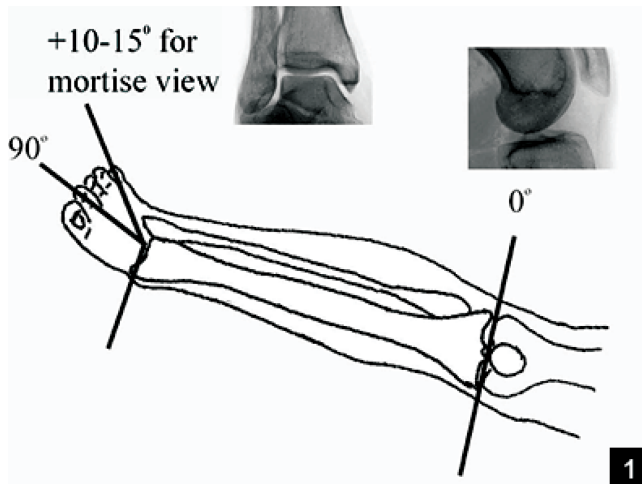


Figure: Clementz technique.

deviation (SD) were computed for continuous variables i.e., age, and as frequency and percentage for nominal variables i.e., gender, site, side type of fracture and proportion of malrotation. Stratification with respect to age, gender site of fracture, type of fracture and associated fibular fracture was done to see the effect of these on outcome variable through chi square test. $P < 0.05$ was considered significant.

Of the 81 patients, 64 (79%) were male. The overall mean age was 38 ± 16.9 years (range: 17 -80 years). Of the total, 31 (38%) patients had fracture in the upper half of tibia, while in 50 (62%) cases lower half of tibia was involved. Besides, 52 (64.2%) patients had simple fractures, 11 (13.6%) had wedge and 18 (22.2%) had complex fractures, with 69 (85.2%) concomitant fibular fractures. Overall, 20 (24.7%) cases had malrotation out of whom 15 (75%) had external and 5 (25%) had internal malrotation.

When stratification with respect to site of fracture was done in order to see the effect of site of fracture on outcome variable, it was found to be statistically non-significant ($p > 0.05$). When we saw malrotation with respect to type of fracture, the more complex type fractures were associated with more malrotation ($p < 0.05$). None of the patients had malrotation who had intact fibula ($p < 0.05$).

Conclusion

IMnailing is the treatment of choice for displaced diaphyseal fractures of the tibia in adults.^{5,6} Clinical manifestations after tibial shaft fractures treatment, regardless of the kind of treatment, are subtle and, most of times remain unperceived.

Rotational mal-alignment is a common but difficult complication to detect radiographically and clinically, and it is often underappreciated. There are many methods to assess the rotational mal-alignment intraoperatively by fluoroscopy and post-operatively by computed tomography (CT) scan.^{3,7} Malrotation is often determined indirectly by fluoroscopy like obtaining the true AP view of knee and Mortis view of ipsilateral ankle and measuring the difference in angle between them. Certain fracture patterns are at high risk for malrotation like transverse, segmental comminuted and fractures associated with ipsilateral fibular fracture. Clinical assessment is an inconsistent method of judging rotation. Assessing rotation by comparing the injured extremity with the normal extremity leads to missed malrotation.

Rotational deviation after IMnail insertion is seldom reported, but literature shows an incidence ranging from 0% to 15% when clinically assessed⁶ and even up to 30% in some studies^{3,7} that showed tibial rotation by means of CT on tibial shaft fractures treated with blocked IMnail and suggested that over 20% of the patients developed tibial rotation above 10° when measured by CT. In our study it was 24.7% which is in accordance with literature.

Other studies^{7,8} demonstrated that the injury pattern may influence results. High-energy, comminuted fractures, significant deviations of bone fragments and distal third fractures seem to predispose patients to rotational deformities. Also, in our study complex type of fractures were associated with more severe rotational mal-alignment after IMnailing of tibia. It was also observed in our study that an intact fibula prevented rotational mal-alignment. It is believed that rotational mal-alignment of the lower extremity can affect knee and ankle joints biomechanics and may consequently lead to the development and progression of degenerative changes.

Also, two separate studies reported that tibial mal-alignment was associated with poor functional outcomes.⁹ Despite these reports, there are several other studies that found no or poor correlation between malunion and osteoarthritis. One study¹⁰ demonstrated that there was no correlation between tibial malrotation and arthrosis.

We believe that our study had an acceptable sample size, but it was performed over a short period of time. A clinical and biomechanical long-term follow-up study on the malrotated group would be helpful to improve the insight generated by our study about the effects of tibial malrotation on the patient's gait and quality of life.

References

1. Bhandari M, Zlowodzki M, Tornetta Iii P, Schmidt A, Templeman DC. Intramedullary nailing following external fixation in femoral and tibial shaft fractures. *J Orthop trauma* 2005; 19: 140-4.
2. Enninghorst N, McDougall D, Hunt JJ, Balogh ZJ. Open tibia fractures: timely debridement leaves injury severity as the only determinant of poor outcome. *J Trauma Acute Care Surg* 2011; 70: 352-7.
3. Jafarinejad AE, Bakhshi H, Haghnegahdar M, Ghomeishi N. Malrotation following reamed intramedullary nailing of closed tibial fractures. *Indian J Orthop* 2012; 46: 312-6
4. Clementz B-GR. Assessment of tibial torsion and rotational deformity with a new fluoroscopic technique. *Clin Orthop Relat Res* 1989; 245: 199-209.
5. Christie J, McQueen MM. Closed intramedullary tibial nailing. Its use in closed and type I open fractures. *J Bone Joint Surg Br* 1990; 72: 605-11.
6. Alho A, Benterud JG, HÅGevold HE, Ekeland A, StrÅMsÅE K. Comparison of functional bracing and locked intramedullary nailing in the treatment of displaced tibial shaft fractures. *Clin Orthop Relat Res* 1992; 277: 243-50.
7. Puloski S, Romano C, Buckley R, Powell J. Rotational malalignment of the tibia following reamed intramedullary nail fixation. *J Orthop Trauma* 2004; 18: 397-402.
8. Krettek C, Schandelmaier P, Tschene H. Nonreamed interlocking nailing of closed tibial fractures with severe soft tissue injury. *Clin Orthop Relat Res* 1995;315:34-47.
9. Puno RM, Vaughan JJ, Stetten ML, Johnson JR. Long-term effects of tibial angular malunion on the knee and ankle joints. *J Orthop Trauma* 1991 ;5: 247-54.
10. Hankemeier S, Hufner T, Wang G, Kendoff D, Zheng G, Richter M, et al. Navigated intraoperative analysis of lower limb alignment. *Arch Orthop Trauma Surg* 2005; 125: 531-5.