

SHORT REPORT

Paediatric External Ventricular Drains: Experience from a tertiary care hospital of a Developing Country

Abbas Qalab,¹ Rayaan Asad,² Mahnaz Hakeem,³ Maria Ahmed,⁴ Haque Anwar,⁵ Aneela Darbar⁶

Abstract

The aim of the study was to describe indications and complications of external ventricular drain (EVD) placement in children aged between 1 month and 16 years. This retrospective chart review was conducted at the Aga Khan University Hospital, Karachi, and comprised all children who underwent EVD placement from January 2007 to December 2014. Of the 177 patients identified, 117(66%) were males 60(34%) were girls. The overall mean age was 5.4 ± 5.2 years. The median Glasgow Coma Scale score on presentation and discharge was 13 (interquartile range [IQR]: 7) and 15 (IQR: 4), respectively. Major diagnosis included intracranial tumour 60(34%), bacterial meningitis 34(19%), tuberculous meningitis 33(18.6%), and haemorrhage 23(13%). Clinical indications for EVD insertion were acute hydrocephalus secondary to infection 64(36.2%), tumour 54(30.5%), and haemorrhage 23(13%) ventriculoperitoneal shunt malfunction or infection 25(14.1%) and traumatic brain injury 11(6.2%). Complications were observed in 47(26%) patients including infections 25(14.1%), malfunction 11(6.2%), haemorrhage 6(3.4%), misplacement 3(1.7%) and obstruction 2(1.1%). Staphylococcus was the main organism isolated. Moreover, 25(14%) patients expired. Acute hydrocephalus was the major indication and EVD infection was the major complication.

Keywords: EVD, Paediatric, Hydrocephalus, Infections, Complications.

Introduction

External ventricular drain (EVD) is a catheter placed percutaneously into the brain's ventricular system and connected to the external drain and transducer system. The insertion technique is simple, reliable and cost-effective.¹ EVD serves the dual purpose of cerebrospinal fluid (CSF) drainage and measurement of intracranial pressure (ICP).² EVDs have been used to treat acute hydrocephalus secondary to various underlying conditions including central nervous system (CNS)

tumours, CNS infections and as a temporary replacement for infected or malfunctioning ventriculo-peritoneal shunt (VPS).^{2,3} Its use is also increasing in patients with traumatic brain injury (TBI) and the paediatric guidelines for TBI emphasise the need for studies on EVD use in paediatric population.¹ EVD use has been intensely investigated in adult neurosurgical patients, but its use and experience in paediatric population is far less.⁴ Despite their increasing use and experience in children, they are not without complications. Various complications have been identified in adults as well as paediatric population with EVD insertion including infections, misplacement, haemorrhage malfunction and obstruction, with variable frequency and infections being the most common (9% to 28%).⁵ There is scarce literature on use of EVD in paediatric population from developing countries.

The current study was planned to analyse the indications and complications of EVD placement in children in tertiary care setting of a developing country.

Methods and Results

This retrospective study was conducted at the Aga Khan University Hospital (AKUH), Karachi, and comprised medical records of children aged 1 month to 16 years who underwent EVD insertion from January 2007 to December 2014. Approval was obtained from the institutional ethics review committee. EVD insertion confirmation was done from medical chart notes and double-checked with operating room (OR) records, patient billing codes and log books.

Codman EVDs (Johnson & Johnson) were placed in all patients in OR in the lateral ventricle using standard technique. EVD position was confirmed post-operatively by computed tomography (CT). EVD bundle care was applied.⁶ CSF drainage through EVD was replaced volume to volume with normal saline. All patients received prophylactic cefazolin for 48 hours and CSF surveillance samples were sent for analysis twice a week and/or in case of new fever episode, i.e. $>38.3^{\circ}\text{C}$.

Data was collected on a structured proforma including demographic (age, gender, diagnosis) and clinical data

^{1,3,4}Department of Pediatrics and Child Health, ²Student, ⁵Department of Surgery, Section of Neurosurgery, ⁶Aga Khan University, Karachi.

Correspondence: Qalab Abbas. Email: qalab.abbas@aku.edu

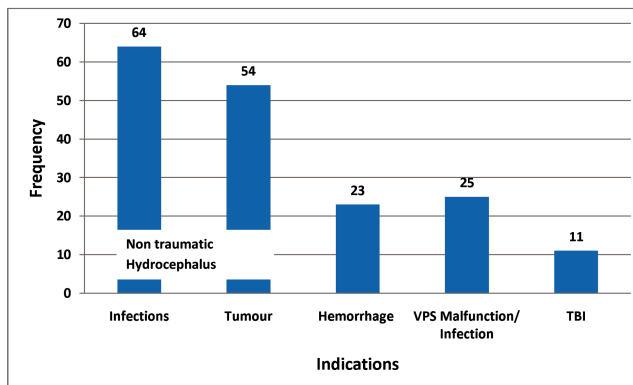
Table: Basic Demographic and EVD Data (n=177).

Variable	Number (percentage)
Age (Median with IQR)	4 (IQR 10)
Gender (Male)	117 (66%)
Female	
Glasgow Coma Scale (Median with IQR)	
On Admission: Median (IQR)	13 (7)
Median (IQR): On Discharge	15 (4)
Indication for EVD	
Acute Non Traumatic Hydrocephalus	141 (80)
TBI	11(6)
VPS Failure	25 (14)
Primary Diagnosis	
Tumour	60 (34)
Bacterial Meningitis	34 (19)
Tuberculous Meningitis	33 (18.6)
Haemorrhage	23 (13)
Meningocele	9 (5)
Congenital Hydrocephalus	7 (4)
TBI	11 (6.4)
EVD placement duration: Median (IQR)	6 (6)
Outcome (mortality)	24 (13.5)

IQR: Interquartile range,
 TBI: Traumatic Brain injury,
 EVD: External ventricular drains,
 VPS: Ventriculoperitoneal drains.

(Glasgow Coma Scale (GCS) on admission and discharge, indication for EVD insertion, findings of CT brain, duration of EVD placement, complications of EVD). Indications were categorised into acute traumatic and non-traumatic hydrocephalus and VPS failure. Dilatation of ventricles on CT scan with signs and symptoms (low GCS, bradycardia, hypertension, unequal pupils) of raised ICP in a patient with VPS was labelled as VPS failure. Complications noted were malfunction, haemorrhage, and misplacement of EVD, EVD catheter infection, and obstruction. EVD malfunction was identified when EVD could not measure ICP accurately. When CSF was not draining due to debris deposited or kinking of the tube, EVD was considered obstructed. Misplacement was defined as catheter tip outside the lateral ventricle in the brain parenchyma on CT. Infection after EVD insertion was defined as a positive CSF culture in previously sterile CSF with fever above 38.3°C. Haemorrhage after EVD insertion was identified by CT imaging. Other outcomes measured included the duration of EVD placement (days) and patient survival. Data was analysed using SPSS 20. Results were presented as frequency with percentages and mean with standard deviation (SD). Student's t-test and chi-square test were applied as appropriate. P<0.05 was considered significant.

Of the 177 patients, 117(66%) were boys and 60(34%) were girls. The overall mean age was 5.4±5.2 years.



EVD: External ventricular drains.

Figure-1: Indications for EVD Insertion in Children.

The indications for EVD insertion were acute non-traumatic hydrocephalus in 141(80%) cases, TBI in 11(6%) and VPS failure in 25(14%). Causes for non-traumatic hydrocephalus included tumour 54(30.5%), bacterial meningitis 34(19%), tuberculous meningitis 30(17%) and haemorrhage 23(13%). There were 25(14%) cases of VPS failure. Diagnosis in patients with VPS failure was meningocele in 9(5%) patients, congenital hydrocephalus in 7(3.9%), tumour in 6(3.4%) and tuberculous meningitis in 2(1.1%).

The median EVD placement duration was six days (interquartile range (IQR): 6). EVD complications were observed in 47(27%) patients, infection 25(14%), malfunction of EVD in 11(6.2%) patients and revision was done, haemorrhage 6(3.3%), misplacement of EVD in 3(1.7%) (intraparenchymal) and obstruction of EVD in 2(1.1%) patients in which revision of EVD was done. In EVDs infected after insertion, microorganisms identified from CSF culture taken from EVD included staphylococcus aureus 5(2.8%), staphylococcus epidermidis 3(1.7%), other staph species 4(2.3%) (all of them coagulase positive), 4(2.3%) patients had pseudomonas species,

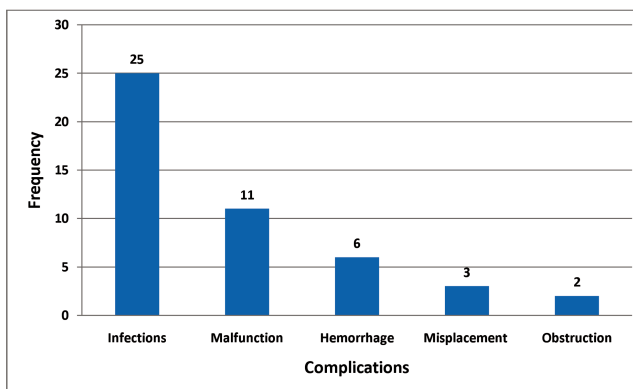


Figure-2: External Ventricular Drain Complications (n=47).

acinetobacter and enterococcus species each. Moreover, 3(1.7%) patients with acinetobacter and 2(1.1%) with enterococcus had multidrug resistance.

The mean GCS score improved from 11.59±3.95 to 12.22±4.4 after EVD insertion ($p=0.04$, 95% confidence interval (CI): -1.41 to -0.003). Infection developed in 10(5.6%) patients who had EVD placed for 5 days or less and in 15(8.5%) patients who had EVD placed for >5 days ($p=0.82$). The duration of EVD placement was higher in patients with acute non-traumatic hydrocephalus, tumour and VPS failure ($p=0.13$) (Figure-1). In patients with EVD placement duration of less than 5 days, 14(7.9%) patients developed complications with EVD duration of < 5days compared to 33(18.6%) patients in whom EVD was placed for >5 days. There was no difference between infections or all complications when compared with age, gender, GCS, indication for EVD insertion, underlying diagnosis or outcome ($p>0.05$) (Figure-2). Besides, 24(13.5%) patients died during the study period. Of them, 2(8.3%) died of EVD-related infections, whereas 22(91.7%) died of the underlying disease process (Table).

Conclusion

EVD use in paediatric population is increasing. Major indication for EVD placement in our study was acute non-traumatic hydrocephalus secondary to CNS infections ($n=88$). Results from developed countries showed the main indications for EVD insertion were TBI and tumours.^{3,5} This could be due to increased incidence of tuberculosis in our country as shown in some previous studies,⁷ which showed meningitis as the second-most common indication for EVD placement (21%) in contrast to our study where 25% and 18% patients had hydrocephalus due to bacterial and tuberculous meningitis, respectively. Complications rate in our study is 27% similar to that shown by Ngo et al.⁵ (26%) but is less than that reported by Arif et al. i.e. 31%.⁸ Non-infectious complications, including malfunction, misplacement, haemorrhage and obstruction, in our study are similar as reported earlier.^{5,8} We observed a high infection rate of 14% in our study as compared to a study by Ngo et al. where it was 9.4% while Arif et al. showed a high infection rate of 23%. Different measures have been studied to reduce the infection rates including making long subcutaneous tunnels, using antibiotic-coated EVD catheters and some other measures collectively called EVD bundle care.^{6,9} We have started the use of EVD bundle care since last 2 years but EVD catheters are not antibiotic impregnated. The micro-organisms identified in our study are similar to those reported from other studies.^{7,10} We found no effect of EVD

duration on infection rate compared to other studies that showed that prolonged EVD placement was associated with high infection rate.⁵ The role and choice of prophylactic antibiotics need large prospective studies as many organisms especially acinetobacter and enterococcus are resistant to these commonly used antibiotics.

It was found that acute non-traumatic hydrocephalus was the most common indication and infection was the most common complication for EVD insertion.

This was the first comprehensive report describing all the complications of EVD placement from our part of the world. However, one of the limitations of the current study was that it was a single centre retrospective study with limited data.

Conflicting Interest: None.

Acknowledgement: None.

References

1. Brain Trauma Foundation; American Association of Neurological Surgeons; Congress of Neurological Surgeons. Guidelines for the management of severe traumatic brain injury. *J Neurotrauma* 2007; 24 Suppl1: S1-106.
2. Friedman WA, Vries JK. Percutaneous tunnel ventriculostomy. Summary of 100 procedures. *J Neurosurg* 1980; 53: 662-5.
3. Walker CT, Stone JJ, Jacobson M, Phillips V, Silberstein HJ. Indications for pediatric external ventricular drain placement and risk factors for conversion to a ventriculoperitoneal shunt. *Pediatr Neurosurg* 2012; 48: 342-7.
4. Brain Trauma Foundation; American Association of Neurological Surgeons; Congress of Neurological Surgeons; Joint Section on Neurotrauma and Critical Care, AANS/CNS, Bratton SL, Chestnut RM, Ghajar J, McConnell Hammond FF, Harris OA, Hartl R, Manley GT, et al. Guidelines for the management of severe traumatic brain injury. VII. Intracranial pressure monitoring technology. *J Neurotrauma* 2007; 24 Suppl1: S45-54.
5. Ngo QN, Ranger A, Singh RN, Kornecki A, Seabrook JA, Fraser DD. External ventricular drains in pediatric patients. *Pediatr Crit Care Med* 2009; 10: 346-51.
6. Kubilay Z, Amini S, Fauerbach LL, Archibald L, Friedman WA, Layon AJ. Decreasing ventricular infections through the use of a ventriculostomy placement bundle: experience at a single institution. *J Neurosurg* 2012; 118: 514-20.
7. Rafiq MF, Ahmed N, Aii S, Khan MN, Khaleeq uz Z. Culture and sensitivity pattern in patients with external ventricular drain infection. *J Ayub Med Coll Abbottabad* 2011; 23: 118-20.
8. Arif S H BAR, Wani M A , Raina T, Ramzan A, Kirmani A, Hussain Z, Tabassum R, Baba A, Bari S. Infective and non-infective complications of external ventricular drainage. *J K Pract* 2012; 17: 27-32.
9. Hill M, Baker G, Carter D, Henman LJ, Marshall K, Mohn K, et al. A multidisciplinary approach to end external ventricular drain infections in the neurocritical care unit. *J Neurosci Nurs* 2012; 44: 188-93.
10. Kulkarni AV. External ventricular drains: common procedure, unanswered questions. *Pediatr Crit Care Med* 2009; 10: 412-3.