

Postoperative range of motion and stability after anterior cruciate ligament reconstruction using quadrupled hamstring autograft

Rana Dawood Ahmad Khan, Syed Muhammad Tayyab Hassan, Usama Bin Saeed, Ajmal Yasin

Abstract

Background: The incidence of anterior cruciate ligament (ACL) tear is increasing, especially in young active adults. Various surgical options like bone-patellar tendon-bone graft and hamstring autograft have been the focus of evaluation and comparison in various aspects, each having specific advantages and demerits. We are increasingly using and analysing quadrupled hamstring autograft for ACL reconstruction. Previously it was advocated as a sports injury, but now we note that road traffic accidents (RTAs) are the most common cause of ACL tear.

Objectives: Objective of this study was to evaluate clinical results of ACL reconstruction in terms of stability and range of motion using hamstring autograft.

Materials and Methods: We enrolled 50 patients from June 2011 to May 2014 with isolated ACL rupture, used autologous quadrupled hamstring graft and compared the clinical improvement of knee stability and range of motion preoperatively versus postoperatively using pivot shift test and lachman test. Every patient underwent a standardised 6-month rehab follow-up plan and then findings were documented and analysed using SPSS 17.

Results: Marked improvement was seen at 6-month follow-up. Preoperatively 44(88%) patients showed grade 2 positive pivot shift test while postoperatively only 1(2%) showed grade 2 positive pivot shift, and 47(94%) patients improved to grade 0 pivot shift. Similarly, 44(84%) patients were having grade 2 positive lachman test preoperatively which improved to 43(86%), showing grade 0 lachman test and only 5(10%) showed grade 2 positive lachman test.

Keywords: Anterior cruciate ligament, Quadrupled hamstring graft, Range of motion, Stability. (JPMA 65:S-215 (Suppl.3);2015)

Introduction

The anterior cruciate ligament (ACL) is the most common completely torn ligament in the knee.¹ ACL reconstruction is an effective method of treating instability and anterior tibial subluxation due to ACL tear.²⁻⁵ The aim of surgery is to restore the ACL function and proprioceptive mechanisms that are compromised due to traumatic ACL rupture, thus the risk of osteoarthritis is also reduced.⁶

The trend of operative reconstruction procedures for ACL rupture is rising with time and improved postoperative results are achieved with arthroscopic surgery and advancement of arthroscopic equipment. Different types of autografts are the most preferred form and way of surgical reconstruction of a ruptured ACL.^{3,4} Mostly bone-patellar tendon-bone (BPTB) and semitendinosus-gracilis (STG) autografts are used and both have been shown to produce 80% to 90% success rates.⁵ STG autograft are becoming increasingly popular because they result in comparatively less donor-site morbidity and less incidence of osteoarthritis.⁶

.....
Department of Orthopedic Surgery, Allied Hospital, Punjab Medical College, Faisalabad.

Correspondence: Rana Dawood Ahmad Khan. Email: doc_dawood@yahoo.com

The current study was planned to evaluate the 6-month clinical outcome of ACL reconstruction using a quadrupled hamstring autograft in terms of postoperative range of motion (ROM) compared with the normal unaffected knee and postoperative stability based on lachman test and pivot shift test after 6 months of postoperative rehabilitation.

Patients and Methods

The study was conducted at Allied Hospital, Faisalabad, Pakistan, from June 2011 to May 2014, and comprised patients having an isolated ACL rupture and otherwise not having any other comorbidity, or any previous surgery to the affected knee. After approval from the institutional ethics committee, relevant patients were enrolled who furnished written informed consent. Patients with multi-ligamentous injuries, previous surgery to same knee or having osteoarthritis were excluded.

Diagnosis was made primarily on the basis of physical examination findings. Two same team members performed Lachman test and pivot shift tests on all enrolled patients and this was the main basis of diagnosis and analysis of postoperative results. Preoperative record of physical findings and radiographs were made. One surgeon with the help of the same operating team and instruments performed all the operations using

autologous STG tendon graft. Postoperatively all patients were subjected to a standardised rehab protocol for 6months after which final readings were taken.

The affected knee joint was thoroughly examined under anaesthesia, knee instability findings were confirmed and documentation was done. Medial parapatellor approach was made. Femoral and tibial footprints and tunnels were prepared. STG tendons were harvested using tendon stripper, maximum tension was given using Naseer Awais (NA) fixator for five minutes, then tendon was folded four times and fixed in place using bioabsorbable screw and vicryl #1 suture.

A standardised postoperative rehabilitation protocol was given to all patients and it was supervised by two personnel and compliance was documented. For controlled mobilisation, knee braces were used for the first three weeks postoperatively. Assisted partial weight-bearing was allowed in the first three postoperative weeks. At the last follow-up, ROM, stability and knee proprioception was measured against the healthy side.

Statistical analysis was done using SPSS 17. Descriptive statistics, Student t test (paired or unpaired), chi-square analysis, Fisher exact tests were appropriately applied. Significance was established at $p < 0.05$.

Results

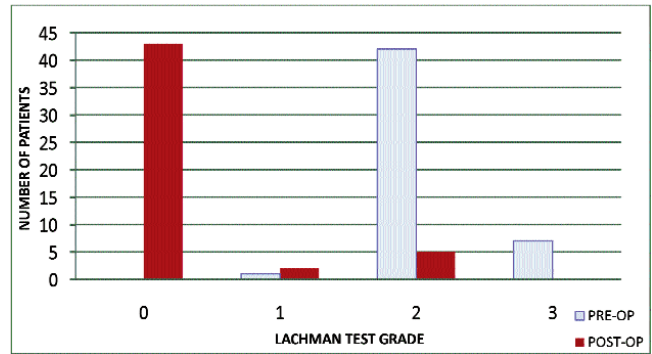
All the 50 patients in the study were males (100%) with a mean age of 35.02 ± 12.0 years (range: 18-53 years) (Table-

Table-1: Demographic Data.

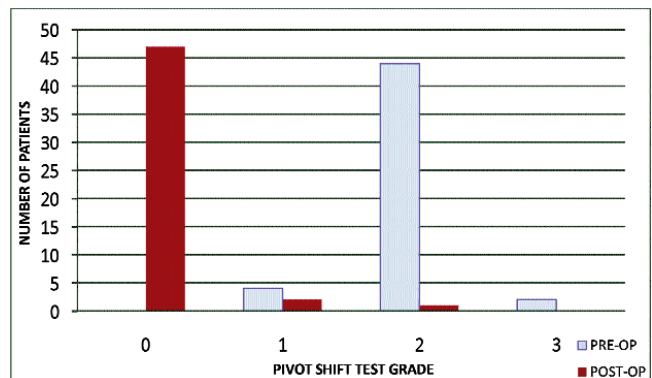
Variables	Patients
Number of patients	50
Gender	
Male	50
Female	0
Mean Age (y)	35.02 ± 12.0
Range (SD)	18-53
Days from injury to surgery	80 ± 5.43
Range (SD)	50-110
Total operative time \pm SD min	80 ± 6.74 min
Mechanism of injury	
Road Traffic Accident	44
Sports	4
Fall	1

Table-2: Range of motion (ROM) normal knee vs 6 month post-op knee.

Variable	Normal Knee Rom	Post-Operative Repair Rom
Flexion	$148^\circ (145-151)$	$135^\circ (130-145)$
Extension	$2^\circ (0-5)$	$2^\circ (0-3)$



Graph-1: Lachman Test. Preoperatively vs postoperatively.



Graph-2: Pivot shift test. Preoperatively vs postoperatively.



Figure-1: Stretching the graft.

1). Overall, 45(90%) ruptures were caused by RTAs, while 5(10%) were sports injuries. Mean time of surgery was 80 ± 6.74 minutes (range: 55-105 minutes).

At the final follow-up, 4(8%) patients had a flexion contracture of $< 5^\circ$. Mean extension was -2° (range: $-3^\circ - 0^\circ$),

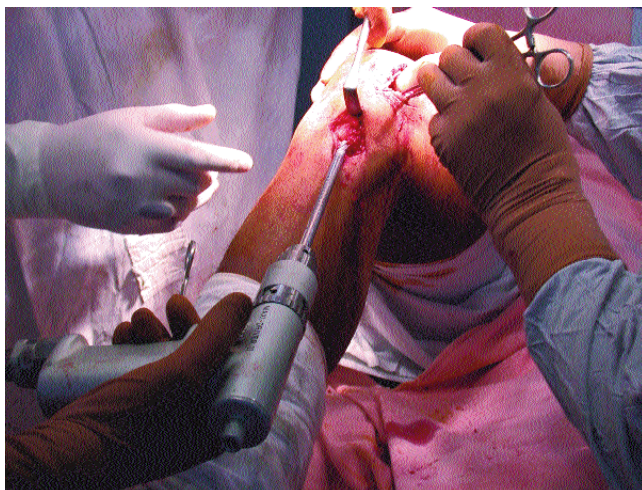


Figure-2: Creating tibial tunnel.

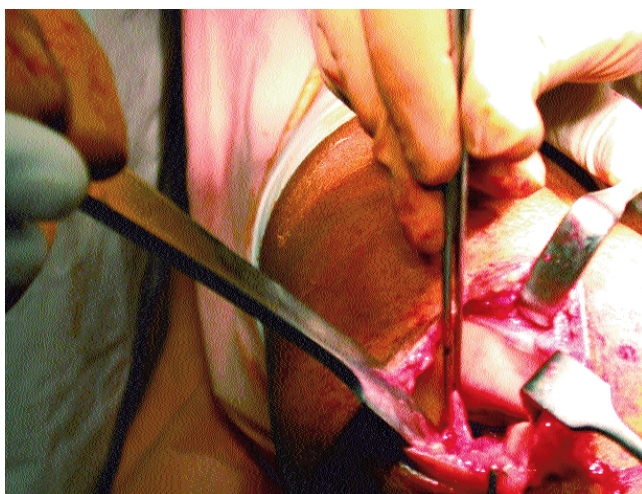


Figure-3: Remnants of ACL.

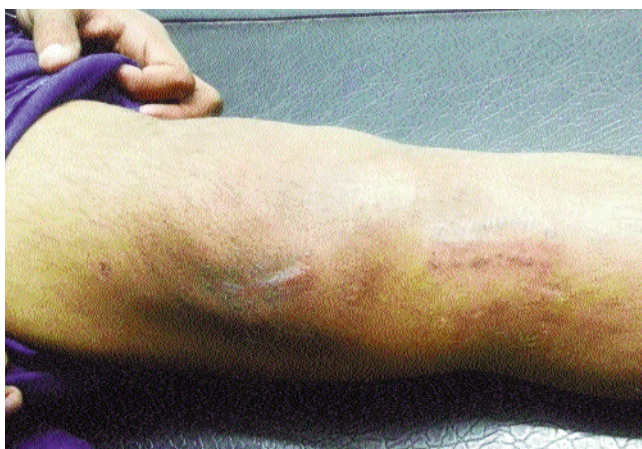

Figure-4: Follow up at 6 weeks.

and mean flexion was 135° (range: 130°-145°).

In terms of knee stability, 42(84%) patients showed grade2 positive lachman test, while at 6-month follow-up 43(86%) patients improved to grade0 lachman test. Only 5(10%) patients showed grade2 positive lachman test (Graph-1). On the pivot shift test, 44(88%) patients showed grade 2 pivot shift pre operatively (Graph-2). At 6-month follow-up, 47(94%) patients improved to grade0 and only 1(2%) patient was at grade2 postoperatively. At the end of 6 month period, the flexion and extension ROM of the operated knee was fairly comparable to normal unaffected knee as measured by goniometer (Table-2).

Discussion

Bone-patellar tendon-bone complex, hamstring tendon autografts, and allografts are commonly used as the graft sources, which graft is the most suitable is still controversial.⁷⁻⁹ Synthetic grafts are almost never used because of the poor results.¹⁰ Allografts are preferred by some surgeons because the grafts are easy to obtain in the desired sizes and have low perioperative morbidity, shorter operative time and less motion restriction in the postoperative period. However, the main disadvantages of reconstruction with allografts include disease transport, immunogenic rejection of the graft, and resorption in the tunnel, long remodelling period and high cost.¹¹

Donor-site morbidity has been reported following the application of autologous patellar tendon grafts, including kneeling pain, tendon shortening, patellar chondromalacia, patellar fractures, patellar tendon ruptures, patellofemoral pain syndromes and persistent quadriceps weakness.¹²⁻¹⁵

Hamstring tendons are biomechanically superior to the patellar tendon.^{16,17} Isometry of the anterolateral and posteromedial parts of the normal anterior cruciate ligament varies depending on the degree of knee flexion. Due to the four-strand structure, hamstring tendon grafts mimic this characteristic of ACL most closely.¹⁸ The use of quadruple hamstring grafts is not recommended in overweight patients (more than 100kg), sprinters and patients with medial laxity or with a pivot shift test result of 4(+), which constitutes the limitations of quadruple hamstring grafts.^{19,20}

Different methods are currently used in fixation with hamstring grafts. The most common include screws, EndoButtons and cross-pins. In a study conducted on graft fixation materials, Brand et al.²¹ stated that while cross-pins were not weaker than EndoButtons or other fixation methods in terms of force and loading, but the

disadvantages were reported to be the need for an additional incision and the occurrence of dilatation due to in-depth fixation in the tunnel.

Authors such as Howell²² and Beynon²³ do not have their patients use a brace following ACL reconstruction. Some studies have shown that aggressive rehabilitation immediately after surgery tends to increase knee laxity,^{23,24} while others have found no difference in subjective outcomes or functional stability.²⁵ Furthermore, Wright et al²⁶ conducted a systematic review confirming that the available evidence on postoperative bracing, immediate weight-bearing, and unrestricted ROM has largely been performed addressing BPTB grafts, demonstrating the lack of attention in comparison with STG grafts.

We used angle-adjustable hinged knee braces in the initial postoperative period for controlled mobilisation and protection of the graft integrity by reducing the load until adequate quadriceps strength was achieved.^{27,28} The principal aim was to obtain full quadriceps strength and good ROM and stability by the end of the follow-up. We continued the rehabilitation with isometric straight-leg-raising exercises and kept the brace during 3 to 6 weeks until a motion in range of 0-120° was obtained. After the removal of the drain, we mobilised our patients and allowed partial weight-bearing as much as tolerated. While early full weight-bearing may lead to haemarthrosis which can impair rehabilitation, it should not be delayed more than 3 weeks.^{28,29} This rehabilitation enabled all patients to return to full activity and appreciable stability within 6 months.

Aglietti et al. compared 30 knees with ACL tear constructed with BPTB graft against 30 knees with ACL tear reconstructed with hamstring autograft. They found translation of <5mm in 13% and 20% of the knees, respectively.²⁹ Other authors have reported tibial translation of >5 mm in 10% to 18% of patients following anterior cruciate reconstruction with a hamstring graft.^{30,31} We found tibial translation of between 3 and 5mm in 11% patients and of >5mm in 6%. Of the five patients in our series who had tibial translation of >5mm, three had a positive pivot shift test and two did not. The grafts in the latter two patients were not considered failures.

Noojin et al. reported a difference ($p < 0.05$) between the clinical failure rates in women (23%) and men (4%) in a group of 65 patients who had undergone anterior cruciate reconstruction with a four-strand hamstring autograft.³² But all of our patients were males and we did not come across a single female patient with isolated ACL

tear during the three years of our study

With the rehabilitation protocol used in our study, the majority of patients returned to a high functional status after 6 weeks. No motion deficits or clinically important knee pain was noted at the follow-up examination. Other authors have reported success with similar rehabilitation protocols following anterior cruciate reconstruction.³³⁻³⁶ The use of protected weight-bearing for three weeks following surgery did not significantly affect the findings on physical examination. Therefore, we now allow full weight-bearing with the knee in terminal extension in a brace in the immediate postoperative period and employ immediate passive ROM following the reconstruction.

Conclusion

The incidence of ACL tear in our entirely male population needs a mega analysis to determine gender bias as the size of our study population was too small to be generalised. The study and our growing experience of ACL reconstruction by quadrupled hamstring graft clearly indicates that STG autograft eliminates symptomatic anterior tibial subluxation due to torn ACL. Lachman test, pivot shift test all proved marked improvement in stability and a ROM comparable to that of the normal unaffected knee.

References

1. Muneta T, Sekiya I, Yagishita K, Ogiuchi T, Yamamoto H, Shinomiya K. Two-bundle reconstruction of the anterior cruciate ligament using semitendinosus tendon with endobuttons: operative technique and preliminary results. *Arthroscopy* 1999;15:618-624.
2. Reinhardt KR, Hetsroni I, Marx RG. Graft selection for anterior cruciate ligament reconstruction: a level I systematic review comparing failure rates and functional outcomes. *Orthop Clin North Am* 2010;41:249-262.
3. Ardern CL, Webster KE, Taylor NF, Feller JA. Return to sport following anterior cruciate ligament reconstruction surgery: a systematic review and meta-analysis of the state of play. *Br J Sports Med* 2011;45:596-606.
4. Holm I, Oiestad BE, Risberg MA, Aune AK. No difference in knee function or prevalence of osteoarthritis after reconstruction of the anterior cruciate ligament with 4-strand hamstring autograft versus patellar tendon-bone autograft: a randomized study with 10-year follow up. *Am J Sports Med* 2010;38:448-454.
5. Pinczewski LA, Lyman J, Salmon LJ, Russell VJ, Roe J, Linklater J. A 10-year comparison of anterior cruciate ligament reconstructions with hamstring tendon and patellar tendon autograft: a controlled, prospective trial. *Am J Sports Med* 2007;35:564-574.
6. Shelbourne KD, Gray T. Minimum 10-year results after anterior cruciate ligament reconstruction: how the loss of normal knee motion compounds other factors related to the development of osteoarthritis after surgery. *Am J Sports Med* 2009;37:471-480.
7. Gorschewsky O, Klakow A, Riechert K, Pitzl M, Becker R. Clinical comparison of the Tutoplast allograft and autologous patellar tendon (bone-patellar tendon-bone) for the reconstruction of the anterior cruciate ligament: 2- and 6-year results. *Am J Sports Med* 2005;33:1202-9.

8. Peterson RK, Shelton WR, Bomboy AL. Allograft versus autograft patellar tendon anterior cruciate ligament reconstruction: a 5-year follow-up. *Arthroscopy* 2001;17:9-13.
9. Tashiro T, Kurosawa H, Kawakami A, Hikita A, Fukui N. Influence of medial hamstring tendon harvest on knee flexor strength after anterior cruciate ligament reconstruction. A detailed evaluation with comparison of single- and double-tendon harvest. *Am J Sports Med* 2003;31:522-9.
10. Chun CH, Han HJ, Lee BC, Kim DC, Yang JH. Histologic findings of anterior cruciate ligament reconstruction with Achilles allograft. *Clin Orthop Relat Res* 2004;421:273-6.
11. Harner CD, Olson E, Irrgang JJ, Silverstein S, Fu FH, Silbey M. Allograft versus autograft anterior cruciate ligament reconstruction: 3 to 5 year outcome. *Clin Orthop Relat Res* 1996;324:134-44.
12. Indelli PF, Dillingham MF, Fanton GS, Schurman DJ. Anterior cruciate ligament reconstruction using cryopreserved allografts. *Clin Orthop Relat Res* 2004;420:268-75.
13. Feller JA, Webster KE, Gavin B. Early post-operative morbidity following anterior cruciate ligament reconstruction: patellar tendon versus hamstring graft. *Knee Surg Sports Traumatol Arthrosc* 2001;9:260-6.
14. Kartus J, Movin T, Karlsson J. Donor-site morbidity and anterior knee problems after anterior cruciate ligament reconstruction using autografts. *Arthroscopy* 2001;17:971-80.
15. Shelton WR, Papendick L, Dukes AD. Autograft versus allograft anterior cruciate ligament reconstruction. *Arthroscopy* 1997;13:446-9.
16. Spicer DD, Blagg SE, Unwin AJ, Allum RL. Anterior knee symptoms after four-strand hamstring tendon anterior cruciate ligament reconstruction. *Knee Surg Sports Traumatol Arthrosc* 2000;8:286-9.
17. Gillquist J, Odensten M. Arthroscopic reconstruction of the anterior cruciate ligament. *Arthroscopy* 1998;45-49.
18. Eriksson K, Anderberg P, Hamberg P, Löfgren AC, Bredenberg M, Westman I, et al. A comparison of quadruple semitendinosus and patellar tendon graft in reconstruction of the anterior cruciate ligament. *J Bone Joint Surg Br* 2001;83:348-54.
19. Williams RJ 3rd, Hyman J, Petrigliano F, Rozental T, Wickiewicz TL. Anterior cruciate ligament reconstruction with a four-strand hamstring tendon autograft. *J Bone Joint Surg Am* 2004;86:225-32.
20. Yasuda K, Tsujino J, Ohkoshi Y, Tanabe Y, Kaneda K. Graft site morbidity with autogenous semitendinosus and gracilis tendons. *Am J Sports Med* 1995;23:706-14.
21. Brand J Jr, Weiler A, Caborn DN, Brown CH Jr, Johnson DL. Graft fixation in cruciate ligament reconstruction. *Am J Sports Med* 2000;28:761-74.
22. Howel JG, Wertheimer C, Johnson RJ, Nichols CE, Pope MH, Beynnon B. Arthroscopic strain gauge measurement of the anterior cruciate ligament. *Arthroscopy* 1990;6:198-204.
23. Beynnon BD, Johnson RJ, Fleming BC. The science of anterior cruciate ligament rehabilitation. *Clin Orthop Relat Res* 2002;402:9-20.
24. Heijne A, Werner S. A 2-year follow-up of rehabilitation after ACL reconstruction using patellar tendon or hamstring tendon grafts: a prospective randomized outcome study. *Knee Surg Sports Traumatol Arthrosc* 2010;18:805-813.
25. Poolman RW, Farrokhlyar F, Bhandari M. Hamstring tendon autograft better than bone patellar-tendon bone autograft in ACL reconstruction: a cumulative meta-analysis and clinically relevant sensitivity analysis applied to a previously published analysis. *Acta Orthop* 2007;78:350-354.
26. Wright RW, Preston E, Fleming BC, Amendola A, Andrish JT, Bergfeld JA, et al. A systematic review of anterior cruciate ligament reconstruction rehabilitation: part I: continuous passive motion, early weight bearing, postoperative bracing, and home-based rehabilitation. *J Knee Surg* 2008;21:217-224.
27. Dunn WR1, Lincoln AE, Hinton RY, Smith GS, Amoroso PJ. Occupational disability after hospitalization for the treatment of an injury of the anterior cruciate ligament. *J Bone Joint Surg Am* 2003;85:1656-66.
28. Wexler G, Hurwitz DE, Bush-Joseph CA, Andriacchi TP, Bach BR Jr. Functional gait adaptations in patients with anterior cruciate ligament deficiency over time. *Clin Orthop Relat Res* 1998;348:166-75.
29. Aglietti P, Buzzi R, Zaccherotti G, De Biase P. Patellar tendon versus doubled semitendinosus and gracilis tendons for anterior cruciate ligament reconstruction. *Am J Sports Med* 1994;22:211-8.
30. Meystre JL, Vallotton J, Benvenuti JF. Double semitendinosus anterior cruciate ligament reconstruction: 10-year results. *Knee Surg Sports Traumatol Arthrosc* 1998;6:76-81.
31. Nebelung W, Becker R, Merkel M, Röpke M. Bone tunnel enlargement after anterior cruciate ligament reconstruction with semitendinosus tendon using Endobutton fixation on the femoral side. *Arthroscopy* 1998;14:810-5.
32. Noojin FK, Barrett GR, Hartzog CW, Nash CR. Clinical comparison of intraarticular anterior cruciate ligament reconstruction using autogenous semitendinosus and gracilis tendons in men versus women. *Am J Sports Med* 2000;28: 783-9.
33. Segawa H, Omori G, Tomita S, Koga Y. Bone tunnel enlargement after anterior cruciate ligament reconstruction using hamstring tendons. *Knee Surgery Sports Traumatol Arthrosc*. 2001 Jul;9(4):206-10
34. Howell SM, Taylor MA. Brace-free rehabilitation, with early return to activity, for knees reconstructed with a double-looped semitendinosus and gracilis graft. *J Bone Joint Surg Am* 1996;78:814-25.
35. MacDonald PB, Hedden D, Pacin O, Huebert D. Effects of an accelerated rehabilitation program after anterior cruciate ligament reconstruction with combined semitendinosus-gracilis autograft and a ligament augmentation device. *Am J Sports Med* 1995;23:588-92.
36. Shelbourne KD, Nitz P. Accelerated rehabilitation after anterior cruciate ligament reconstruction. *Am J Sports Med* 1990;18:292-9.