

Multi level lumbosacral spinal fusion including lumbo-Sacral (L5-S1) junction fixation in adult deformity surgery; is postero- lateral fusion at (L5-S1) alone adequate?

Ahmed Bilal Khaliq, Ibrahim Farooq Pasha, Akmal Sultan, Waseem Afzal, Muhammad Asad Qureshi

Abstract

Background/aims: To assess the revision rate at L5-S1 when only posterior fixation with pedicle screws is done with multi-level spinal fixation.

Patients and Methods: The Retrospective quasi experimental study was conducted at the Combined Military Hospital, Rawalpindi and comprised data from 2009 to 2014 of patients in whom multi-level posterior decompression including lumbosacral junction (L5-S1) with laminectomy and posterior fixation with pedicle screws was done till L3 and higher. Those with known cause of implant failure like osteoporosis, osteomalacia and infection were excluded. Patients were followed up and need for revision at L5-S1 level was assessed.

Result: Of the 22 cases, 5(23%) were males and 17(77%) were females with an overall mean age of 64 ± 10.38 years (range 48-84 years). Mean number of levels fixed was 5.22 ± 1.15 the highest level of fixation being T11. Mean follow-up was 08 ± 3.22 months and focused only at the failure of fixation at L5-S1. Two (9%) cases showed implant loosening and required revision at L5-S1 because of screw cut out.

Conclusion: Properly placed pedicle screws were adequate with fusion for multilevel spinal fixations.

Keywords: Lumbosacral junction, Posterior fixation, Pedicle screws, Spinal fixations. (JPMA 65: S-152 (Suppl. 3); 2015)

Introduction

Adult deformity is one the most common disorders which a spine surgeon is faces in the developed world. The reported prevalence has a wide range of 8.3 to 68%.¹⁻³ Moreover elderly population has a much higher prevalence of scoliosis of 68% at mean age of 70 years.¹ As the quality of health care improves and life expectancy increases in our part of the world these disorders will be more frequently encountered and operated upon here as well. Adult deformity is a combination of spinal stenosis, instability, disc degeneration facet joint arthropathy and idiopathic scoliosis.⁴

Surgical procedures performed in adult deformity range from simple decompression to complex fixation. Usually it is a combination of both the procedures. More extensive decompression requires extensive fixation to hold the spine in place till the time the bony fusion occurs. The combined fusion and decompression procedures have been reported to have a good outcome in this population.⁵

When a patient is fixed beyond L3 there is an increased failure rate at the S1 pedicle screw.⁶ Various strategies have been suggested to improve the survival of fixation at

the base. Commonly suggested are a 360 degree fusion at L5-S1⁷⁻⁸ or extending the fixation to iliac wing is recommended in cases when performing fixation beyond L3.⁹ Both these approaches lead to an increased operating time, increased incidence of complication and not to mention the increased morbidity especially associated with iliac fixation.

Our population is leading a much more sedentary life in advanced ages as compared to Western population and in our clinical observation we did not see an increase in the complication in the base when fixation was only carried till S1 without doing either discectomy and fusion or iliac wing fixation. In this study we followed our cases in which extensive fixation without doing discectomy and fusion or including ilium in fixation.

The current study was planned to assess the revision rate at L5-S1 when only posterior fixation with pedicle screws was done with multi-level spinal fixation.

Patients and Methods

The retrospective quasi experimental study was conducted at the Combined Military Hospital (CMH), Rawalpindi and comprised data from January 1, 2009 to June 30, 2014 of patients in whom multi-level posterior decompression, including lumbosacral junction (L5-S1) with laminectomy and posterior fixation with pedicle screw, was done till L3 and higher. Those included were

.....
Combined Military Hospital, Rawalpindi.

Correspondence: Ahmed Bilal Khaliq. Email: drdoormouse@gmail.com

cases who underwent long surgery was carried out for spinal stenosis, degen scoliosis and instability only.

Cases where discectomy of L5-S1 was performed along with bone grafting; patients in whom fixation was carried till ilium; those who had poor bone quality because of osteoporosis or other metabolic conditions; patients developing post operative deep wound infection; those in whom screw augmentation was done using bone cement; patient having surgical fixation other than those mentioned in the inclusion criteria; those with neurological deficit; and patients who were lost to follow-up or having a follow-up less than 6 months.

Patients records were analyzed and demographic data was collected about gender, age, co-morbid. Dual energy absorptionmetry (DEXA) scan was used to determine bone density. Surgical records were reviewed for levels fused, decompression type and type of fusion performed. Last follow-up X-rays were analysed for evidence of fusion. These patients were further analysed for any revision surgery. Any revision surgery carried out at L5-S1 due to any kind of failure was recorded. Extension of fixation cranially was disregarded as failure of fixation. Solid fusion and asymptomatic pseudarthrosis was regarded as adequate treated case.

Pre-operative radiographs and magnetic resonance imaging (MRI) scan followed by pedicle screw fixation were reviewed. The spine was instrumented from T11 till S1. The fixation was stopped at Sq and no anterior discectomy was done. Posterolateral fusion was attempted and the deformity was corrected (Figure-1).

Preoperative images of the spine with decompression from L2-S1 by posterior laminectomy and fixation by pedicle screws were also recorded. Correction has been achieved by applying contoured rods (Figure-2).

In terms of fixation management the fixation was carried till ilium and the additional screws were cement augmented. To prevent the collapse of the top vertebrae it has been cement augmented to make it more rigid (Figure-3).

Mean and standard deviation was calculated for age, levels fixed, while frequencies and percentages were calculated for gender. The revision rate was measured for L5-S1 fixation.

Results

Of the 22 cases, 5(23%) were males and 17(77%) were females with an overall mean age of 64 ± 10.38 years (Range 48-84 years) Decade wise frequency was plotted and most patients were found to be in 6th and 8th decade

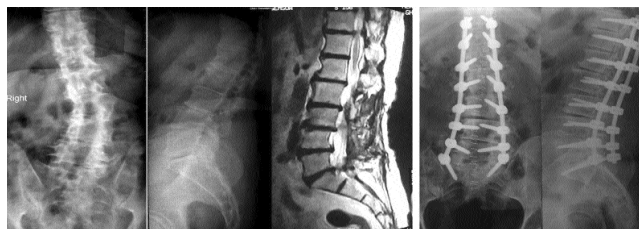

Figure-1: Preoperative and post operative radiographs and magnetic resonance imaging (MRI) scan. Marked correction was achieved after pedicle instrumentation.

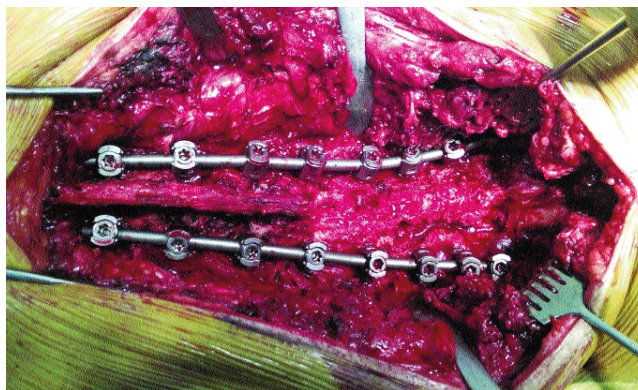

Figure-2: A peroperative photograph showing posterior decompression and pedicle screw fixation.

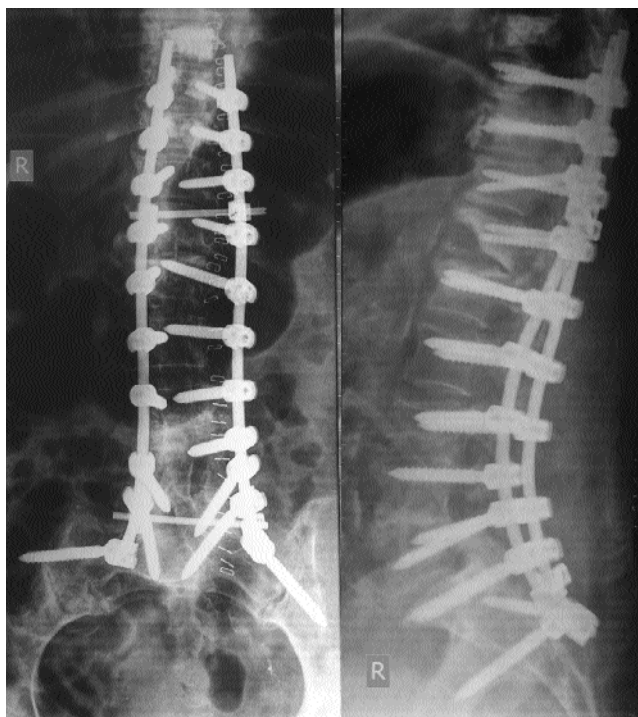

Figure-3 The revision of fixation in a case with failure of fixation at L5-S1 level treated with iliac screws and cement augmentation.

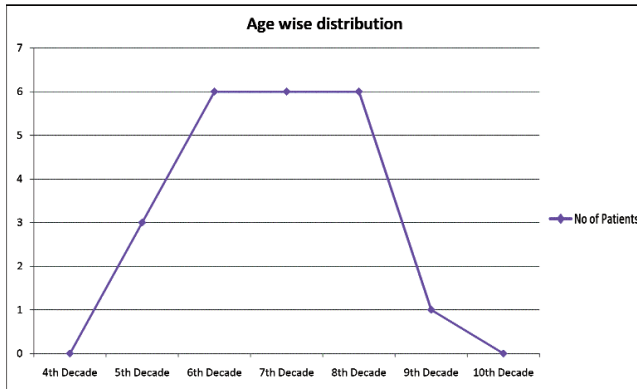


Figure-4: Number of patients in each decade of life.

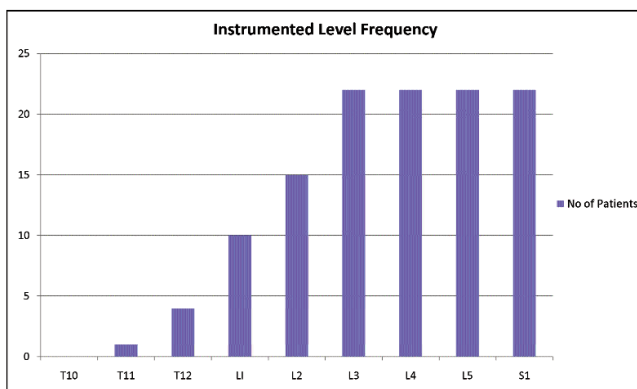


Figure-5: Frequency of instrumentation at each level.

of life (Figure-4).

The mean number of levels fixed was 5.27 (\pm 1.16) the highest level of fixation being T11. Eight (36%) patients had 6 or more levels fixed. The number of patients at L3-S1 was the same as the number of patients in the study (Figure-5).

Mean follow-up was 8 \pm 3.22 months and focused only at the failure of fixation at L5-S1. Two (9%) cases showed implant loosening and required revision at L5-S1 because of screw cutout. These were managed by extension of fixation.

Discussion

The decision to include L5-S1 joint in a fixation is a major undertaking. Every effort is usually made to spare this segment as it is the most mobile joint. When this is included in the fixation the stress on the construct is increased manifold and chances of pseudarthrosis are high.^{10,11} If we spare L5-S1 to preserve mobility we may be

faced with a revision later as there is usually disc degeneration at this level in most cases,⁴ so stopping at L5 enhances the degeneration at that level.¹² This situation is further complicated by the presence of spondylolisthesis at this level in many cases.¹³

The researchers have used various techniques to improve the fusion at L5-S1. The pseudarthrosis at this level is marked by the presence of rod breakage.⁶ Birdwell et al¹⁴ looked at the various ways employed to this fixation which included anterior grafting, extension of fixation till ilium^{6,15} and extension of fixation till sacral 2.^{16,17} The aim of all these strategies is to increase the rigidity at L5-S1¹⁸ and hence even in the presence of pseudarthrosis at L5-S1 there was no case reported for fixation failure in as series.¹⁴ It was further confirmed by other researchers.¹⁹ This comes at the price of increased blood loss, increased operating time, increased incidence of complication of surgery²⁰ and hardware placement complications.²¹

In our study we looked at the failures in our cases which had no major risk factor to cause hardware problems so as to isolate the complications arising due to limitation of fixation till S1 without doing anterior discectomy or extending till ilium.

The failure rates in our study is not as high as reported by other researches.^{5,13,15,21} The possibility is that we aimed to remove all those cases that had host factors for hardware-related complication like decreased bone density. Another reason can be due to the fact that our population is leading a much more sedentary life style compared to Western population especially in the later part of life. This causes decreased loading to the construct leading to better survival of fixation.

Even those cases in which we had to revise the pseudarthrosis at L5-S1 caused rod breakage which is a common indication for revision in studies reported above. However, our indications for revision were screw cutouts, which would be ascribed to the fact that either the screw at L5-S1 was malplaced or failed to achieve anterior cortical fixation by sacral pedicle at sacral promontory.²²

Therefore it can be stated that in our low-demand population there was very little clinical indication to undertake the fixation till ilium or to do anterior fusion at L5-S1 while performing long fixation. Further good-quality multicentre prospective randomised clinical trials are needed to better answer this issue.

Conclusion

In low-demand patients without major risk factors to hardware failures long lumbar fixation can be started

from S1 without performing anterior discectomy or ilium fixation.

References

1. Carter OD, Haynes SG. Prevalence rates for scoliosis in US adults: results from the first National Health and Nutrition Examination Survey. *Int J Epidemiol* 1987; 16: 537-44.
2. Schwab F, Dubey A, Gamez L, El Fegoun AB, Hwang K, Pagala M, et al. Adult scoliosis: prevalence, SF-36, and nutritional parameters in an elderly volunteer population. *Spine (Phila Pa 1976)* 2005; 30: 1082-5.
3. Hong JY, Suh SW, Modi HN, Hur CY, Song HR, Park JH. The prevalence and radiological findings in 1347 elderly patients with scoliosis. *J Bone Joint Surg Br* 2010; 92: 980-3.
4. de Schepper EI, Damen J, van Meurs JBJ, Ginai AZ, Popham M, Hofman A, et al. The association between lumbar disc degeneration and low back pain: the influence of age, gender, and individual radiographic features. *Spine (Phila Pa 1976)* 2010; 35: 531-6.
5. Rillardon L, Guigui P, Veil-Picard A, Slulittell H, Deburge A. [Long-term results of surgical treatment of lumbar spinal stenosis]. *Rev Chir Orthop Reparatrice Appar Mot* 2003; 89: 621-31.
6. Harimaya K, Mishiro T, Lenke LG, Bridwell KH, Koester LA, Sides BA. Etiology and revision surgical strategies in failed lumbosacral fixation of adult spinal deformity constructs. *Spine (Phila Pa 1976)* 2011; 36: 1701-10.
7. Ploumis A, Simpson AK, Cha TD, Herzog JP, Wood KB. Coronal spinal balance in adult spine deformity patients with long spinal fusions: a minimum 2-5 year follow-up study. *J Spinal Disord Tech* 2013. doi: 10.1097/BSD.0b013e3182aab2ff
8. Cho W, Mason JR, Smith JS, Shimer AL, Wilson AS, Shaffrey CI, et al. Failure of lumbopelvic fixation after long construct fusions in patients with adult spinal deformity: clinical and radiographic risk factors: clinical article. *J Neurosurg Spine* 2013; 19: 445-53.
9. Ould-Slimane M, Miladi L, Rousseau MA, Bonaccorsi R, Catonne Y, Lazennec JY, et al. Sacropelvic fixation with iliosacral screws: applications and results in adult spinal deformities. *J Spinal Disord Tech* 2013; 26: 212-7.
10. Kim YJ, Bridwell KH, Lenke LG, Cho KJ, Edwards CC 2nd, Rinella AS. Pseudarthrosis in adult spinal deformity following multisegmental instrumentation and arthrodesis. *J Bone Joint Surg Am* 2006; 88: 721-8.
11. Kostuik JP, Hall BB. Spinal fusions to the sacrum in adults with scoliosis. *Spine (Phila Pa 1976)* 1983; 8: 489-500.
12. Zencica P, Chaloupka R, Hladíková J, Krbec M. [Adjacent segment degeneration after lumbosacral fusion in spondylolisthesis: a retrospective radiological and clinical analysis]. *Acta Chir Orthop Traumatol Cech* 2010; 77: 124-30.
13. Christensen FB. Lumbar spinal fusion. Outcome in relation to surgical methods, choice of implant and postoperative rehabilitation. *Acta Orthop Scand Suppl* 2004; 75: 2-43.
14. Bridwell KH, Edwards CC 2nd, Lenke LG. The pros and cons to saving the L5-S1 motion segment in a long scoliosis fusion construct. *Spine (Phila Pa 1976)* 2003; 28(20 Suppl): S234-42.
15. Tsuchiya K, Bridwell KH, Kuklo TR, Lenke LG, Baldus C. Minimum 5-year analysis of L5-S1 fusion using sacropelvic fixation (bilateral S1 and iliac screws) for spinal deformity. *Spine (Phila Pa 1976)* 2006; 31: 303-8.
16. Park YS, Kim HS, Baek SW, Lee SH. Lumbosacral fixation using the diagonal S2 screw for long fusion in degenerative lumbar deformity: technical note involving 13 cases. *Clin Orthop Surg* 2013; 5: 225-9.
17. Koller H, Zenner J, Hempfing A, Ferraris L, Meier O. Reinforcement of lumbosacral instrumentation using S1-pedicle screws combined with S2-alar screws. *Oper Orthop Traumatol* 2013; 25: 294-314.
18. Alegre GM, Gupta MC, Bay BK, Smith TS, Laubach JE. S1 screw bending moment with posterior spinal instrumentation across the lumbosacral junction after unilateral iliac crest harvest. *Spine (Phila Pa 1976)* 2001; 26: 1950-5.
19. Emami A, Deviren V, Berven S, Smith JA, Hu SS, Bradford DS. Outcome and complications of long fusions to the sacrum in adult spine deformity: luque-galveston, combined iliac and sacral screws, and sacral fixation. *Spine (Phila Pa 1976)* 2002; 27: 776-86.
20. Proietti L, Scaramuzza L, Schiro' GR, Sessa S, Logroscino CA. Complications in lumbar spine surgery: a retrospective analysis. *Indian J Orthop* 2013; 47: 340-5.
21. Edwards CC 2nd, Bridwell KH, Patel A, Rinella AS, Berra A, Lenke LG. Long adult deformity fusions to L5 and the sacrum. A matched cohort analysis. *Spine (Phila Pa 1976)* 2004; 29: 1996-2005.
22. Kato M, Taneichi H, Suda K. Advantage of pedicle screw placement into the sacral promontory (tricortical purchase) on lumbosacral fixation. *J Spinal Disord Tech* 2015; 28: E336-42. doi: 10.1097/BSD.0b013e31828ffc70.