

Outcome of ilizarov fixator in complex non-union of long bones

Muhammad Shoab Khan, Waqas Raza, Hidayat Ullah, Abdus Samad Khan, Muhammad Siraj, Zahid Askar

Abstract

Objectives: To evaluate the efficacy of Ilizarov fixator in the management of complex non-union of long bones.

Methods: The retrospective study was conducted at Ayub Teaching Hospital, Abbottabad, and Khyber Teaching Hospital, Peshawar, Pakistan, and comprised data of patients aged 14- 60 years of either gender with complex non-union of long bones between January 2006 and December 2013. Data, including age, gender, mechanism of injury, type of long bone involved, complications of surgery and final outcome, was documented on a pre-designed proforma. Outcome was graded using Association for the Study and Application of Methods of Ilizarov scoring system. SPSS 20 was used for analysis.

Results: There were 45 patients of whom 30(66.7%) were males and 15(33.4%) were females. The overall mean age was 32.20±12.48 years (range: 14-60 years).Of the 45 non-unions, 39(86%) healed successfully, and the mean time to union was 30.69±8.6 weeks (range: 16-52weeks).In terms of outcome, 29(64.44%) patients had excellent bone results, 9(20%) had good results, 2(4.44%) had fair results and 5(11.1%) had poor bone results. There were 32(71.11%) patients with excellent functional result, 8(17.77%) good, 2(4.44%) fair and 3(6.66%) patients had poor results.

Conclusion: Ilizarov fixator gave good and excellent results in complex non-union of long bones by eradicating the infection, filling the defect with bone transport, and correcting the deformity and limb length discrepancy.

Keywords: Complex non-union, Long bones, Ilizarov fixator, Reflex sympathetic dystrophy, Limb length discrepancy. (JPMA 65: S-147 (Suppl. 3); 2015)

Introduction

Ilizarov has been named after the orthopaedic surgeon Gavril Abramovich Ilizarov from the Soviet Union, who pioneered the technique.¹ The apparatus is based on the principle which Ilizarov called as "the theory of tensions."² It can be used for the treatment of infected non-union and mal-union of bones, limb lengthening, height increase and badly comminuted fractures (multiple fragments) in the limbs, even with skin loss.³⁻⁵ It is used in surgical procedures that are not amenable with other techniques.⁶ In addition to being used to support a fractured limb, the Ilizarov apparatus is also commonly used to correct deformity through distraction osteogenesis.⁷ This method is preferred over conventional treatment options such as internal fixation or cast where there is a high risk of infection or the fracture is of such severity that internal fixators are unworkable.⁸ The circular construction and tensioned wires of the Ilizarov apparatus provide far more structural support than the traditional mono-lateral fixator system. This allows early weight-bearing.^{9,10} Management of non-union with bony defect in long bones is a challenging problem for orthopaedic surgeons. There are

various techniques to fill the defect in long bones, i.e. cancellous bone grafting for small defect,¹¹ vascularised fibular grafts, allograft and papineau technique of bone grafting¹² for larger bone defects.

Union with bony defect in long bones is a challenging problem for orthopaedic surgeons. There are various techniques to fill the defect in long bones, i.e. cancellous bone grafting for small defect,¹¹ vascularised fibular grafts, allograft and papineau technique of bonegrafting¹² for larger bone defects.

When the defect is more than 4cm, it needs bone transport which can be done by ring fixators, modified Arbeitsgemeinschaft für Osteosynthesefragen (AO) fixators or specialised intramedullary nails. However, infection, bone exposure, bone loss, deformity or failures of previous internal fixation are relative contraindications to internal fixation. In these more complicated cases, which we define as complex non-union, the Ilizarov method is particularly valuable. The choice in such patients may be between limb salvage using the Ilizarov method and amputation. Complex non-union is defined as an established non-union of at least six months in duration with one or more of the following criteria: infection at the site of non-union; a bone defect of more than 4 cm (defect non-union); and an attempt to achieve union that failed to heal after at least one supplementary

.....
Department of Orthopedics, Khyber Teaching Hospital, Peshawar and Ayub Teaching Hospital, Abbottabad.

Correspondence: Muhammad Shoab Khan. Email: drshoabortho@yahoo.com

intervention, for example, bone grafting or exchange nailing. Complex non-union poses a formidable challenge to both the surgeon and the patient. The Ilizarov treatment has been successful in managing most problems in these patients, but it is not a panacea.

The current study was planned to evaluate the efficacy of treatment by Ilizarov frame in patients with complex non-union of long bones. The hypothesis was that Ilizarov is the only treatment modality which treats all 4 components of the complex non-union, infection, deformity, bone loss and non-union.

Materials and Methods

The retrospective study was conducted at Ayub Teaching Hospital, Abbottabad, and Khyber Teaching Hospital, Peshawar, Pakistan, and comprised data of patients aged 14-60 years of either gender with complex non-union of long bones and complete follow-up between January 2006 and December 2013. Patients with Intra-articular fractures and a fracture along with vascular injury were excluded.

Ilizarov fixators were used in all cases and all procedures had been done under general or spinal anaesthesia with antibiotic prophylaxis. Proper wound debridement with resection of infected dead bone had been done when needed. Metaphyseal /diaphysial osteotomy was done in the same sitting or after eradicating the infection with debridement and antibiotic in selective cases. Antibiotic protocol was followed according to culture and sensitivity when required.

After the application of each fixator, radiographs were taken. All factors were correlated with eventual time to union and the presence of mal-union. If X-ray showed incorrect positioning of the pin/fragments, correction was made to avoid difficulties later on. Physical therapy was continued throughout the treatment duration and wound-site and pin site condition of the wound. All patients had been educated regarding bone transport and pin site care. Patients were followed every 2-4 weeks with radiographs of the involved extremity to look for regenerate and union, till full healing of the bones. Minimum follow-up of patients was 24 weeks (upto 52 weeks), according to the criteria of the Association for the Study and Application of Methods of Ilizarov (ASAMI). The fracture union, complications and functional recoveries were also recorded during follow-up. Our criteria of union were the presence of bridging trabeculae on three cortices radiologically, absence of pain and movement at the union site clinically. The ASAMI outcome measurement (Table-1) divides the results into bone and functional, and has been often used in earlier studies.¹³⁻¹⁵

At final follow-up, patients were assessed for gait, limb length discrepancy (LLD) and range of motion (ROM) of the adjacent joints.

Data collected was analysed using SPSS19.

Results

There were 45 patients of whom 30(66.7%) were males

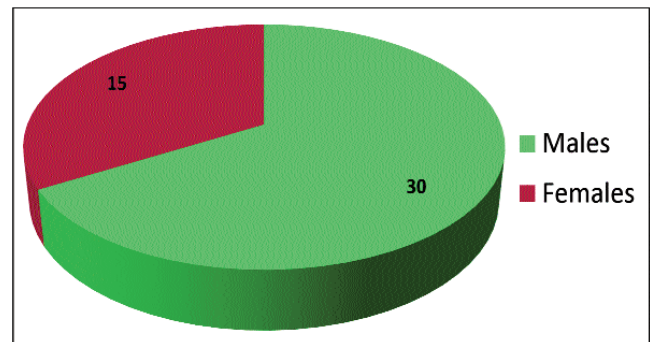


Figure-1: Gender- wise distribution of patients (N=45).

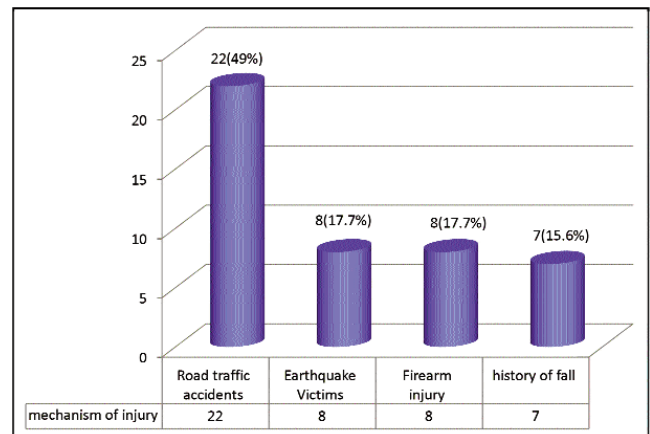


Figure-2: Mechanism of injury.

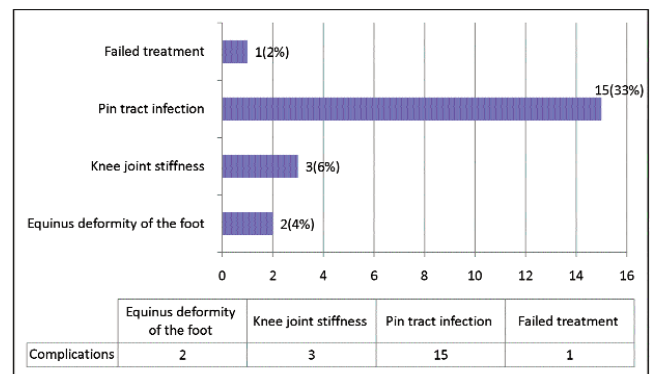


Figure-3: Complications of procedure.

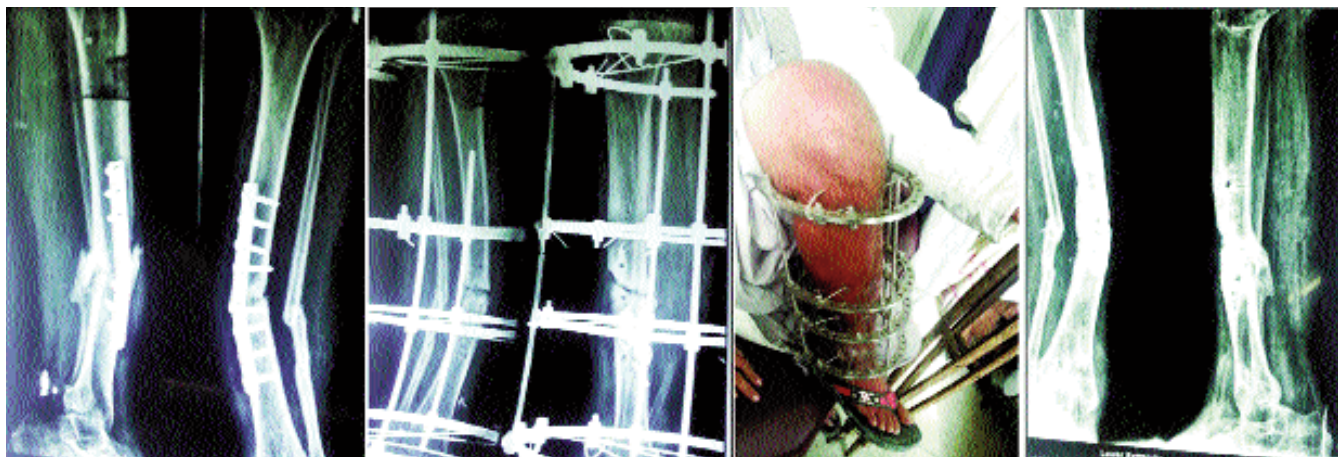

Figure-4: X-rays of patient with broken tibial plate after Ilizarov application. Final X-ray after removal of Ilizarov with good union. Picture showing good knee range of motion (ROM).

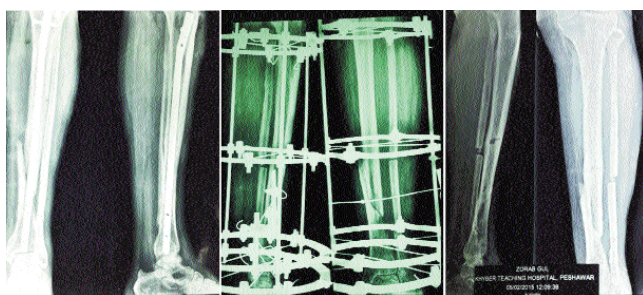


Figure-5: X-ray showing tibia non-union with intra-medullary nail after removal of nail and application of Ilizarov. Final X-ray after removal of Ilizarov with good.

and 15(33.4%) were females (Figure-1). The mean age was 32.20 ± 12.48 years (range: 14-60 years).

Tibia was the most commonly involved bone in 31(68.8%) patients followed by femur 10(22%). Other involved bones were Radius/Ulna 2(4%) and Humerus 2(4%) (Table-2). In 35(77.77%) patients, there were failed previous surgical attempts either by internal or external fixation.

Out of the 35 failed implants, 16(45.7%) were external fixators, 10(28.6%) were plates and 9(25.7%) were intramedullary nails. The initial mechanism of injury was road traffic accidents (RTAs) in 22(49%) cases, earthquake victims 8(17.7%), firearm injuries 8(17.7%), and fall from height 7(15.6%) (Figure-2). Of the 45 non-unions, 39(86%) healed successfully, and the mean time to union was 30.69 ± 8.6 weeks (range: 16-52 weeks).

Limb-lengthening or filling-bone defect was treated through bone transport in 20(44.44%) cases. Bone grafting at docking site was done in 3(6%) patients. Complications in our study were equinus deformity of the foot in 2(4%) that were later on corrected by putting another Ilizarov ring in the foot; knee joint stiffness in 3(6%) cases; pin tract infection in 15(33%) cases who recovered with treatment; and failed treatment in 1(2%) case (Figure-3).

According to ASAMI criteria, 29(64.44%) had excellent bone results, 9(20%) had good results and 2(4.44%) had fair results. There were 5(11.1%) poor bone results. There were 32(71.11%) patients with excellent functional results,

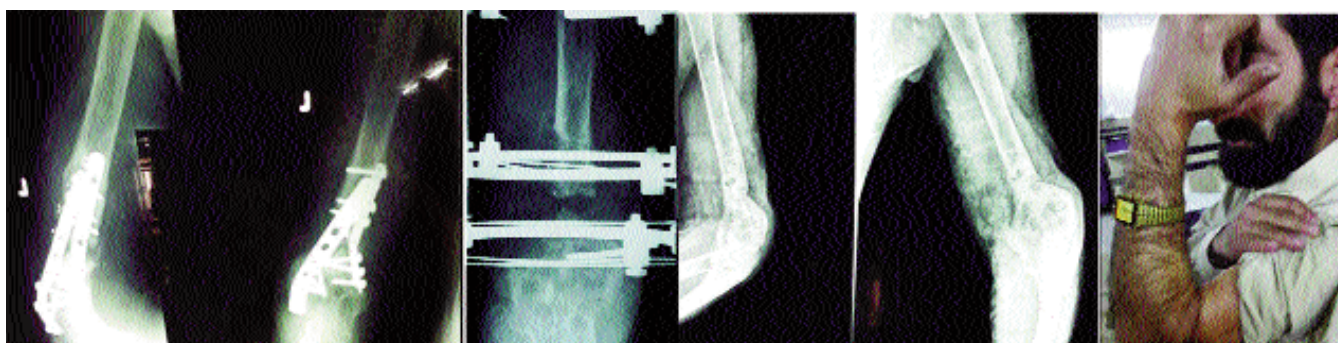


Figure-6: Complex non-union left Humerus with plates after removal of plates and application of Ilizarov. Final history after removal of Ilizarov with good healing. Picture showing good elbow range of motion (ROM).

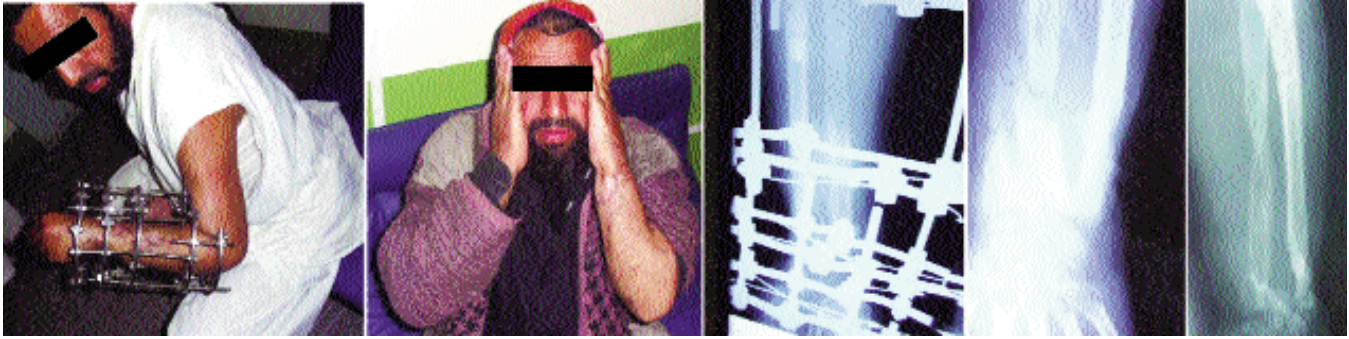

Figure-7: X-ray of chronic osteomyelitis (COM) of left distal radius, excision of sequestrum, Ilizarov application and bone transport. Final radiological and functional results.

Table-1: Association for the Study and Application of Methods of Ilizarov (ASAMI) scoring system.

Bone results	
Excellent	Union, no infection, deformity < 7°, limb length discrepancy < 2.5cm,
Good	Union + any two of following. Absence of infection, deformity < 7°, limb length discrepancy < 2.5cm,
Fair	Union + any one of following. Absence of infection, deformity < 7°, limb length discrepancy < 2.5cm,
Poor	Non-union/ re-fracture/union + infection + deformity > 7° + limb length inequality > 2.5cm
Functional results	
Excellent	Active, no limp, minimum stiffness (loss of < 15° knee extension / < 15° Dorsiflexion of ankle), no reflex sympathetic dystrophy, insignificant pain.
Good	Active, with one or two of following: Limp, stiffness, RSD, significant pain
Fair	Active, with three or all of the following: Limp, stiffness, RSD, significant pain
Poor	Inactive (unemployment or inability to return to daily activities because of injury), Amputation

Table-2: Types of long bones involvement (N=45).

Types of long bones involvement	No of patients	Percentage of patients
Tibia patients followed by patients		
Other involved bones were and s	31	68.8%
Femur	10	22%
Radius/Ulna	02	4%
Humerus	02	(4%)

8 (17.77%) had good results and 2 (4.44%) had fair results. 3 (6.66%) patients had poor functional results. Results were also calculated for individual bones (Table-3).

The radiological and functional results of tibia (Figure-4,5), humerus (Figure-6) and radius/ulna (Figure-7) are shown.

Discussion

The treatment of complex non-union of long bones is a challenge for orthopaedic surgeons. Ilizarov is a

Table-3: Outcome of individual bone according to association for the study and application of methods of ilizarov (ASAMI) criteria (N=45).

Bone results	Tibia (Total 31)	Femur (Total 10)	Humerus (Total 2)	Radius/ Ulna (Total 2)
Excellent (Total 29)	20(64.51%)	7(70%)	1(50%)	1(50%)
Good (Total 9)	6(19.35%)	2(20%)	1(50%)	-
Fair (Total 2)	1(3.22%)	-	-	1(50%)
Poor (Total 5)	4(12.90%)	1(10%)	-	-
Functional results				
Excellent (Total 32)	27(87.1%)	3(30%)	1(50%)	1(50%)
Good (total 8)	3(9.7%)	4(40%)	-	1(50%)
Fair (Total 2)	-	1(10%)	1(50%)	-
Poor (Total 3)	1(3.2%)	2(20%)	-	-

specialised modality of treatment which can address all the problems in complex non-unions simultaneously. The most important thing is that the patient can mobilise soon after the operation with Ilizarov apparatus.

In our study, the radiological results were excellent both in femur (70%) and tibia (64.51%). However, the functional results were more excellent in tibia (87.1%) compared to femur (30%). As the number of cases in Humerus and radius/ulna were very limited (2 each), we cannot comment on their outcome. Pin tract infection (33%) was the most common complication, mostly in tibia, which was treated with antibiotics (Figure-6). After the removal of Ilizarov, good healing was noted (Figure-7).

Knee stiffness occurred in 6% cases, mostly in femur patients. Knee ROM exercises were advised after frame removal, which slightly improved the knee movements. Equinus deformity of the foot occurred in 4% cases which were later on corrected by putting another Ilizarov ring in the foot. In the study by Paley D et al 1625 cases of tibial non-union were treated with Ilizarov fixators which showed excellent bone results in 18(72%) cases, good in 5(20%) and fair in 2(8%) based on union. Functional results were excellent in 16(64%) cases, good in 7(28%), fair in 1(4%) and poor in 1(4%) based on return to daily activities. In another study on 58 patients with tibial non-union, 38 (65.52%) patients had infected non-union, while 20(34.48%) had clean non-union. Radiological result was excellent in 33(58.89%), good in 12 (20.68%), fair in 8(13.79%) and poor in 5(8.62%) patients. Clinical result was excellent in 33(56.89%), good in 18(31.05%), fair in 4(6.89%) and poor in 3 (5.17%) patients.¹⁷

In another study by Kumar, Out of 28 cases, complete union was achieved in 25 (89.28%) and eradication of infection in 91.66% cases. Three cases failed to unite and two were lost to follow-up. Besides 16 cases underwent lengthening. Out of 30 patients, 79% had excellent, 11% good and 10% poor bony result. Functional result was excellent in 40% cases, good in 50% and failure in 10% cases using ASAMI scoring system.¹⁸ The union was achieved at non-union site in almost all patients upto the end of the treatment. The patients were satisfied with the surgical procedure by performing their normal daily life activities which were not possible before operation.

The limitation of our study is its small sample size and the fact that it relates to only two health centres.

Conclusion

Ilizarov fixator gave good and excellent results in complex

non-union of long bones by eradicating the infection, filling the defect with bone transport, and correcting the deformity and LLD.

References

1. Spiegelberg B, Parratt T, Dheerendra SK, Khan WS, Jennings R, Marsh DR. Ilizarov principles of deformity correction. *Ann R Coll Surg Engl* 2010; 92: 101-5.
2. Gessmann J, Baecker H, Jettkant B, Muhr G, Seybold D. Direct and indirect loading of the Ilizarov external fixator: the effect on the interfragmentary movements and compressive loads. *Strategies Trauma Limb Reconstr* 2011; 6: 27-31.
3. Borzunov DY, Chevardin AV. Ilizarov non-free bone plasty for extensive tibial defects. *Int Orthop* 2013; 37: 709-14.
4. El-Mowafi H, El-Alfy B, Refai M. Functional outcome of salvage of residual and recurrent deformities of clubfoot with Ilizarov technique. *Foot Ankle Surg* 2009; 15: 3-6.
5. Makhdoom A, Qureshi PA, Jokhio MF, Siddiqui KA. Resistant clubfoot deformities managed by Ilizarov distraction histogenesis. *Indian J Orthop* 2012; 46: 326-32.
6. Lovisetti G, Sala F, Thabet AM, Catagni MA, Singh S. Osteocutaneous thermal necrosis of the leg salvaged by TSF/Ilizarov reconstruction. Report of 7 patients. *Int Orthop* 2011; 35: 121-26.
7. El-Sayed MM, Correll J, Pohlig K. Limb sparing reconstructive surgery and Ilizarov lengthening in fibular hemimelia of Achterman-Kalamchi type II patients. *J Pediatr Orthop B* 2010; 19: 55-60.
8. Hollenbeck ST, Woo S, Ong S, Fitch RD, Erdmann D, Levin LS. The combined use of the Ilizarov method and microsurgical techniques for limb salvage. *Ann Plast Surg* 2009; 62: 486-91.
9. Ilizarov S. The Ilizarov method: history and scope. In: Rozbruch SR, Ilizarov S, eds. *Limb Lengthening and Reconstruction Surgery*. Boca Raton, FL: CRC Press; 2006; pp 15-16.
10. Burnei G, Vlad C, Gavrilu S, Georgescu I, Hodoroagea D, Pârvan A, et al. Upper and lower limb length equalization: diagnosis, limb lengthening and curtailment, epiphysiodesis. *Rom J Intern Med* 2012; 50: 43-59.
11. Edwards CC, Simmons SC, Browner BD, Weigel MC. Severe open tibial fractures. Results treating 202 injuries with external fixation. *Clin Orthop Relat Res* 1988; 230: 98-115.
12. Tucker HL, Kendra JC, Kinnebrew TE. Tibial defects. Reconstruction using the method of Ilizarov as an alternative. *Orthop Clin North Am* 1990; 21: 629-37.
13. Maini L, Chadha M, Vishwanath J, Kapoor S, Mehtani A, Dhaon BK. The Ilizarov method in infected nonunion of fractures. *Injury* 2000; 31: 509-17.
14. Dendrinis GK, Kontos S, Lyritis E. Use of the Ilizarov technique for treatment of non-union of the tibia associated with infection. *J Bone Joint Surg Am* 1995; 77: 835-46.
15. McKee M, Yoo D, Schemitsch EH. Health status after Ilizarov reconstruction of post traumatic lower-limb deformity. *J Bone Joint Surg Br* 1998; 80: 360-4.
16. Paley D, Catagni MA, Argnani F, Villa A, Benedetti GB, Cattaneo R. Ilizarov treatment of tibial nonunions with bone loss. *Clin Orthop Relat Res* 1989; 241: 146-65.
17. Farmanullah, Khan MS, Awais SM. Evaluation of management of tibia nonunion defect with Ilizarov fixator. *J Ayub Med Coll Abbottabad* 2007; 19: 34-6.
18. Seenappa HK, Shukla MK, Narasimhaiah M. Management of complex long bone nonunions using limb reconstruction system. *Indian J Orthop* 2013; 47: 602-7.