

Experience with Haemorrhoidal artery ligation under direct vision at a tertiary care hospital: A case series

Syed Mukarram Hussain,¹ Mansoor Tariq Azim,² Muhammad Mudassir Saleem,³ Muhammad Tanveer Sajid,⁴ Muhammad Awais Mughal,⁵ Asrar Ahmed⁶

Abstract

This study aims to share the results of haemorrhoidal artery ligation under direct vision in the management of symptomatic haemorrhoids. We conducted a case series of 70 patients at Combined Military Hospital Rawalpindi & Quetta, from January 2015 to October 2017. All patients underwent Haemorrhoidal Artery Ligation (HAL) and Recto Anal Repair (RAR). Ligation of superior haemorrhoidal artery was done under direct vision following manual palpation. Patients were followed up postoperatively at 1, 3 and 6 months. At 1 month follow up, all 70 (100%) patients were pain free. Post operative bleeding was observed in 7 (10%) patients but did not require surgical intervention. Sixty two (89%) patients were able to return to their daily activities 1 week after surgery and 57 (81%) resumed military duties or joined their work place at 2 weeks. 70 (100%) patients were asymptomatic and 45 (64%) highly satisfied with their surgery at 3 months. This increased to 53 (75%) at 6 months. 48 (69%) said that they would recommend this procedure to someone else. Prolapse recurrence was observed in 1(1.42%) patient 6 months post operatively which was dealt by band ligation. All patients completed follow-up at 1, 3 and 6 months. HAL is a simple yet safe technique with few complications, acceptable patient satisfaction and early return to work.

Keywords: Haemorrhoidal artery ligation, Mucopexy, Recto anal repair, Ligation under vision.

DOI: <https://doi.org/10.5455/JPMA.300504>

Introduction

Haemorrhoidal disease (HD) is estimated to affect 4.4-36.4% of general population.¹ It is the most common

diagnosis among patients presenting with bleeding from anus accounting for around 22.3 % of cases.² Over the years, a number of treatment modalities have emerged including Milligan-Morgan Haemorrhoidectomy (MMH), closed Haemorrhoidectomy, stapled haemorrhoidopexy and transanal haemorrhoidal artery ligation (HAL); which may be doppler guided or ligation under vision (LUV). Despite considerable research in this area, the ideal treatment for HD is debatable³ as standard excisional haemorrhoidectomy (SH), for advanced haemorrhoidal disease, has several limitations like post operative pain and recurrence.⁴ This calls for exploring newer treatment options like HAL as was done in this case series.

HAL is a minimally invasive technique that is being applied successfully for grade II and III haemorrhoids. The aim of this technique is to preserve haemorrhoidal plexuses and overlying mucosa.⁵ It potentially offers an intermediate surgical solution between outpatient procedures, such as injection sclerotherapy or rubber band ligation, and more invasive surgical procedures, such as conventional haemorrhoidectomy.⁶

Earlier studies did not find HAL much successful in treatment of grade IV haemorrhoids but with availability of improved anosscopes and better surgical techniques, satisfactory the results are being reported for grade IV disease as well.⁷ The present case series describes our experience of treating late 2nd degree, 3rd and 4th degree HD with HAL and mucopexy. This study aims to present results of functional evaluation and safety assessment of HAL/RAR in the treatment of late 2nd degree, 3rd and 4th degree HD.

Methodology

This was a case series. After departmental approval and informed consent from each patient, a total of 70 patients were enrolled from January 2015 to October 2017. Patients with symptomatic haemorrhoidal disease with or without prolapsing haemorrhoids without any previous history of procedure for haemorrhoidal disease were included. Those with thrombosed haemorrhoids on external examination, presence of anal fissure, actively bleeding haemorrhoids or faecal incontinence (any

.....
¹Department of General & Laparoscopic Surgery, Combined Military Hospital, Rawalpindi, ²Department of General Surgery, Combined Military Hospital, Kohat, ³Department of Pediatric Surgery, Military Hospital, Rawalpindi, ^{4,5}Department of General Surgery, Combined Military Hospital, Quetta, ⁶Department of General Surgery, Combined Military Hospital, Nowshera, Pakistan.

Correspondence: Mansoor Tariq Azim. Email: mansurtariq@gmail.com

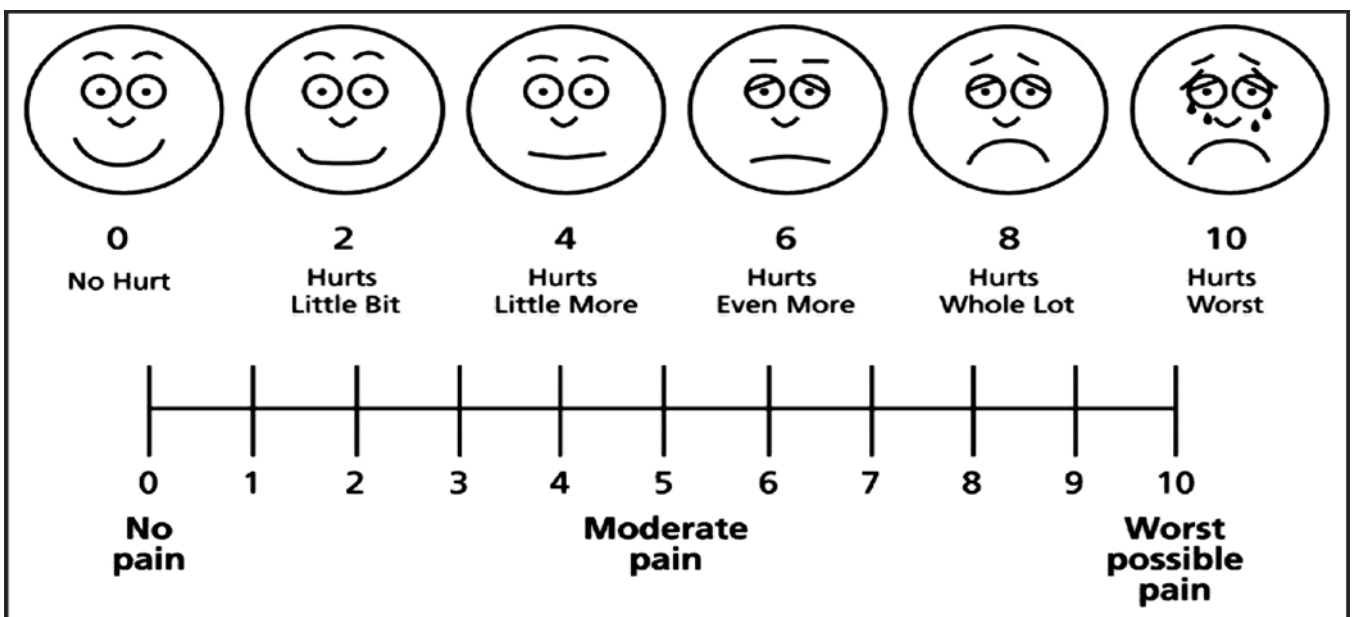
| 1. PATIENT DETAIL | |
|--|--------------------------|
| Name: _____ | Case No. _____ |
| Age: _____ | Hospital A & D No. _____ |
| Sex: Male <input type="checkbox"/> Female <input type="checkbox"/> | Hemorrhoid Grade _____ |
| Date of Admission: _____ | ASA Status _____ |
| 2. DATA | |
| Operative Time (Minutes) | |
| Per Op Bleeding (No of Gauze used) | |
| Post Op Bleeding (No of events) | |
| Post Op Pain (VAS) | |
| Hospital Stay (No of Days) | |
| Follow up at 1 month | |
| Follow up at 3 months | |
| Follow up at 6 months | |

grade) were excluded from study. Anorectal region was examined by digital examination and proctoscope to stage the disease as per Goligher's classification.⁸ Patients were admitted a night before the surgery and given rectal enema 12 hours prior to surgery. Per operative bleeding was assessed by the number of surgical gauze pieces used and recorded on a proforma (Annex - A). Post-Operative pain was assessed at 12 hours using Visual Analog Scale (VAS) (Annex - B). Post-operative follow up was done at 1, 3 and 6 months. A modified Surgical Satisfaction Questionnaire (SSQ - 8) was used to assess the post-operative satisfaction of patients⁹ (Annex - C).

Surgical Technique

All patients were operated by the same surgeon under spinal/caudal anaesthesia in Lithotomy position using a special proctoscope which

Annex-A: Hemorrhoidal artery ligation and recto anal repair.



Annex-B: Visual pain analog chart.

Annex-C: Surgical satisfaction questionnaire.**(SSQ - 8)**

Instructions: Following are a list of questions about your satisfaction with your surgery. All information is strictly confidential. Your confidential answers will be used only to help us understand and improve our patient care. Please check the circle that best answers the question for you. Thank you for your help.

1. How satisfied are you with your pain control in hospital after surgery?

Very Satisfied Satisfied Neutral Unsatisfied Very unsatisfied

2. How satisfied are you with your pain control at home after discharge from hospital?

Very Satisfied Satisfied Neutral Unsatisfied Very unsatisfied

3. How satisfied are you with the time it took for you to return to your daily activities e.g house work, social activities outside home, job?

Very Satisfied Satisfied Neutral Unsatisfied Very unsatisfied

4. How satisfied are you with the results of your surgery?

Very Satisfied Satisfied Neutral Unsatisfied Very unsatisfied

5. Would you recommend this surgery to someone else?

Very Satisfied Satisfied Neutral Unsatisfied Very unsatisfied

Haff RE, Stoltzfus J, Lucente VR, Murphy M. The Surgical Satisfaction Questionnaire (SSQ-8): A validated tool for assessment of patient satisfaction following surgery to correct prolapse and/or incontinence. *Journal of Minimally Invasive Gynecology*. 2011 Nov;18(6): 49-50.

allows easy palpation of vessels and suturing via side slit (Figure-1). After insertion, the proctoscope was moved over to 3 o'clock position. Haemorrhoidal artery was manually palpated and transfixated with 3/0 absorbable suture (polyglycan) mounted on a 26mm needle in a 'figure-of-eight' form (Figure-2). The level of transfixation depended on the site of the strongest palpation but was always kept above the dentate line.

After ligation we placed a continuous suture along the prolapsed mucosa and using the same thread, pliated the prolapsed component. The suture, covering the whole mass of a prolapsed haemorrhoid was tied with the long proximal end of the same thread lifting the haemorrhoid back into its anatomical position to achieve optimal plication of the prolapsed mucosal component. The distal end of the placating suture was 5mm proximal to dentate line (Mucopexy). Same procedure was repeated at 7 and 11 o'clock positions with clockwise rotation of the proctoscope through 360°. Anal pack was placed and removed 6 hours after surgery. Patients were kept in post-operative ward for 24 hours. Pain was controlled by Acetaminophen 2 - 3gm per day along with antibiotic prophylaxis with Cefuroxime 500mg per day for 3 days.

Results

A total 70 patients completed the study. Median age was 43.2 [Interquartile Range (IQR) = 9.75] years whereas mean age was 43.2 (SD ±10.1) years. Apart from prolapsing or permanently prolapsed haemorrhoids (100%), chief complaints on admission were bleeding (92.5%) and painful defecation (70%). Forty (57%) patients had grade 3 haemorrhoids; 22(31.4%) patients had grade

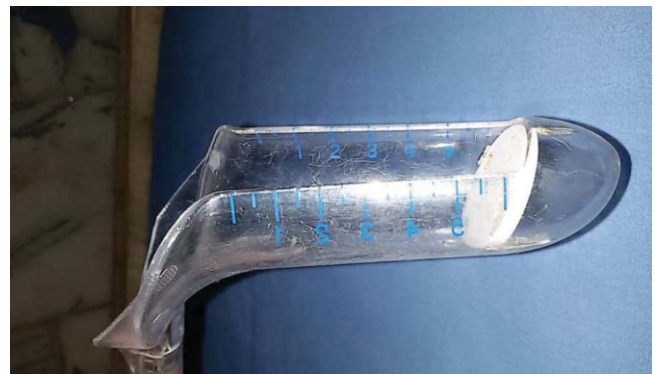

Figure-1: Proctoscope with side longitudinal slit.

4 whereas 8(11%) patients had grade 2 haemorrhoids. One patient (1.42%) had per operative sub-mucosal bleed during ligation of haemorrhoidal artery which was controlled by placing another trans fixating suture proximal to the first one. Median time of surgery was 19 minutes (IQR = 19) whereas mean time was 20±3.5 minutes. Twelve hours after surgery, 68(97%) had mild pain whereas 2(2.9%) had moderate pain. None of the patients complained of severe pain. Post-operative bleeding occurred in 7(10%) patients which was mild and occurred along with passage of stool. It did not require any surgical intervention and settled on its own.

Forty five (64%) patients were discharged the next day with an overall median hospital stay of 1.4 days (IQR = 1), whereas mean hospital stay was 1±0.2 day. Sixty two (89%) patients were able to return to their daily activities one week after surgery and 57 (81%) resumed military duties at 2 weeks. This was a major functional improvement (>50%) in our military setup. At one month

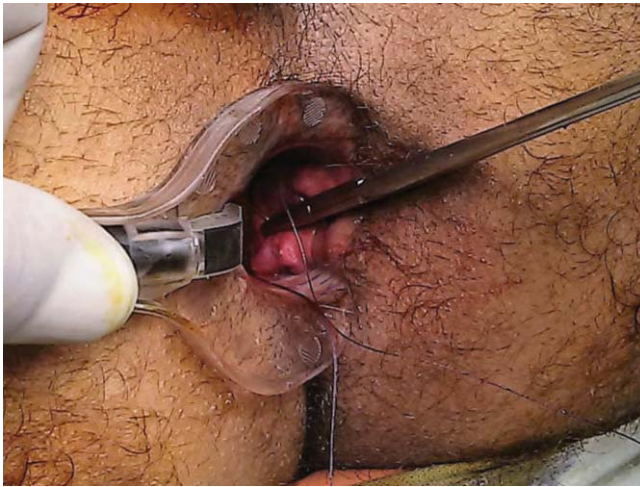
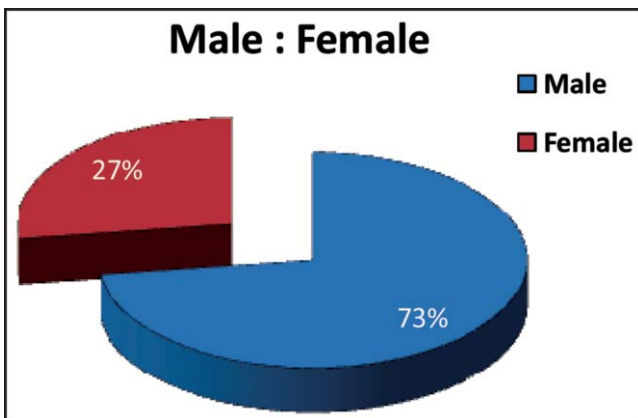


Figure-2: Placement of trans fixating suture.



Graph-I: Graphical display of male & female patients.

follow up, patients were asked to chart their pain using VAS and which showed that 100% patients were pain free and highly satisfied with the results of procedure. Mean satisfaction score was 22.2 ± 2.11 out of 25 (SSQ - 8). 70 (100%) patients were asymptomatic and 45 (64%) highly satisfied with their surgery at 3 months. This increased to 53 (75%) at 6 months. 48 (69%) said that they would recommend this procedure to someone else. Prolapse recurrence was observed in 1(1.42%) patient 6 months post operatively which was dealt by band ligation.

Discussion

Haemorrhoidal artery dearterialization was first described as a treatment for internal haemorrhoids in 1995 by Morinaga and has been popularized over the last decade with the development of specialized anosopes, which facilitate this procedure. However, there is still controversy and skepticism surrounding this procedure as an alternative to haemorrhoidectomy or stapled

haemorrhoidopexy.⁴ LUV is supported in literature to be effective and safe with earlier mobilization even in 2nd Degree HD.¹⁰ This manuscript concerns our experience with HAL/RAR which is reported to be as effective as SH in treating HD.⁷ Our early postoperative pain results were comparable with international data which showed much less pain in HAL in first 1 week.⁴ Our local literature is supportive in saying that HAL with mucopexy is a safe and effective treatment for HD with early return to work.¹¹ HAL can be done with Doppler Guided Anoscope or under direct vision. We did not use doppler assistance since arterial ligation can be performed under vision with comparable outcomes without using any specialized instruments.¹² It is also considered a safe and effective treatment option for grade IV HD as was the case in our study.¹² LUV is further supported by Demir H. et al¹² in where they found that routine ligation of all arteries in the rectal column may be unnecessary and ligation of only the visible haemorrhoidal cushions seems to be feasible. This case series showed very promising results, in terms of patient satisfaction, pain management and early return to work. In our setup, haemorrhoidectomy is not done as a day care procedure. In fact they are admitted a night before surgery, undergo surgery the next morning and discharged 24 to 36 hours after surgery once there is adequate pain control. On the other hand, HAL technique allowed us to discharge our patients much earlier because of earlier pain relief. Although the observation period of 6 months is too short to conclude the long-term effectiveness of the procedure.

Conclusion

Our study shows that haemorrhoidal artery ligation with suture mucopexy is a safe and effective procedure for haemorrhoidal disease and is associated with good patient satisfaction.

Limitations

This study maintained post op follow up till 6 months. More prolonged follow up and a larger study group is suggested for generalization of the results.

Disclaimer: The article has not been presented or published in a conference or published in an abstract book.

Conflict of Interest: The authors declare no conflicting interests.

Funding Disclosure: None to declare.

References

1. Zhai M, Zhang YA, Wang ZY, Sun JH, Wen J, Zhang Q, et al. A Randomized Controlled Trial Comparing Suture-Fixation Mucopexy and Doppler-Guided Hemorrhoidal Artery Ligation in Patients with Grade III Haemorrhoids. *Gastroenterol Res Pract*.

- 2016; 2016:8143703.
2. Jehangiri AU, Gul R, Hadayat R, Khan AN, Zabiullah, Khursheed L. Causes Of Lower Gastrointestinal Bleeding On Colonoscopy. *J Ayub Med Coll Abbottabad*. 2017; 29:468-71.
 3. Kara C, Sozutek A, Yaman I, Yurekli S, Karabuga T. Ligation under vision in the management of symptomatic haemorrhoids: A preliminary experience. *Asian J Surg*. 2015; 38:121-5.
 4. Denoya P, Tam J, Bergamaschi R. Haemorrhoidal dearterialization with mucopexy versus haemorrhoidectomy: 3-year follow-up assessment of a randomized controlled trial. *Tech Coloproctol*. 2014; 18:1081-5.
 5. Walega P, Romaniszyn M, Kenig J, Herman R, Nowak W. Doppler-guided haemorrhoid artery ligation with Recto-Anal-Repair modification: functional evaluation and safety assessment of a new minimally invasive method of treatment of advanced hemorrhoidal diseases. *Sci World J*. 2012; 2012:324040.
 6. Conaghan P, Farouk R. Doppler-Guided Hemorrhoid Artery Ligation Reduces the Need for Conventional Haemorrhoid Surgery in Patients who Fail Rubber Band Ligation Treatment. *Dis Colon Rectum*. 2009; 52:127-30.
 7. Faucheron JL, Poncet G, Voirin D, Badic B, Gangner Y. Doppler guided haemorrhoidal artery ligation and recto anal repair (HAL-RAR) for the treatment of grade IV haemorrhoids: long-term results in 100 consecutive patients. *Dis Colon Rectum*. 2011; 54:226-31.
 8. Goligher JC. *Surgery of the anus, rectum and colon*. 5th ed. London: Billiere Tindall, 1984; pp 101.
 9. Haff RE, Stoltzfus J, Lucente VR, Murphy M. The Surgical Satisfaction Questionnaire (SSQ-8): A validated tool for assessment of patient satisfaction following surgery to correct prolapse and/or incontinence. *J Minim Invasive Gynecol*. 2011; 18:49-50.
 10. Elshazly WG, Gazal AE, Madbouly K, Hussen A. Ligation anopexy versus haemorrhoidectomy in the treatment of second- and third-degree haemorrhoids. *Tech Coloproctol*. 2015; 19:29-34.
 11. Khawer R, Muhammad AJ, Khalid M, Asma K. A Randomized Trial To Compare Pile Suturing With Hemorrhoidectomy For Treatment Of Third And Fourth Degree Haemorrhoids. *PAFMJ*. 2010; 60:186-9.
 12. Demir H, Karaman K, Ercan M, Kocer HB, Celebi F. Comparison of two procedures for symptomatic haemorrhoidal disease: Ligation under Vision and Ferguson Haemorrhoidectomy - A retrospective cohort study. *Pak J Med Sci*. 2017; 33:90-5.
-