

Primary carcinoid tumour of the testis

Shahid A.A.Khan¹, George John¹, Simon D. Howell²

Departments of Urology¹ and Pathology², Royal Sussex County Hospital, Brighton, United Kingdom.

Abstract

A left radical orchidectomy was performed on a 32-year-old man presenting with a testicular mass. Histology revealed a tumour comprising of cells with monotonous nuclei and granular cytoplasm arranged in an insular pattern. Immunohistochemical expression for NSE, synaptophysin and chromogranin A were positive. No teratomatous elements were seen. Postoperatively, a staging CT and an octreotide scan were normal. Urinary 5-HIAA levels were not elevated. Based on these investigations the tumour was diagnosed as a pure primary carcinoid tumour of the testis. The patient has been followed up for 3 years with no evidence of recurrence.

Introduction

Primary testicular carcinoid tumours are rare neoplasms thought to originate from either dispersed neuroendocrine elements within the testis or from an aberrant development of a simplified teratoma.¹ We report a case of a 32 year-old man presenting with a palpable testicular mass that was found to be a primary testicular carcinoid tumour.

Case Report

A 32-year-old man presented with a painless left testicular mass of 2 months duration. Scrotal examination revealed a firm non-tender, smooth, ovoid mass approximately 10 cm in diameter. Ultrasonography demonstrated a heterogeneous echo pattern suggestive of malignancy. A left radical inguinal orchidectomy was performed.

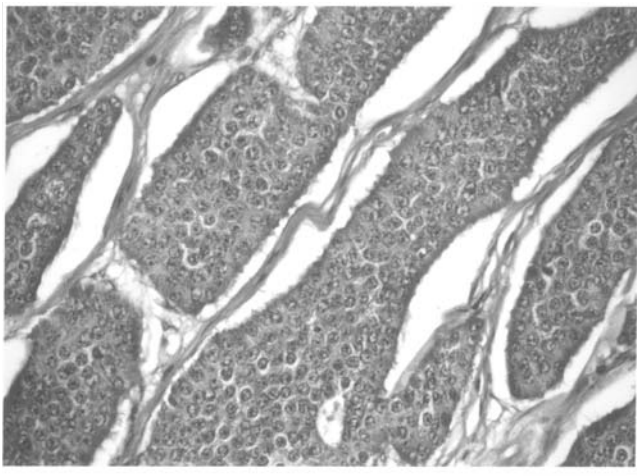


Figure 1.

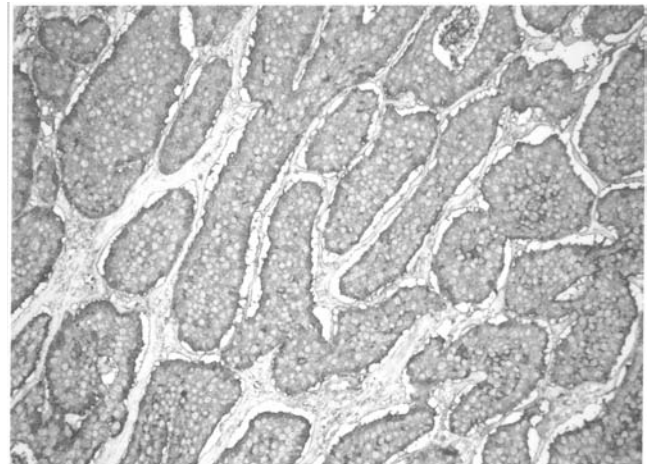


Figure 2.

Histology showed a tumour composed of nests and cords of cells with monotonous nuclei and faintly eosinophilic granular cytoplasm, lying in a vascular stroma (Figure 1). Immunohistochemical expression for neuron specific enolase, synaptophysin, chromogranin A, MNF116 and CAM 5.2 were positive, consistent with an epithelial tumour of neuro-endocrine origin (Figure 2). No teratomatous elements were seen.

Postoperatively, CT of the chest, abdomen and pelvis was normal. Clinically there was no sign of carcinoid syndrome. Urinary 5 hydroxyindoleacetic acid levels were not elevated. Investigations including an octreotide scan to find a primary site were negative. The tumour was therefore diagnosed as a primary carcinoid tumour of the testis. A follow-up of 3 years has been carried out so far and there is no evidence of metastasis but review has to take place for another 7 years.

Comments

Carcinoid tumour of the testis is exceedingly rare, comprising 0.23% of all testicular tumours. The reported age at presentation ranges from 10 to 83 years, with a peak incidence between the 5th and 7th decade.² It rarely manifests symptoms of carcinoid syndrome and patients commonly present with a painless testicular mass or enlargement, however associations with hydrocele and cryptorchidism have been reported.³

Carcinoid tumours found in the testis are divided into 3 sub-groups: pure primary testicular carcinoid, primary testicular carcinoid associated with a teratoma (mixed carcinoid) and carcinoid metastases to the testis. Pure primary testicular carcinoid accounts for more than 75% of the reported cases.^{1,3}

Immunohistochemistry techniques cannot distinguish between a pure primary carcinoid and a carcinoid metastasis; therefore a distant primary must be excluded. CT is used to identify primary gastrointestinal and endobronchial tumours, as gastrointestinal carcinoids are usually greater than 2 cm before they metastasise.⁴

Octreotide scintigraphy is a useful modality for tumour localization with sensitivity of around 80%, which when combined with SPECT is the most reliable staging procedure. Octreotide scintigraphy also facilitates the selection of patients with carcinoids that are likely to respond favourably to somatostatin analogue treatment.⁵

Primary testicular carcinoid has a good prognosis with an indolent clinical course. Retroperitoneal lymph node dissection is not considered necessary with radical orchidectomy being the main treatment. Testicular carcinoids greater than 7 cm may metastasise, although rarely, many years after excision, hence long term follow-up is

considered necessary.³

Recommendations for follow-up include careful physical examination and biochemical surveillance using urinary HIAA as a marker with imaging for localization included when considered clinically appropriate.

References

1. Terhune DW, Manson AL, Jordon GH, Peterson N, Auman JR, MacDonald GR. Pure primary testicular carcinoid: a case report and discussion. *J Urol* 1988;139:132-3.
2. Kim HJ, Cho MY, Park YN, Kie JH. Primary carcinoid tumour of the testis: immunohistochemical, ultrastructural and DNA flow cytometric study of two cases. *J Korean Med Sci* 1999;14:57-62.
3. Zavala-Pompa A, Ro JY, el-Naggar A, Ordonez NG, Amin MB, Pierce PD, et al. Primary carcinoid tumour of testis. Immunohistochemical, ultrastructural, and DNA flow cytometric study of three cases with a review of the literature. *Cancer* 1993;72:1726-32.
4. Glazier DB, Murphy DP, Barnard N, Cummings KB, Weiss RE. Primary carcinoid tumour of the testis. *BJU Int* 1999;83:153-4.
5. Hoegerle S, Althoefer C, Ghanem N, Koehler G, Waller CF, Scheruebl H, et al. Whole-body 18F dopa PET for detection of gastrointestinal carcinoid tumours. *Radiology* 2001;220:373-80.