

Hyperdominant left anterior descending artery presenting as anterior wall ST segment elevation myocardial infarction: A rare coronary anomaly

Shahrukh Hashmani, Abid Hussain Laghari

Abstract

We report on a 75 year-old man who presented with severe chest pain for four hours. Physical examination was unremarkable and he was haemodynamically stable. ECG done in the ED showed ST segment elevations along with Q waves in the anterior and inferior leads with T wave inversions. He was rushed to the catheterization lab where the left anterior descending (LAD) artery was 99% occluded in the proximal segment while distal left circumflex showed 50-60% lesion. He underwent primary percutaneous coronary intervention to LAD with drug eluting stent and made an uneventful recovery. The LAD was found to be wrapping around the apex and continuing as the posterior descending artery (PDA).

To the best of our knowledge, there are few case reports on the continuation of LAD across the left ventricular apex as PDA in the presence of a normally arising but small right coronary artery.

Keywords: Case Report, Hyperdominant, Left anterior descending artery, ST segment elevation myocardial infarction, Percutaneous coronary intervention.

Introduction

This is a rare case of hyperdominant LAD presenting as anterior wall ST segment elevation myocardial infarction (AWMI). As the blood supply to the entire interventricular septum is derived from this "hyperdominant" LAD system, stenosis of LAD can be catastrophic.

An interventional cardiologist must be aware of such anomalies whenever performing a catheterization on patients who have suffered a large infarction involving both the anterior and inferior walls. Early revascularization is probably lifesaving for these patients, as was in our case.

Case Report

A 75 year old male, ex-smoker presented to the emergency department (ED) on 12th January, 2017 at the Aga Khan University Hospital; Karachi, with symptoms of

.....
Aga Khan University Hospital, Karachi.

Correspondence: Shahrukh Hashmani. Email: drshahrukhashmani@gmail.com

central chest pain for last four hours. Pain was central, radiated to neck, jaws, left shoulder and was 6/10 in intensity. It was associated with diaphoresis and nausea. He did not have any other risk factors for coronary artery disease. He was immediately rushed to the near-by hospital where an initial ECG was recorded (Figure-1) that showed ST segment elevations in anterior and inferior leads along with Q waves and T wave inversions, so was referred to our hospital for further management after receiving the acute coronary syndrome (ACS) protocol, which included 300 mg of aspirin, 600 mg of clopidogrel and 5000 IU of intravenous unfractionated heparin.

On examination, he was haemodynamically stable with clear chest and normal precordial examination. He was given 2mg intravenous morphine for pain control and was immediately rushed to cath lab. Baseline haematological and biochemical results were within normal range.

Left heart catheterization was performed through right femoral artery approach using Judkins left catheter 6 French. It showed a normal, left main system bifurcating into Left anterior descending (LAD) and Left circumflex arteries (LCX) respectively. The LAD was large and it showed 99% stenosis in proximal segment with thrombolysis in myocardial infarction (TIMI) II flow. LAD was a large vessel curving around the apex of the left ventricle and continuing as the PDA, and supplying most of the inferior septum. The LCX showed 60% stenosis in distal segment. The Right coronary artery (RCA) was engaged with Judkins Right catheter 6 French that

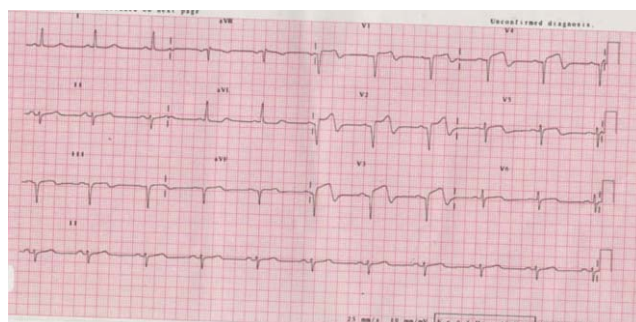


Figure-1: 12 Lead Electrocardiogram (ECG) showing Q waves in leads V1-V4, leads III and aVF along with ST segment elevations and T wave inversions.

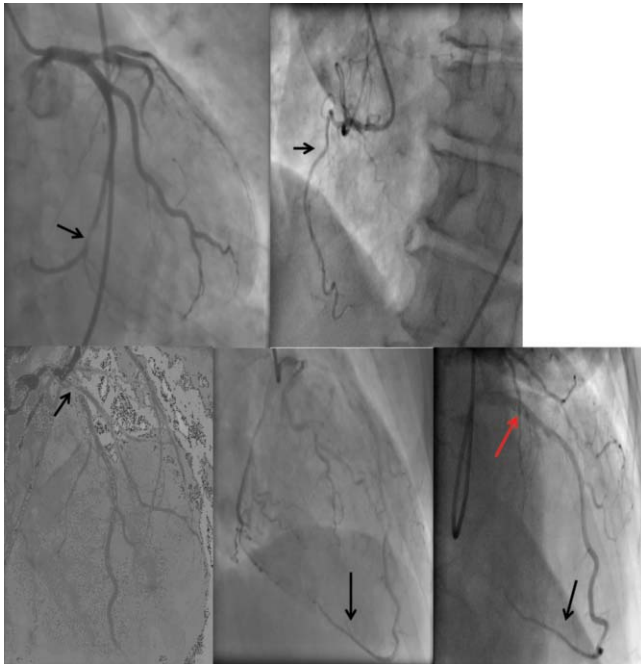


Figure-2: A: Coronary angiogram in Right anterior oblique (RAO) caudal view, black arrow shows distal left circumflex artery (LCX) shows 50 -60% discrete stenosis. B: Left anterior oblique (LAO) view, black arrow shows non dominant right coronary artery (RCA). C: (AP) cranial view, black arrow shows proximal LAD with critical 99% stenosis. D: Right anterior oblique (RAO) cranial view, black arrow shows continuation of LAD beyond the apex as "Hyperdominant LAD". E: Post PCI. Red arrow shows stent in proximal LAD, black arrow shows hyperdominant LAD system.

demonstrated a small, non-dominant but normally arising right coronary artery (Figure-2a-2e).

Two dimensional transthoracic echocardiogram was performed once the patient was stabilized and that showed an ejection fraction of approximately 30%. Apex, basal to mid septum, mid anterior wall and mid inferior wall were akinetic. Rest of the segments were contracting normally.

After the completion of coronary angiogram, the left main stem was engaged with extra back-up (Voda Left® Boston Scientific, USA) 3.5 French guiding catheter. LAD and first Diagonal (D1) branch were wired with Balance Middle Weight (Abbott Vascular, USA) 0.014 x 190 cm guide wires. The proximal LAD lesion was predilated with semi-compliant balloon Sapphire II (OrbusNeich, Hong Kong) 2.5 x 15 mm at 12 atmosphere. The lesion was hard, so it was further dilated with non-compliant balloon Sapphire™ NC (OrbusNeich, Hong Kong) 3.0 x 10 mm at 10 atmosphere. Drug eluting stent XienceXpedition (Abbott Vascular, USA) 3.5 x 23mm was deployed in proximal LAD at 10 atmosphere. The stent was post dilated with NC Treck (Abbott Vascular, USA) 3.75x12 mm at 16 - 18

atmosphere. Mild no reflow was observed which got better with intracoronary administration of adenosine and nitroprusside. Final kissing ballooning of LAD and D1 was done with NC Treck (Abbott Vascular, USA) 3.75x12mm and Sapphire II (OrbusNeich, Hong Kong) 2.0 x 10 mm respectively.

Post procedure selective coronary angiogram of left coronary artery showed TIMI-III flow in the LAD which continued across the left ventricular apex as PDA, running along the posterior interventricular septum (Figure-6).

Post procedure, the patient was stable and was discharged after three days of hospital stay. He was discharged on aspirin (150 mg /day), clopidogrel (75 mg/day), perindopril (2mg/day), carvedilol 6.25mg twice daily, spironolactone 25mg/day, furosemide 40mg/day and atorvastatin (40mg/day). At one month follow up visit, he was asymptomatic and clinically stable.

Discussion

Anomalous coronaries are usually discovered incidentally and have an estimated incidence of 0.2-1.2% in the general population.¹ Depending upon the origin, course, and termination of the anomalous vessel, these abnormalities may be responsible for angina pectoris, heart failure and sudden death.²

Normally the posteroinferior part of the interventricular septum is supplied by the posterior descending artery (PDA) whose variable origin is reflected by the concept of coronary dominance. The posterior descending artery can arise from right coronary artery (RCA) in a pattern of right dominance (85% of patients) and co-dominance (7% of patients) or from the left circumflex artery (LCX) in a pattern of left dominance (8% of patients),³ therefore on ECG it may manifest as ST segment elevations in both the anterior and inferior leads.

We present a rare type of left dominant circulation in which a large LAD continues as PDA after winding round the apex in the presence of a diminutive RCA. Such a large LAD continuing as PDA is referred as "hyperdominant"⁴ or "superdominant".⁵ Some authors describe such a LAD as "wrap around LAD" though "wrapped LAD" is defined as a LAD supplying at least one-fourth part of inferior surface of left ventricle and the interventricular septum.⁶ Occurrence of acute inferior wall myocardial ischaemia due to occlusion of LAD continuing as PDA has also been reported in the literature.⁶ If the patient has a wrapped LAD and the location of the occlusion is proximal to D1, ST segment is elevated in anterior leads and remains isoelectric in the inferior leads, as was in our case.⁷

Continuation of the LAD to form the posterior descending artery is a rare coronary anomaly.⁸ Clark et al.⁹ identified a patient in whom LAD formed the PDA and terminated just before the crux. Similarly, Musselman and Tate reported a case in which the PDA originated from the LAD and continued beyond the crux. Later, the PDA divided in to two branches that went through both the left and right sides of atrioventricular groove.¹⁰

The stenosis of hyperdominant LAD can have catastrophic complications. Kaul, described repeated successful surgical rescues of early and delayed ruptures of ventricular septum, right ventricle and aneurysmal left ventricle following massive biventricular infarction subsequent to the occlusion of a hyperdominant LAD, albeit in the presence of a normally arising but modestly distributed RCA.¹¹

Learning Points

- ◆ Anomalous coronaries are usually discovered incidentally and have an estimated incidence of 0.2-1.2% of routine angiographic studies.
- ◆ Very rarely, the PDA may arise as a continuation of "hyperdominant" LAD.
- ◆ In the presence of a "hyperdominant" LAD continuing as PDA, the entire interventricular septum is perfused by the LAD and its occlusion can lead to catastrophic consequences.
- ◆ Physicians, interventional cardiologists and cardiac surgeons should be aware of such a rare anomaly as it can have considerable impact on the clinical outcome of a patient and can jeopardize a large segment of the myocardium.
- ◆ Patient having typical cardiac chest pain and ECG showing ST segment elevations in anterior leads but isoelectric ST segment in inferior leads may represent ischaemia extending to entire inferior territory.

Disclaimer: None to declare.

Conflict of Interest: None to declare.

Funding Source: None to declare.

References

1. Cingoz F, Bingol H, Turan Yilmaz A, Tatar H. Left anterior descending artery arising as a terminal extension of posterior descending artery (a rare coronary artery anomaly). *Interact CardiovascThorac Surg.* 2003; 2: 680-1.
2. Dubey L. Anomalous origin of the coronary arteries: an account of six cases. *J Nepal Med Assoc.* 2013;52:512-6.
3. Kim JH, Cha KS, Park SY, Park TH, Kim MH, Kim YD. Anomalous origins of the right and posterior descending coronary arteries from the left anterior descending coronary artery: unusual pattern of single coronary artery. *J Cardiol cases.* 2011; 3: e26 -28.
4. Javangula K, Kaul P. Hyperdominant left anterior descending artery continuing across left ventricular apex as posterior descending artery coexistent with aortic stenosis. *J Cardiothorac Surg.* 2007; 2: 42.
5. Deora S, Shah S, Patel T. Superdominant left anterior descending artery continuing as posterior "ascending" and posterior left ventricular branch: a rare coronary anomaly. *Int J Cardiol.* 2013; 168:e121-2.
6. Sunil Roy TN, Nagham JS, Anil Kumar R. Acute inferior wall myocardial infarction due to occlusion of the wrapped left anterior descending coronary artery. *Case Rep Cardiol.* 2013; 2013:983943.
7. Andreou AY, Georgiou GM. "Simultaneous anterior and inferior myocardial infarction due to occlusion of the left anterior descending coronary artery," *Turk Kardiyol Dern Ars.* 2009; 37:285-7.
8. Singh SP, Soto B, Nath H."Anomalous origin of posterior descending artery from left anterior descending artery with unusual intraseptal course," *J Thorac Imaging.* 1994; 9:255-7.
9. Clark VL, Brymer JF, Lakier JB. "Posterior descending artery origin from the left anterior descending: an unusual coronary artery variant," *Cathet Cardiovasc Diagn.* 1985; 11:167-71.
10. Musselman DR, Tate DA. Left coronary dominance due to direct continuation of the left anterior descending to form the posterior descending artery. *Chest.* 1992; 102: 319-20.
11. Kaul P. Repeated successful surgical rescues of early and delayed multiple ruptures of ventricular septum, right ventricle and aneurysmal left ventricle following massive biventricular infarction. *J Cardiothorac Surg.* 2006;1:30.