

Perirenal haemorrhage after successful stent placement in a patient with atherosclerotic renal artery stenosis: A case report

Yu Ho Lee,¹ Jiyoung Oh,² Yang Gyun Kim,³ Sang-Ho Lee,⁴ Kyung-Hwan Jeong,⁵ Ju-Young Moon⁶

Abstract

Atherosclerotic renal artery stenosis is a potentially correctable cause of secondary hypertension. Most patients with renal artery stenosis are managed with medical therapy alone. However, percutaneous renal angioplasty could be more effective than conventional medical therapy in several specific conditions. Common complications following renal angioplasty include puncture site haematoma, branch vessel occlusion, and renal artery dissection. However, late perirenal haemorrhage following the procedure is rarely reported. We report a case of perirenal haemorrhage after successful percutaneous renal artery stent placement in a patient diagnosed with unilateral atherosclerotic renal artery stenosis.

Keywords: Renal artery stenosis, Percutaneous transluminal angioplasty, Perirenal haemorrhage.

Introduction

Atherosclerotic renal artery stenosis (ARAS) is an important but often underestimated cause of hypertension. ARAS is commonly found in the elderly; the estimated prevalence is 6.8% in people aged above 65.¹ Most patients diagnosed with ARAS are effectively managed with antihypertensive medication alone. However, in some cases, percutaneous renal angioplasty can be a better therapeutic option compared to medical therapy. Currently suggested indications for the procedure include a short duration of severe hypertension, refractory hypertension uncontrolled by medical therapy, recurrent flash pulmonary oedema with congestive heart failure, and progressively increasing levels of serum creatinine.²

Percutaneous renal artery stent placement is considered a safe procedure with the risk of complications being 5-15%.^{3,4} Common complications include groin haematoma at the puncture site, branch vessel occlusion, and renal artery dissection. However, delayed perirenal

haemorrhage following renal angioplasty is rarely reported. We report a case of perirenal haemorrhage after successful renal artery stent placement in a patient diagnosed with unilateral ARAS. The consent of the patient was taken prior to writing of the manuscript.

Case Report

A 50-year-old man was admitted in Kyung Hee University hospital at Gangdong on June 18th 2017, for assessment and management of intermittent headache of 2 months' duration, which was temporarily improved with administration of acetaminophen but recurred after discontinuation of the analgesic. He was 158cm tall and weighed 61kg. His previous medical check-up had been done a year prior to presentation, at which time his blood pressure was noted to be 118/72 mm Hg. He did not show symptoms such as dyspnoea, or chest pain. Physical examination revealed his blood pressure was 220/120 mmHg, heart rate was 72 beats/min, respiratory rate was 20 breaths/minute, and his body temperature was 36.5°C. There was no evidence of abnormal breath sounds, cardiac murmur, abdominal bruit, or pretibial pitting oedema. Routine laboratory tests showed the following results: white blood cell count 14,690/ μ L, haemoglobin 16.7 g/dL, platelets $220 \times 10^3/\mu$ L, blood urea nitrogen 13 mg/dL, serum creatinine 1.16 mg/dL, sodium 138mEq/L, potassium 3.8mEq/L, chloride 104mEq/L, bicarbonate 28.2mEq/L, and C-reactive protein 0.1mg/dL. Urinalysis

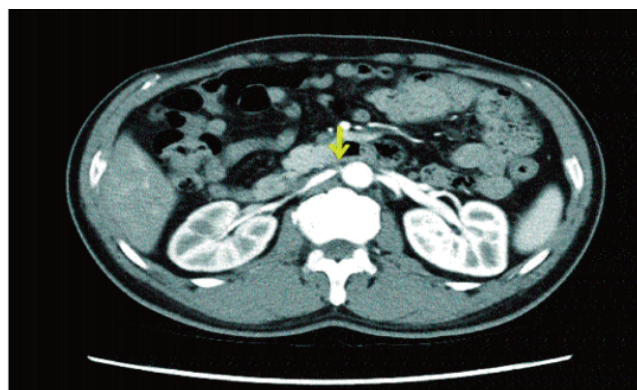


Figure-1: Computed tomography (CT) scan of the abdomen at the time of presentation. Severe atherosclerotic stenosis of the ostium of the right renal artery (Arrow) is observed.

^{1,3-6}Division of Nephrology, Department of Internal Medicine, ²Department of Radiology, Kyung Hee University, Korea.

Correspondence: Ju-Young Moon. Email: jymoon@khu.ac.kr

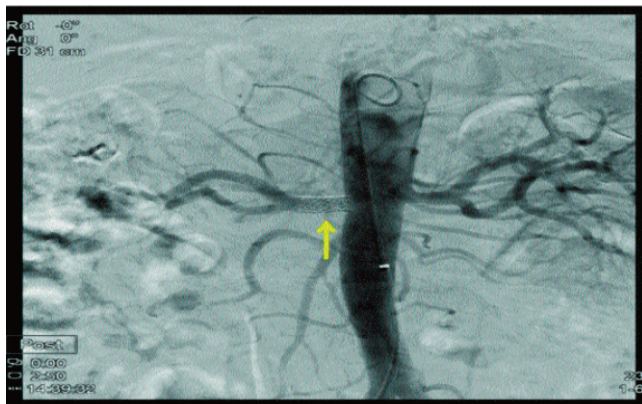


Figure-2: Percutaneous renal angiography and renal artery stent placement. Successful placement of a renal artery stent after balloon dilatation (Arrow).

was negative for haematuria and proteinuria. A chest x-ray showed no active lung lesion with intact cardiac size, and an electrocardiogram (EKG) was normal without evidence of left ventricular hypertrophy. Continuous infusion of nicardipine was initiated after admission, and his blood pressure gradually decreased to 160/90 mmHg on hospital day 1 and to 140/90 mmHg on hospital day 2. Computed tomography (CT) of the abdomen was performed to assess for secondary causes of hypertension. The CT scan revealed severe atherosclerotic stenosis of the ostium of his right renal artery (Figure-1). Right and left kidneys measured 10.2cm and 10.6 cm in length, respectively.

Percutaneous renal angiography was performed on hospital day 3 and showed >80% stenosis of his right renal artery, as was demonstrated by his CT findings. Successful placement of a renal artery stent was followed

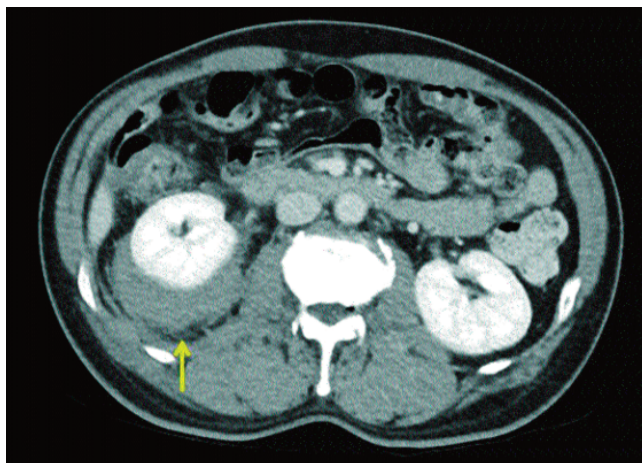


Figure-3: Follow-up computed tomography (CT) scan of the abdomen. Right-sided perirenal haemorrhage was detected (Arrow).

by improved renal blood flow to the affected kidney, which was confirmed by serial angiography (Figure-2). We also checked that there was no bleeding after the procedure. Aspirin therapy was initiated to prevent stent thrombosis. His blood pressure started to return to the normal range without use of antihypertensive medication.

However, a day later, he complained of sudden onset of right flank pain. A follow-up CT scan showed right-sided perirenal haemorrhage without any evidence of active bleeding during the arterial phase (Figure-3). His renal artery stent was intact without peri-arterial haemorrhage or stent thrombosis. Because the patient's vital signs were stable, despite bleeding, we opted for conservative management instead of performing embolization. Aspirin was withheld, and the patient remained stable with improving flank pain. He was discharged on hospital day 6 without use of antihypertensive medication, and his blood pressure has been stable for last 2 months of follow up.

Discussion

Atherosclerosis is a very common condition affecting the arteries, and renal artery is frequently associated with the development of atherosclerosis. Renovascular hypertension is the most common clinical manifestation caused by ARAS.¹ Rarely, spontaneous renal artery dissection is reported to occur due to dissection of atheromatous plaque around the renal artery.⁵

Several procedure-related complications could arise in association with a percutaneous renal angioplasty with stent placement. While most events are minor and do not cause serious medical problems, serious intra or postoperative complications including renal artery rupture, atheroembolic renal disease, and renal arterial embolization are known to occur. Perirenal haemorrhage is among the least frequently reported complications. Nonetheless, this entity should not be neglected because rapid and massive bleeding into the perirenal space can often lead to circulatory collapse and death.⁶

The exact mechanism of perirenal haemorrhage following renal angioplasty remains controversial. Bleeding could be caused by iatrogenic injury, as reported by several studies in which perirenal haemorrhage was found to be associated with guidewire-induced distal renal artery perforation.^{3,4,6} This usually happens due to excessive distal migration of the tip of the guidewire into the renal parenchyma to cause perforation of the distal renal artery through the renal capsule. In our patient, the guidewire was observed very carefully during the procedure to ensure that it did not migrate too distally, and we confirmed that there was no extravasation of the contrast

dye into the perirenal space after placement of the renal artery stent.

To date, most patients diagnosed with ARAS have been managed by either medical therapy alone or use of percutaneous renal angioplasty. Restoring renal blood flow to the affected kidney has been a theoretically attractive therapeutic option, considering that the central pathophysiology of ARAS involves decreased renal perfusion leading to activation of the renin-angiotensin-aldosterone system. Therefore, several randomized controlled trials have been performed to compare the efficacy and outcomes of percutaneous renal artery revascularization in patients diagnosed with ARAS.^{3,4,7,8} However, all those studies have failed to demonstrate benefits of revascularization compared to medical therapy alone. A possible reason for these disappointing results might be inappropriate selection of candidate patients for revascularization because most patients with long-standing ARAS did not benefit from the procedure. Interestingly, a few studies recruited patients diagnosed with unilateral ARAS who presented with severe clinical manifestations such as flash pulmonary oedema and refractory hypertension and compared the efficacy of medical therapy alone with that of renal angioplasty.^{9,10} Among those patients, the incidence of progressive renal insufficiency and cardiovascular events was significantly lower in patients who underwent renal angioplasty than in those who were treated with medical therapy alone. In this regard, current guidelines recommend that renal angioplasty be performed in specific clinical conditions, as described above.² The patient in our study was considered to have had a relatively rapid onset of hypertension without evidence of end-organ damage, and the limitation of blood flow to his affected kidney was clearly demonstrated using contrast-enhanced CT. We therefore concluded that percutaneous renal angioplasty would be effective to control severe hypertension in this patient and did find that hypertension improved dramatically after the procedure.

Conclusion

We report a case of late perirenal haemorrhage after successful percutaneous renal artery stent placement in a patient diagnosed with unilateral ARAS. Although we

could not explain the exact mechanism of perirenal haemorrhage after the procedure, it is noteworthy and important to understand that lack of evidence of bleeding following renal angiography does not exclude the possibility of perirenal haemorrhage. Clinicians should be aware of this complication for proper evaluation and management of patients.

Disclaimer: None.

Conflict of Interest: We declare no conflict of interest, and the work was not supported or funded.

Funding Sources: None to declare.

References

1. Textor SC, Lerman L. Renovascular hypertension and ischemic nephropathy. *Am J Hypertens* 2010; 23: 1159-69.
2. Anderson JL, Halperin JL, Albert NM, Bozkurt B, Brindis RG, Curtis LH, et al. Management of patients with peripheral artery disease (compilation of 2005 and 2011 ACCF/AHA guideline recommendations): a report of the American College of Cardiology Foundation/American Heart Association Task Force on Practice Guidelines. *Circulation* 2013; 127:1425-43.
3. Wheatley K, Ives N, Gray R, Kalra PA, Moss JG, Baigent C, et al. Revascularization versus medical therapy for renal-artery stenosis. *N Engl J Med* 2009; 361: 1953-62.
4. Cooper CJ, Murphy TP, Cutlip DE, Jamerson K, Henrich W, Reid DM, et al. Stenting and medical therapy for atherosclerotic renal-artery stenosis. *N Engl J Med* 2014; 370: 13-22.
5. Mansoor MS, Shafiq M. Spontaneous renal artery dissection: Current perspective. *J Pak Med Assoc* 2012; 62: 1333-7.
6. Axelrod DJ, Freeman H, Pukin L, Guller J, Mitty HA. Guide wire perforation leading to fatal perirenal haemorrhage from transcortical collaterals after renal artery stent placement. *J Vasc Interv Radiol* 2004; 15: 985-7.
7. van Jaarsveld BC, Krijnen P, Pieterman H, Derckx FH, Deinum J, Postma CT, et al. The effect of balloon angioplasty on hypertension in atherosclerotic renal-artery stenosis. Dutch Renal Artery Stenosis Intervention Cooperative Study Group. *N Engl J Med* 2000; 342: 1007-14.
8. Bax L, Woittiez AJ, Kouwenberg HJ, Mali WP, Buskens E, Beek FJ, et al. Stent placement in patients with atherosclerotic renal artery stenosis and impaired renal function: a randomized trial. *Ann Intern Med* 2009; 150:840-8.
9. Kalra PA, Chrysochou C, Green D, Cheung CM, Khavandi K, Sixt S, et al. The benefit of renal artery stenting in patients with atheromatous renovascular disease and advanced chronic kidney disease. *Catheter Cardiovasc Interv* 2010; 75: 1-10.
10. Ritchie J, Green D, Chrysochou C, Chalmers N, Foley RN, Kalra PA. High-risk clinical presentations in atherosclerotic renovascular disease: prognosis and response to renal artery revascularization. *Am J Kidney Dis* 2014; 63: 186-97.