

Clinical variability of CYP1B1 gene variants in Pakistani primary congenital glaucoma families

Rasheeda Bashir,¹ Khazeema Yousaf,² Hafsa Tahir,³ Marukh Sanai,⁴ Seema Qayyum,⁵ Shagufta Naz,⁶ Sadaf Naz⁷

Abstract

Objective: To explore the spectrum of Cytochrome P450 1B1 gene variants and genotype-phenotype correlations in families affected with primary congenital glaucoma.

Methods: The cross-sectional study was performed at the Department of Biotechnology, Lahore College for Women University, Lahore, and the School of Biological Sciences, University of the Punjab, Lahore, Pakistan, from February 2015 to October 2016. Six consanguineous families having individuals affected with primary congenital glaucoma were recruited from different hospitals of the city. Sanger sequencing of coding exon of Cytochrome P450 1B1 gene was performed in order to identify the variants segregating with the disorder.

Results: All six families had multiple individuals affected with primary congenital glaucoma. Five out of six families (83%, 5/6) showed CYP1B1 mutations upon Sanger sequencing. All eighteen patients of five families with homozygous Cytochrome P450 1B1 gene variants had different degrees of severity of the phenotypes. Clinical evaluation of the affected members revealed congenital glaucoma with a severe phenotype of corneal oedema, photophobia and corneal scarring. The onset of the phenotype was reported to be congenital but the clinical diagnosis was delayed in four cases since medical help was not sought by the families till much later.

Conclusion: The different degrees of severe phenotypes even in individuals with the same Cytochrome P450 1B1 gene mutation suggested the involvement of modifiers in reducing or increasing the disease severity.

Keywords: CYP1B1, PCG, POAG, IOP, Mutation, Glaucoma. (JPMA 68: 1205; 2018)

Introduction

Glaucoma is the second leading cause of blindness in the world.¹ National survey of blindness and visual impairment on the population of Pakistan reported that glaucoma is the fourth (7.1%) major cause of blindness.² Primary congenital glaucoma (PCG) is a severe form of glaucoma characterised by anatomical defects of the trabecular meshwork and the anterior chamber angle of the eye. These defects block the outflow of aqueous humour leading to increased intra-ocular pressure (IOP) and optic nerve damage. PCG is usually diagnosed at birth or during the first 3 years of life with clinical symptoms of increased IOP, opacification of the cornea, epiphora, photophobia, enlargement of the globe (buphthalmos) and rupture in Descemet's membrane.³ The disease is inherited in an autosomal recessive pattern with variable penetrance.⁴

Mutations in the human Cytochrome P450 1B1 gene (CYP1B) are one of the major causes of this disorder.⁴ To date, two loci with known genes, CYP1B1 (Online Mendelian Inheritance in Man [OMIM]: 601771) at GLC3A (chromosome 2p21),⁵ LTBP2 (OMIM: 602091) at GLC3D (14q24.3)^{6,7} and two loci with

unidentified genes, GLC3B (1p36) (OMIM: 600975)⁸ and GLC3C (14q24.3) (OMIM 613085)⁹ have been linked to PCG.

The incidence of PCG in Pakistan is not known. However, variants of CYP1B1 have been described overall in 37.7% of the participating Pakistani families in combined genetic studies.¹⁰⁻¹² Nevertheless, few detailed clinical phenotypes together with genotypes have been described for PCG patients from these families. Therefore, the current study was planned to explore the role of variants in CYP1B1 in consanguineous families affected with PCG.

Subjects and Methods

The cross-sectional study was conducted at the Department of Biotechnology, Lahore College for Women University, and the School of Biological Sciences, University of the Punjab, Lahore, Pakistan, from February 2015 to October 2016, after approval was obtained from ethics committees of the two institutions and of the referring hospitals. Written informed consent was obtained from all the subjects and from parents on behalf of their young children.

Patients in six families affected with PCG were enrolled from the Children Hospital and the Institute of Child Health (CH&ICH), Lahore, and the Mayo Hospital, Lahore. PCG was diagnosed by doctors. Ophthalmic examination was conducted using Goldman or Perkins applanation tonometer (Medtronic, Minneapolis MN), slit lamp

¹⁻⁶Department of Biotechnology, Lahore College for Women University, Lahore, ⁷School of Biological Sciences, University of Punjab, Lahore.

Correspondence: Rasheeda Bashir. Email: rashidasbs@yahoo.com

biomicroscopy, perimetry and ophthalmoscopy. Retinal Nerve Fibre Layer (RNFL) assessment was obtained wherever possible. Diagnosis was made according to the following criteria: age at onset ranging from birth to 3 years, raised IOP of >21 mmHg or >16 mmHg in at least one eye under general anaesthesia, cup-to-disc (C/D) ratio >0.3 of optic nerve. The C/D ratio of the affected eyes ranged from 0.3 to complete cupping. Megalocornea (corneal diameter >12mm) and rupture in Descemet's membrane were also considered.¹³

Blood samples were obtained from affected and unaffected family members. Deoxyribonucleic acid (DNA) was extracted from whole blood by a standard method.¹⁴ Three sets of primers for CYP1B1 were designed for amplifying and sequencing the two coding exons using Primer 3.¹⁵

CYP1B1 coding exons were amplified by polymerase chain reaction (PCR) using 50ng of DNA. Each reaction was set in a final volume of 50µl, which contained 1X PCR buffer, 0.24µM of each primer, 200µM of each deoxyribonucleotide triphosphate (dNTP), 0.15-0.25 units of thermusaquaticus DNA (TaqDNA) polymerase (MBI Fermentas, Vilnius, Lithuania) and 1.5-3 mM magnesium chloride (MgCl₂). PCR thermal conditions included an initial denaturation of DNA at 94°C for 4 minutes followed by 36 cycles of 94°C for 45 seconds, annealing at 62°C for exon 2 and 57°C for exon 3 for 45 seconds followed by extension at 72°C for 45 seconds to 75 seconds. The final extension was completed at 72°C for 10 minutes. Products were purified by Quick Gel Extraction Kit (Invitrogen™, Carlsbad, CA, USA). The required gel band was cut and dissolved by adding Gel solubilisation buffer with the ratio of 6:1. The Eppendorf tube was placed into water bath at 50°C for 10 minutes to dissolve the gel. The dissolved gel was pipetted onto gel extraction column inside a wash tube. The column was centrifuged at 12,000 x g for 60 second. Filtrate was thrown away and the column was placed into wash tube. For wash purpose, 500µl wash buffer containing ethanol was added and centrifuged at 12,000x g for 60 seconds. Filtrate was thrown away. For removing ethanol, the column was centrifuged again at 12,000 x g for 1-2 minutes. The filtrate was thrown away and the column was placed into a recovery tube for elution of

purified product. Then 50µl elution buffer was added and the tube was incubated for 1 minute at room temperature. Tube was centrifuged at 12,000 x g for 60 second. The recovery tube contained the purified product. The purified products were sequenced. Sequencing was performed with Big Dye Terminator® (V 3.1) Cycle Sequencing Kit (Applied Biosystems, Foster City, CA) and the samples were resolved on an ABI 3730 capillary machine. Genotyping for family coded PKH2 was performed by PCR amplifying two closely linked microsatellite markers each for CYP1B1 and LTBP2 with fluorescently labelled primers and the products were resolved by capillary electrophoresis on an ABI 3730 instrument.

Results

All six families had multiple individuals affected with PCG. Clinical evaluation of the affected members revealed

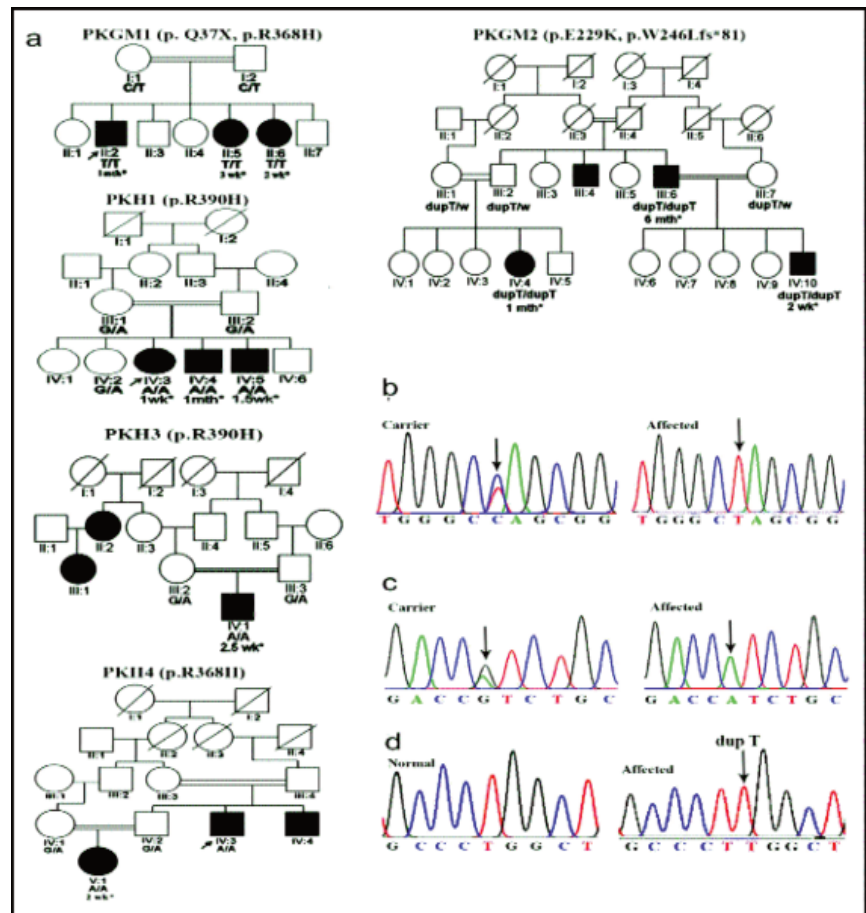


Figure-1: Pedigrees of the participating families and the sequence traces of CYP1B1 regions harboring variants. (a): Pedigrees of primary congenital glaucoma (PCG) families: PKGM1, PKGM2, PKH1, PKH3 and PKH4 respectively. Genotypes from the available subjects are indicated below the symbols. *The age of onset of disease, mth: month; wk: week. Arrow indicates the proband. (b): Electropherogram of CYP1B1 with heterozygous sequence and homozygous C to T substitution at codon 37 (p.Q37X) resulting in a stop codon in family PKGM1. (c): Electropherogram of CYP1B1 with heterozygous sequence and homozygous G to A substitution at codon 368 (p.R368H) in family PKGM1. (d): Electropherogram of the genomic DNA sequence of CYP1B1 with a homozygous duplication of T at position c.736 (p.W246Lfs*81) resulting in a frameshift mutation observed in family PKGM2.

Table-1: CYP1B1 Variants and associated clinical features of PCG patients. (Family PKGM1, PKGM2, PKH2 and PKH4).

Family ID (Mutation)	Patient No.	Age at diagnosis	Gender	Current Age (2016)	C/D ratio OD/OS	IOP at first diagnosis	Last IOP (mmHg) OD/OS	Visual acuity (VA)	Last Corneal Diameter (mm) OD/OS (after surgery)	No. of Surgical interventions	Type of Surgical intervention	Clinical Phenotype
PKGM1 (Q37X/R368H)	II:2	8 mth	M	5yrs	0.3/0.3	24/24	12/13	HM/HM	11/11	1	1X B/L trab	Bilateral buphthalmos, corneal oedema and corneal scarring.
	II:5	4 mth	F	6yrs	0.3/0.3	21/23	10/12	HM/NPL	11/11.75	1	1X B/L trab	Bilateral buphthalmos, corneal oedema and corneal scarring.
	II:6	2.5 mth	F	12yrs	0.5/0.6	31/32	24/26	HM/NPL	12.75/13	3	2X B/L trab, AGV placement in the superior temporal quadrant (OD/OS)	Buphthalmos with corneal edema and corneal scarring in left eye, right eye shrunken in size.
PKGM2 (E229K/W246LfsX81)	IV:5	1 mth	F	4yrs	0.6/0.7	22/23	18/18	PL	11/11.5	4	3X B/L trab, pupiloplasty (OS), 1X trab (OD)	Bilateral buphthalmos, corneal oedema, corneal scarring.
	IV:10	3weeks	M	3yrs	0.6/0.8	30/31	23/25	PL	12.75/13	3	2X B/L trab, 1X trab (OS)	B/L buphthalmos, corneal oedema and photophobia.
	III:6	11 yrs	M	50yrs*	0.9/0.9	ND	ND	NPL	ND	None	None	B/L buphthalmos, blindness.
PKH2 (no variant Identified)	IV:4	3mth	M	41 yrs	ND	ND	ND	NPL	ND	None	None	Bilateral buphthalmos, impaired vision.
	IV:3	2.5mth	F	56 yrs	ND	29/30	ND	NPL	12/11.5	None	None	B/L buphthalmos, severe opacification of corneas with impaired vision.
	V:3	1mth	M	4 yrs	ND	24/25	18/18	PL	12/13	1	1X B/L trab	B/L buphthalmos, excessive watering.
PKH4 (R368H)	IV:3	1.5yrs	M	39 yrs	ND	ND	ND	NPL	ND	None	None	Impaired vision.
	IV:4	1 yr	M	38 yrs	ND	ND	ND	NPL	ND	None	None	Impaired vision.
	V:1	By birth	F	9 mth	0.3/0.3	25/25	18/18	PL	13/13	2	2X B/L trab	B/L buphthalmos, enlarged globe, hazy corneas and photophobia.

congenital glaucoma with a severe phenotype of corneal oedema, photophobia and corneal scarring (Table-1,2). The onset of the phenotype was reported to be congenital but the clinical diagnosis was delayed in many cases since medical help was not sought by the families till much later.

Clinical details for families coded PKGM1 and PKGM2 (Figure-1a) were presented previously.¹⁶ Affected individuals in both pedigrees had typical symptoms of PCG. However, one affected individual in family PKGM2 was blind in contrast to the other three patients of the

family. Sequencing analyses revealed two known homozygous mutations, p.Q37X and p.R368H, in all three affected members of the family. The parents were unaffected carriers of both mutations (Figure-1b-1c). In family PKGM2, a homozygous frameshift mutation, c.736dupT, p.W246LfsX81 (Figure-1d) and a previously reported missense variant c.685G>A, p.E229K in exon 2 were identified as segregating with the phenotype.

All patients in family PKH1 had bilateral buphthalmos and suffered from corneal oedema, excessive watering and photophobia in both eyes. Patient IV: 5 had excessive

Table-2: CYP1B1 Variants and associated clinical features of PCG patients (Family PKH1 and PKH3).

Family ID (Mutation)	Patient No.	Age at diagnosis	Gender	Current Age (2016)	C/D ratio OD/OS	IOP at first diagnosis	Last IOP (mmHg) OD/OS	Visual acuity (VA)	Last Corneal Diameter (mm) OD/OS (after surgery)	No. of Surgical interventions	Type of Surgical intervention	Clinical Phenotype
PKH1(R390H)	IV:4	By birth	M	7 yrs	0.9/0.9	25/28	23/24	HM/NPL	11.75/11.75	2	2X B/L trab	B/L Buphthalmos, photophobia, hazy cornea.
	IV:5	By birth	M	1.5 yrs	0.9/0.7	26/25	24/24	NPL	15.5/14	1	1X B/L trab	B/L Buphthalmos with corneal oedema.
PKH3 (R390H)	II:2	4.5 mth	F	56 yrs*	ND	ND	ND	NPL	ND	None	None	B/L buphthalmos with impaired vision.
	III:1	2 mth	F	39 yrs*	0.8/0.9	ND	ND	NPL/HM	14/15	None	None	B/L buphthalmos, with impaired vision, rupture in Descemet's membrane.
	IV:1	2.5 wks	M	3 mth	0.5/0.4	26/28	24/24	PL	10/10	1	1XB/L trab	B/L buphthalmos and hazy cornea, photophobia.

PCG: Primary congenital glaucoma

IOP: Increased intra-ocular pressure

OD/OS: Right and Left eye

C/D: Cup-to-disc ratio

ND: Not determined

HM: Hand motion

PL: Perception of light

NPL: No perception of light

B/L: Bilateral

Trab: Trabeculectomy

AGV: Ahmed Glaucoma valve

X: Times.

All identified variants were homozygous in PCG patients.

watering and photophobia in both eyes (Figure-2a). Corneal diameter of Patient IV: 5 was 15.5/14.0 mm right and left eyes (OD/OS). The optic disc had high glaucomatous cupping with C/D ratio of 0.9/0.7 (OD/OS). Individual IV: 4 and IV:5 both underwent bilateral trabeculectomy. Patient IV: 5 had undergone surgical intervention which failed to restore vision. Patient IV: 3 had impaired vision but detailed clinical data was not available. Sequencing analysis revealed a homozygous missense variant c.1169G>A, p.R390H, in exon 3 of CYP1B1 which segregated with the phenotype in the family.

In family PKH3, symptoms of PCG were noticed in patients II: 2, III: 1 and IV: 1 within 5 months of their birth. Patient IV: 1 had severe glaucomatous cupping of the optic disc with C/D ratio of 0.5/0.4 mm (OD/OS) and had bilateral buphthalmos with epiphora, enlarged globe and photophobia in both eyes (Figure-2b). Patient IV: 1 underwent bilateral trabeculectomy. No clinical data was

available for patient II: 2. Sequencing analyses of CYP1B1 revealed the mutation c.1169 G>A, p.R390H segregating with the phenotype in the family with all affected individuals being homozygous for the mutation.

All patients of family PKH4 were affected with congenital glaucoma. Patient V: 1 had corneal oedema, epiphora, enlarged globe and photophobia in both eyes (Figure-2c). Raised bilateral IOP of 18mmHg was recorded for patient V: 1. Patients IV: 3 and IV: 4 were affected with PCG since birth and both had impaired vision. Sequencing revealed a homozygous missense mutation c.1103G>A, p.R368H, in affected individuals IV:3 and V: 1, located in exon 3 of CYP1B1. None of the mutations were observed in 120 chromosomes from normal matched controls of Pakistan.

In family PKH2, the symptoms of PCG were noticed in patients IV: 3 and IV: 4 within 3 months of birth and in patient V: 2 at 2 months of age. Patients IV: 3 and IV: 4 had bilateral buphthalmos, enlarged eye globe, photophobia,

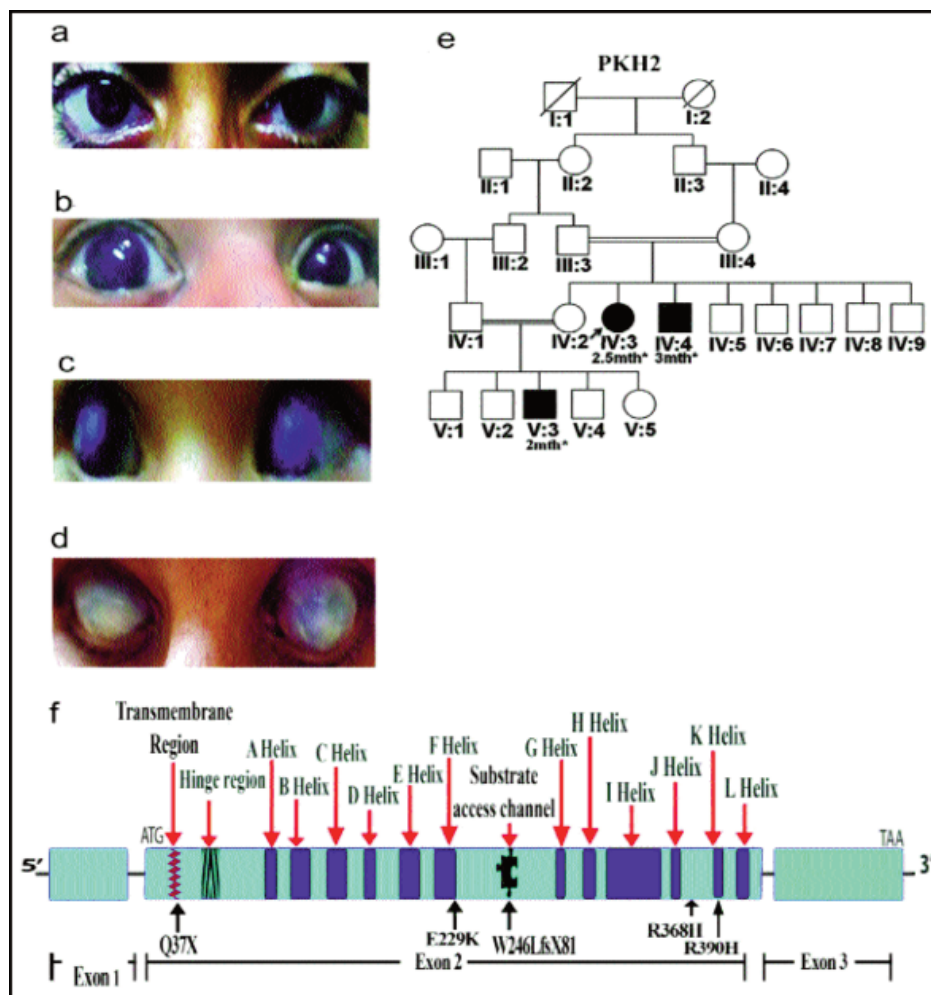


Figure-2: Clinical presentation of participating patients, family PKH2 and gene structure of CYP1B1. (a): Clinical phenotype of patient IV: 5 (family PKH1) which includes excessive watering. (b): Clinical phenotype of patient IV: 1 (family PKH3) showing enlarged eye globe. (c): Clinical phenotype of patient V: 1 (family PKH4) with hazy corneas and enlarged eye globe. (d): Clinical phenotype of patient IV: 3 (family PKH2) with complete opacification of corneas and bilateral buphthalmos. (e): Pedigree of primary congenital glaucoma (PCG) family PKH2. No variant was identified after sequencing for family PKH2 and linkage was not detected to CYP1B1 and LTBP2 locus. (f): Schematic representation of CYP1B1. Exons are represented by large boxes. Various domains of the protein encoded by the exons are also depicted. The locations of the identified mutations are indicated below the arrows.

severe opacification of cornea and impaired vision (Figure-2d-2e). Only the initial diagnosis of affected patients IV: 3 and IV: 4 were available. Maximum bilateral increased IOP of 18mmHg was recorded for patient V: 2. The patient V: 2 had megalocornea, excessive tearing and photophobia in both eyes. No mutation was detected in CYP1B1 by direct sequencing. To confirm the exclusion of CYP1B1, markers D2S1346 and D2S2238 were genotyped for all affected individuals of the family. None of the affected participants was homozygous for the alleles of these markers or shared the same haplotype at this locus, thus excluding CYP1B1 as the cause of PCG. The affected individuals were also checked for homozygosity for alleles

of LTBP2-associated short tandem repeat markers, D14S43 and D14S999, and the results similarly excluded linkage to LTBP2 as well.

Discussion

PCG due to CYP1B1 mutations is an important cause of blindness in many populations.⁶ A frameshift mutation c.736dupT, p.W246LfsX81 and other known mutations segregating with the disease phenotype in five of the six Pakistani PCG families in the study was identified.

The variant c.1169G>A; p.R390H segregated with the phenotype in families PKH1 and PKH3. The p.R390 residue is located in the CYP1B1 alpha helix K which is a highly conserved core sequence (CCS) and has a conformational role in proper protein folding and heme binding.¹⁸ The codon 390 in CYP1B1 is hypothesised to be a mutational hotspot.¹⁹ A recent study on PCG families from Pakistan found p.R390H in 5 of the 10 studied families with variable interfamilial and intra-familial disease expressivity.¹² The p.R390H mutation has also been reported to cause juvenile onset glaucoma (JOAG)²⁰ and primary open angle glaucoma (POAG).²² Additionally, the p.R390H mutation has been associated with variable

phenotypes in patients with PCG,¹¹ JOAG^[19] and POAG.¹⁰ In the present study, p.R390H was identified in two families, PKH1 and PKH3, with variable disease severity and clinical features (Table-2). The disease is more severe in patients of family PKH1 compared to that in PKH3. This variable expressivity in disease phenotype due to mutation p.R390H suggests the involvement of genetic or environmental modifiers that modulate the clinical severity due to this mutation.

Missense mutation c.1103G>A, p.R368H was homozygous in the affected participants of family PKH4. The amino acid residue R368 is located in between the helices J and K (Figure-2f) in an exposed loop of CYP1B1.¹⁸ Functional

studies have revealed a drastic decrease in the relative enzyme activity of CYP1B1 due to the p.R368H mutation.²¹ The mutation weakens the pairing with D-374 and D-367 by replacing the positively charged amino acid.¹⁸ The p.R368H variant has been reported with a frequency of 16.22%-29.16% as the most prevalent PCG mutation in India.^{19,23} In another study, p.R368H variant was implicated with a severe phenotype in 25 Indian PCG patients.²⁴ However, this variant was also found in 2% controls of Indian and 2.13% (1/47) controls from the French population.¹⁷ The p.R368H variant has been previously found in eight sporadic cases of POAG from Pakistan, but was not significantly associated with the disease phenotype because the mutation was also identified in five normal controls.¹¹ The Exome Aggregation Consortium database allele frequency for this variant in normal individuals is 0.0061 with the South Asian specific allele frequency being as high as that of 0.029 and there are 10 unaffected individuals who are homozygous for the variant as well. It is, therefore, possible that the variant is either benign or requires modifiers for its effect.

The mutations p.Q37X and p.R368H were both homozygous in all affected members of family PKGM1 (Figure-1a). Previously, these mutations were also observed together in the homozygous state in an Iranian PCG patient, but the clinical phenotype due to these mutations was not described.²⁰ The mutation p.Q37X is predicted to truncate the protein. Since the mutation introduces a premature stop codon, the transcript is predicted to be destroyed by nonsense-mediated decay and consequently the presence of the second variant is probably redundant. The disease symptoms were more severe in PCG patients of family PKGM1 in comparison to PKH4 which was only homozygous for the p.R368H mutation.

Two homozygous variants, one frameshift p.W246LfsX81 and one missense p.E229K variant of unknown significance, segregated with a severe disease phenotype of PCG in family PKGM2. The duplication of thymine at position c.735 causes a frameshift of the open reading frame. The residue 246 lies in the substrate access channel (SAC) (Figure-2f) which is likely to be involved in the substrate entrance and exit. The transcript will likely be degraded by the messenger ribonucleic acid (mRNA) surveillance system due to the presence of a premature stop codon in the transcript. However, it is possible that the message may not be degraded since the variant is in the penultimate exon. If the mutant mRNA is translated, it will give rise to a truncated protein with 80 wrongly incorporated amino acids residues. The effect of this

mutation could be pathogenic in two ways. One, this could give rise to an unstable protein and hence a complete loss of CYP1B1 may result due to its degradation by the cellular machinery. Secondly, the truncated protein will be missing the G, H, I, J, K and L helices (Figure-2f) and the loss of these domains could lead to complete loss of function of the CYP1B1 protein. All patients in family PKGM2 showed the worst disease progression with patient III:6 being blind.

The second variant p.E229K, which we identified in the same family PKGM2, accompanying the frameshift mutation has been reported in PCG and POAG patients from various populations of the world.^{10,25} Association of p.E229K mutants with severe phenotype in the homozygous and compound heterozygous carriers has also been previously reported from Pakistan.¹⁰ In addition, this variant has been previously described in the heterozygous state in two unrelated French patients affected with PCG²⁴ in five Indian patients²⁴ and in one Turkish case.²⁵ Though variant p.E229K has been reported in PCG and POAG patients from various populations of the world and is annotated as a pathogenic allele,²⁶ it is likely to be either a polymorphism, or a risk allele of modest effect, requiring other gene variants for its effect. This is supported by the high allele frequency of this variant in normal controls.¹⁶ For example, the overall Exome Aggregation Consortium (ExAC) database²⁷ allele frequency is 0.01423 and the South Asian specific allele frequency is 0.056 which includes 41 homozygous individuals. Recently, the c.736dupT, p.W246LfsX81 variant, was reported as a cause of PCG in a Pakistani family with severe phenotype in two patients.²⁸ However, in our cohort of five families with CYP1B1 variants, the presence of p.W246LfsX81 and p.E229K mutations together resulted in the worst disease progression in family PKGM2 compared to that manifested in others. It is noteworthy that — patients IV: 5 and IV: 10 underwent four and three surgical procedures respectively to control the IOP, while patient III: 6 of this family was blind.

Conclusion

Different mutations of CYP1B1 were found and suggested a similar role of modifier genes or environmental factors which caused the variability in the phenotype due to CYP1B1 mutations as suggested previously. Additional studies using whole-exome sequencing on DNA of severely affected patients and those of less affected individuals could reveal the identity of these genetic modifiers. This information will help in developing treatments and cures for one of the most significant contributors to hereditary blindness.

Disclaimer: None.

Conflict of Interests: None.

Source of Funding: Higher Education Commission, Islamabad, Pakistan.

References

1. Pascolini D, Mariotti SP. Global estimates of visual impairment: 2010. *Br J Ophthalmol* 2012; 96: 614-8.
2. Dineen B, Bourne R, Jadoon Z, Shah SP, Khan MA, Foster A, et al. Causes of blindness and visual impairment in Pakistan. The Pakistan national blindness and visual impairment survey. *Br J Ophthalmol* 2007; 91:1005-10.
3. Berraho A, Serrou A, Fritez N, Annas AE, Bencherifa F, Gaboun F, et al. Genotype-Phenotype Correlation in Moroccan Patients With Primary Congenital Glaucoma. *J Glaucoma* 2015; 24: 297-05.
4. Faiq M, Sharma R, Dada R, Mohanty K, Saluja D, Dada T. Genetic, Biochemical and Clinical Insights into Primary Congenital Glaucoma. *J Curr Glaucoma Pract* 2013; 7: 66-84.
5. Sarfarazi M, Akarsu NA, Hossain A, Turacli EM, Aktan GS, Barsoum-Homsy M, et al. Assignment of a locus (GLC3A) for primary congenital glaucoma (Buphthalmos) to 2p21 and evidence for genetic heterogeneity. *Genomics* 1995; 30: 171-7.
6. Cascella R, Strafella C, Germani C, Novelli G, Ricci F, Zampatti S, et al. The Genetics and the Genomics of Primary Congenital Glaucoma. *Biomed Res Int* 2015; 2015: 321291.
7. Ali M, McKibbin M, Booth A, Parry DA, Jain P, Riazuddin S, et al. Null Mutations in LTBP2 Cause Primary Congenital Glaucoma. *Am J Hum Genet* 2009; 84: 664-71.
8. Akarsu AN, Turacli ME, Aktan SG, Barsoum-Homsy M, Chevrette L, Sayli BS, et al. A second locus (GLC3B) for primary congenital glaucoma (Buphthalmos) maps to the 1p36 region. *Hum Mol Genet* 1996; 5:1199-03.
9. Stoilov IR, Sarfarazi M. The third genetic locus (GLC3C) for primary congenital glaucoma (PCG) maps to chromosome 14q24.3. *Invest Ophthalmol Vis Sci* 2002; 43: e3015.
10. Firasat S, Riazuddin SA, Khan SN, Riazuddin S. Novel CYP1B1 mutations in consanguineous Pakistani families with primary congenital glaucoma. *Mol Vis* 2008; 14: 2002-9.
11. Micheal S, Ayub H, Zafar SN, Bakker B, Ali M, Akhtar F, et al. Identification of novel CYP1B1 gene mutations in patients with primary congenital and primary open angle glaucoma. *Clin Exp Ophthalmol* 2014; 43: 31-9.
12. Sheikh SA, Waryah AM, Narsani AK, Shaikh H, Gilal IA, Shah K, et al. Mutational spectrum of the CYP1B1 gene in Pakistani patients with primary congenital glaucoma: Novel variants and genotype-phenotype correlations. *Mol Vis* 2014; 20: 991-1001.
13. Weinreb RN, Grajewski AL, Papadopoulos M, Grigg J, Freedman S. Establishing the diagnosis and determining the progression of glaucoma. Consensus on childhood glaucoma. Amsterdam: Kugler publications, 2013; pp 19-109.
14. Grimberg J, Nawoschik S, Belluscio L, McKee R, Turck A, Eisenberg A. A simple and efficient non-organic procedure for the isolation of genomic DNA from blood. *Nucleic Acids Res* 1989;17: 8390.
15. Primer 3. [Online] [Cited 2016 Oct 16]. Available from: URL: http://biotools.umassmed.edu/bioapps/primer3_www.cgi
16. Bashir R, Sanai M, Azeem A, Altaf I, Saleem F, Naz S. Contribution of GLC3A locus to Primary Congenital Glaucoma in Pakistani population. *Pak J Med Scien* 2014; 30: 1341-45.
17. Kumar A, Basavaraj MG, Gupta SK, Qamar I, Ali AM, BajajV, et al. Role of CYP1B1, MYOC, OPTN and OPTC genes in adult-onset primary open-angle glaucoma: predominance of CYP1B1 mutations in Indian patients. *Mol Vis* 2007; 13: 667-76.
18. Tanwar M, Dada T, Sihota R, Das TK, Yadav U, Dada R. Mutation spectrum of CYP1B1 in North Indian congenital glaucoma patients. *Mol Vis* 2009; 15:1200-9.
19. Reddy AB, Kaur K, Mandal AK, Panicker SG, Thomas R, Hasnain SE, et al. Mutation spectrum of the CYP1B1 gene in Indian primary congenital glaucoma patients. *Mol Vis* 2004;10:696-702.
20. Suri F, Yazdani S, Narooie-Nejhad M, Zargar SJ, Paylakhi SH, Zeinali S, et al. Variable expressivity and high penetrance of CYP1B1 mutations associated with primary congenital glaucoma. *Ophthalmol* 2009; 116: 2101-09.
21. Pasutto F, Chavarria-Soley G, Mardin CY, Michels-Rautenstrauss K, Ingelman-Sundberg M, Fernández-Martínez L, et al. Heterozygous loss-of-function variants in CYP1B1 predispose to primary open-angle glaucoma. *Invest Ophthalmol Vis Sci* 2010; 51: 249-54.
22. Su C, Liu Y, Li S, Yang J, Yen Y. Mutations in the CYP1B1 gene may contribute to juvenile-onset open-angle glaucoma. *Eye* 2012; 26: 1369-77.
23. Reddy AB, Panicker SG, Mandal AK, Hasnain SE, Balasubramanian D. Identification of R368H as a Predominant CYP1B1 Allele Causing Primary Congenital Glaucoma in Indian Patients. *Invest Ophthalmol Vis Sci* 2003; 44: 4200-3.
24. Panicker SG, Mandal AK, Reddy AB, Gothwal VK, Hasnain SE. Correlations of Genotype with Phenotype in Indian Patients with Primary Congenital Glaucoma. *Invest Ophthalmol Vis Sci* 2004; 45: 1149-56.
25. Bagiyeva S, Marfany G, Gonzalez-Angulo O, Gonzalez-Duarte R. Mutational screening of CYP1B1 in Turkish PCG families and functional analyses of newly detected mutations. *Mol Vis* 2007; 13: 1458-68.
26. Human Gene Mutation Database. [Online] [Cited 2016 Sep 16]. Available from: URL: <http://www.hgmd.cf.ac.uk/ac/all.php>.
27. Exome Aggregation Consortium. [Online] [Cited 2016 Oct 16]. Available from: URL: <http://exac.broadinstitute.org/variant>
28. Rauf B, Irum B, Kabir F, Firasat S, Naeem MA, Khan SN, et al. A spectrum of CYP1B1 mutations associated with primary congenital glaucoma in families of Pakistani descent. *Hum Gen Var* 2016; 3: 16021.