

## Optic nerve Schwannoma: Neurofibromatosis Type-1? A case report

Muhammad Junaid,<sup>1</sup> Syed Sarmad Bukhari,<sup>2</sup> Mamoon Ur Rashid<sup>3</sup>

### Abstract

Optic nerve Schwannoma is a very rare tumour described in literature. The rarity of this tumour is due to the fact that the optic nerve is myelinated by oligodendrocytes. We present a case of an ancient optic nerve schwannoma in a 16 year old girl who presented to the clinic with right sided proptosis and bilateral loss of vision. She underwent complete excision of the tumour via a craniotomy and histopathology was confirmatory. The various theories explaining the origin of this tumour are discussed along with surgical nuances of removing this tumour. The importance of taking every precaution to preserve vision and avoiding imaging confusion in patients with von Recklinghausen syndrome is also discussed. Only 6 cases of optic nerve schwannomas are described in literature while none have been described in a patient with NF 1.

**Keywords:** optic nerve, schwannoma, neurofibromatosis 1, Evoked Potentials, Visual

### Introduction

Schwannomas are benign tumours arising from schwann cells that are present in the peripheral nerves. The optic nerve is a cranial nerve that is technically a part of the central nervous system because of its embryological derivation as an outpouching of the diencephalon. The myelin covering the optic nerve is derived from oligodendrocytes hence conditions like peripheral neuropathy do not affect the optic nerve.<sup>1</sup> Schwannomas have been described to have an association with Neurofibromatosis type 1 (NF 1), which is a genetic condition due to mutation of a gene on chromosome 17. It is a neurocutaneous disorder characterized by the development of multiple neurofibromas in peripheral nerve sheaths. The presence of a schwannoma in the setting of NF 1 is exceedingly rare with only 6 reported cases.<sup>2</sup> Here we present a case of optic nerve schwannoma in a patient

<sup>1</sup>Neurosurgery, Bahria Medical and Dental College, Karachi, <sup>2</sup>Department of Neurosurgery, Aga Khan University Hospital, Karachi, <sup>3</sup>Department of Internal Medicine, Florida Hospital, Orlando, FL, USA.

**Correspondence:** Syed Sarmad Bukhari. Email: sarmad.bukhari@aku.edu.

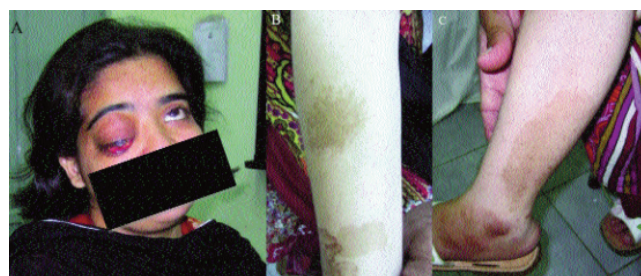with Neurofibromatosis type 1.

### Case Report

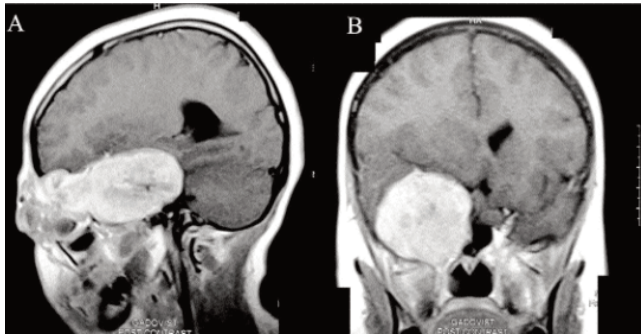
A 16 year old girl was seen in the neurosurgical clinic of Combined Military Hospital Peshawar in June of 2012, with a 3 year history of progressive proptosis in the right eye. She had lost vision in both eyes 1 year ago. She also had progressively increasing headache for the last 6 months.

On examination her GCS was 15/15 with no sensory (except complete visual loss bilaterally) or cognitive deficit. For this reason no ophthalmological examination or review was taken or documented. There was proptosis of the right eye of 1 cm with ophthalmoplegia (Figure-1a). She had multiple Café au lait spots (Figure 1b and 1c). MRI brain with contrast (Figure-2a and b) showed a homogenously contrast enhancing space occupying lesion in the right anterior cranial fossa measuring 8.5 cm x 5 cm x 5 cm. Coronal sections demonstrated its intraorbital extension (Figure-2b). It had a central area of heterogenous enhancement which were consistent with age related degenerative changes in the tumour. The tumour was directly compressing the optic chiasm area and therefore causing bilateral vision loss. The MRI also demonstrated sphenoid wing hypoplasia which provided definite evidence of NF1 hence genetic testing was not pursued. Consent was taken from the parents prior to surgery for publishing of this case.

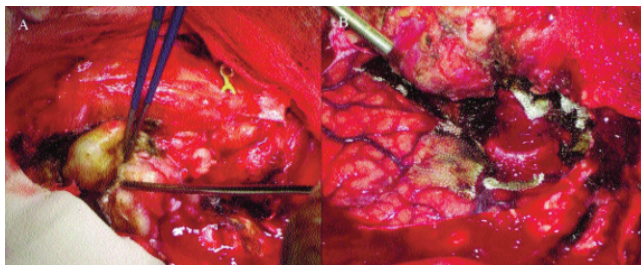
She underwent a right sided pterional craniotomy. Intraoperatively the lesion was found to be adherent to the nerve sheath and a plane was present which allowed



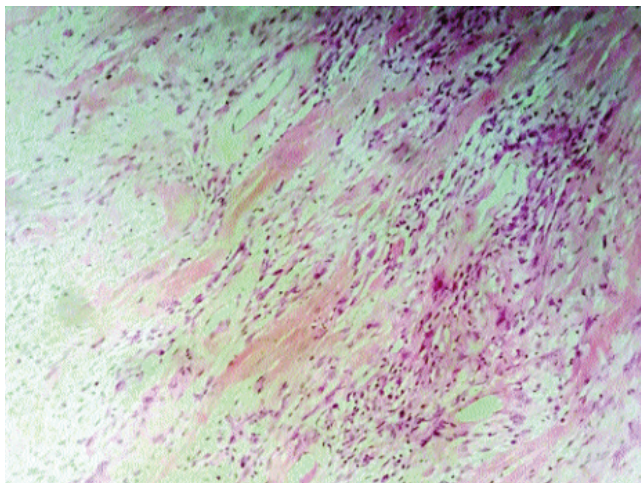
**Figure-1:** Preoperative examination of the patient revealed significant proptosis with ophthalmoplegia and several large and small café au lait spots covering her entire body. No cutaneous neurofibromas.



**Figure-2:** Preoperative MRI brain showing the contrast enhancing lesion with its point of origin from the optic nerve. (a) Sagittal section (b) Coronal section).

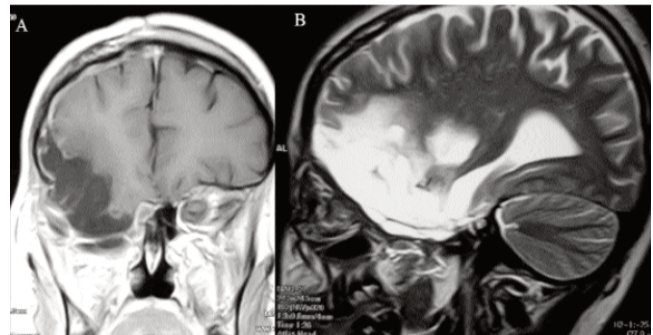


**Figure-3:** Intraoperative photograph showing the yellowish firm tumour during resection (a) and the tumour bed post resection (b).



**Figure-4:** Photomicrograph showing spindle shaped cells with hyper and hypocellular areas and formation of Verocay bodies. Scattered cells showed degenerative atypia with no evidence of malignancy.

separation of the tumour from the nerve. Special care was taken when dissecting it away from the medial expansions and there was no injury to the internal carotid artery. The lesion was fully excised (Figure-3a and 3b). On gross examination the tumour was firm and yellowish in colour.



**Figure-5:** Postoperative MRI at 1 year follow up demonstrating complete excision and fluid filled cavity. (a) sagittal section and (b) coronal section.

Postoperatively she was kept in ICU and then moved to the general ward. Her recovery was uneventful and was discharged on post-operative day 5. Stitches were removed on the 12th post op day. Her headache had improved with occasional requirement of analgesics. Post op MRI showed complete excision with no residual tumour.

Histopathology showed spindle shaped cells with hyper and hypocellular areas and formation of Verocay bodies. Scattered cells showed degenerative atypia with no evidence of malignancy. This was consistent with the diagnosis of ancient schwannoma (Figure-4).

She was followed up till a period of two years. Her vision did not improve and a follow up MRI (Figure-5) showed no evidence of recurrence.

## Discussion

The word schwannoma is not usually associated with either the optic nerve or neurofibromatosis type 1. The origin of the optic nerve as a derivative of the central nervous system precludes the formation of schwannomas in this structure. Its fibers arise from the lateral geniculate body and are myelinated by oligodendrocytes. Neurofibromatosis type 1 is autosomal dominant neurocutaneous disorder characterized by benign neurofibromas but malignant tumours also occur. There have been only three reported cases of schwannomas occurring in patients with NF 1. However they were not intracranial but one was in the spine, one in the presacral region and the third in the thigh.<sup>3-5</sup> To the best of our knowledge and literature review, we present the first reported case of an optic nerve schwannoma in a patient with NF 1.

Only 6 known cases of optic nerve schwannomas have been encountered in literature with several theories to explain their development in this structure. The optic nerve and its sheath are innervated by sympathetic

fibers that are myelinated by Schwann cells these are a potential source.<sup>6</sup> Another possible source is the sympathetic fibers supplying the central artery in case of schwannomas located more centrally within the structure.<sup>7</sup> There is also speculation that there exist aberrant Schwann cells that may give rise to tumours but this appears far less likely.

These tumours would generally be identified early due to loss of vision but in our case it grew to a large size owing to delay in seeking care. In this case a pterional craniotomy was the only approach that would give appropriate exposure. For lesions that are intraorbital, an endonasal endoscopic approach may be used in cases where sparing vision is a consideration.<sup>7</sup>

The extreme rarity of such a case merits a discussion of imaging characteristics of these tumours. Patients with NF 1 require PET scanning with FDG to differentiate between benign neurofibromas or schwannomas and malignant peripheral nerve sheath tumours (MPNSTs). Malignant tumours will show greater metabolic activity when compared to schwannomas but neurofibromas will be similar. However there is a reported case of a schwannoma with high metabolic activity that was mistaken for a MPNST.<sup>5</sup> This results in a potential pitfall for diagnosing these lesions in a patient with NF 1.

Our patient had complete loss of vision but in preventing damage to a visually intact patient's optic nerve takes precedence. Many methods have been suggested to achieve this but the clinical usefulness of these techniques is yet unproven. Intraoperative monitoring of visual evoked potentials has been touted to be useful in this regard but to achieve stable VEPs, direct stimulation of the optic nerve is recommended.<sup>8</sup>

In patients where vision salvage is a priority, the use of radiotherapy is an option. The data on this has to be garnered from treatment of schwannomas in other locations. For intracranial schwannomas, linear accelerator based radiotherapy has been shown to provide a high rate of neurological preservation with long term tumour control.<sup>9</sup> However in our case, the tumour was too large to be subjected to radiation and a craniotomy was considered the best option.

## Conclusion

Optic nerve schwannomas are very rare lesions. This was the seventh reported case, and the only case in conjunction with NF 1. It is important to be aware of this to avoid a potential pitfall in patients with NF 1 when looking for MPNSTs.

## Limitations

Genetic testing was not done in this case because of financial implications and unavailability. However clinical confirmation of NF-1 was available.

**Disclaimer:** None.

**Conflicts of Interest:** None.

**Funding Sources:** None.

## References

1. Kiernan JA, Barr ML, Rajakumar N. Barr's the human nervous system: an anatomical viewpoint. Philadelphia: Wolters Kluwer Lippincott Williams & Wilkins; 2014.
2. Ahlawat S, Blakeley J, Montgomery E, Subramaniam RM, Belzberg A, Fayad LM. Schwannoma in neurofibromatosis type 1: a pitfall for detecting malignancy by metabolic imaging. *Skeletal Radiol* 2013; 42: 1317-22.
3. Honda E, Hayashi T, Goto S, Oshima Y, Kikuchi N, Utsunomiya H, et al. Two different spinal tumours (meningioma and schwannoma) with von Recklinghausen's disease in a case. *No Shinkei Geka* 1990; 18: 463-8.
4. Watanabe M, Ishikawa N, Kameoka N. Presacral Schwannoma in a patient with von Recklinghausen's disease: case report. *Jpn J Gastroenterol Surg* 2002; 25: 436-9.
5. Ahlawat S, Blakeley J, Montgomery E, Subramaniam RM, Belzberg A, Fayad LM. Schwannoma in neurofibromatosis type 1: a pitfall for detecting malignancy by metabolic imaging. *Skeletal Radiol* 2013; 42: 1317-22.
6. Kim DS, Choi JU, Yang KH, Jung JM. Optic sheath schwannomas: report of two cases. *Childs Nervous Syst* 2002; 18: 684-9.
7. Ramey WL, Arnold SJ, Chiu A, Lemole M. A Rare Case of Optic Nerve Schwannoma: Case Report and Review of the Literature. *Cureus* 2015; 7: e265.
8. San-Juan D, Escanio Cortés M, Tena-Suck M, Orozco Garduño AJ, López Pizano JA, Villanueva Domínguez J, et al. Neurophysiological intraoperative monitoring during an optic nerve schwannoma removal. *J Clin Monit Comput* 2017; 31: 1059-64.
9. Zolotova SV, Golanov AV, Kotel'nikova TM, Soboleva OI, Gorlachev GE, Fil'chenkova NA, et al. [Stereotactic radiotherapy and radiosurgery in treatment of patients with intracranial schwannomas]. *Zh Vopr Neirokhirml N N Burdenko* 2010; 1:18-23.