

Staged dental extraction and three interim prostheses for implants based rehabilitation in a periodontally compromised subject

Farhan Raza Khan,¹ Rabia Ali²

Abstract

Studies have shown that the presence of advanced periodontal disease lowers the success of dental implants. The recommended approach for such cases is the delayed placement and delayed loading of implants. The present paper reports a case of a subject who presented with severe periodontally compromised dentition. Placement and early loading of 12 implants was done using a staged approach. Three different sets of fixed-type dental prostheses were employed in the interim period. The final prostheses were cement retained metallo-ceramic fixed bridge. Use of staged extraction and using three sets of interim prostheses helped the patient to maintain his aesthetics and function during the entire treatment period. This approach can be a predictable management option in cases of advanced periodontitis. The key is proper planning and execution of the implant surgery and prosthetics.

Keywords: Dental implants, Periodontal disease, Staged extraction, Missing teeth.

Introduction

Dental implants have become the standard of care for replacement of missing teeth. They are titanium based root- form screws that are inserted into the jaw bone to support and retain the dental prosthesis. Conventionally, implants are placed in the jaw bone for around 3-9 months before being fitted and loaded with the prosthetic teeth.¹

Since placement and loading is a skill intensive area of dental practice, the operator dependent factor has the greatest influence on the procedure success. There are several host factors that too determine the longevity of implants. These include periodontal disease, smoking, poor oral hygiene and diabetes etc.²

When the treatment plan warrants extraction of all remaining teeth, different treatment options can be applied and sequenced, and the patient can be

¹Dental Section, ²Dentistry, Aga Khan University, Karachi, Pakistan.

Correspondence: Farhan Raza Khan. Email: farhan.raza@aku.edu

rehabilitated with an implant-supported fixed restoration.³

As an increasing number of patients receive implants to replace missing teeth lost due to periodontitis, the question arises as to whether a history of periodontitis may increase the risk of peri-implant disease (e.g. mucositis and peri-implantitis) and implant loss.⁴

This case was challenging as our patient, because of his profession, didn't want to remain toothless even for a single day. It is a perfect example of gradual transition from natural, to tooth supported interim prosthesis, to implant supported dentition, hence avoiding the period of edentulism and is therefore worth reporting.

Case Report

This is a case of a 50 years old male who presented to the dental clinics of the Aga Khan University Hospital Karachi, in August 2014 with the chief complaint of multiple mobile and sensitive teeth and an overall dissatisfaction with his smile. He had undergone full mouth scaling procedure in the past. His medical history revealed that he is pre-diabetic with a negative drug and smoking history. He was a surgeon by profession and therefore conscious of his social appearance. The general physical examination was unremarkable. His extra oral examination revealed normal temporomandibular joints, no palpable lymph nodes, no swelling or facial asymmetry.

His intra oral examination revealed generalized moderate plaque and calculus deposits and typical features of chronic periodontitis. There were more than 6mm of periodontal pocket depths in all four quadrants of the dentition. All of his maxillary and mandibular incisors were mobile with grade 3 mobility while all upper and lower molars exhibited grade 2 mobility. Both maxillary and mandibular canines were comparatively stable. Initial investigations included full mouth periapical series and an orthopantomogram. A final diagnosis of chronic periodontitis secondary to poor oral hygiene was made. The patient expressed an interest in receiving a fixed solution for his mobile and missing teeth. The definitive plan was to extract all

teeth followed by full mouth reconstruction with cemented fixed metallo-ceramic prostheses retained over 12 implants. This plan was discussed and was agreed upon by the patient. A written informed consent was obtained from the patient. Approval from the head of the department was also obtained for the publication of the present case. The treatment plan was divided into four phases.

First Stage: Extractions

Upper and lower impressions were taken to obtain study casts. Upper and lower clear plastic vacuum formed stents were fabricated using mounted teeth. Extraction of all the teeth except #13, 23, 33, 43, 17, 27, 37, 47, 38 and 48 were done under local anaesthesia. In the same visit, the above mentioned spared teeth were prepared to receive tooth supported resin based temporary prostheses. These were constructed using the pre-made stents and retained with the zinc oxide based temporary cement.

Second Stage: Implant Surgery

It involved placement of 12 implants in the positions of #12, 22, 32, 42, 14, 24, 34, 44, 16, 26, 36 and 46. All implants were Zimmer- TSV type, placed under local anaesthesia, adhering to the non- submerged protocol. The implants placed in the incisor, premolar and molar zone had 3.7mm, 4.7mm and 6.0mm diameters, respectively. The surgery was done in a free hand manner and fortunately all implants yielded a primary stability of > 30 Ncm. In the same visit, the fixture mount transfer of all implants (except molars) were reduced to receive a new temporary cement retained fixed prosthesis. These

prostheses were tooth and implant borne (retained over 4 implants and four natural teeth in each arch) and were made using the same vacuum formed stents that were used earlier. Thus, the esthetics gained in the first stage was maintained.

Third Stage: Full mouth dental clearance and interim prosthesis

It involved extraction of all remaining teeth except lower third molars, followed by modification of existing temporary prostheses to transform them into screw retained design (Figure-1). It was achieved using plastic abutments and dual cure resin. This design helped in maintaining the hygiene and provided ease in the retrievability. Hence, all the implants were loaded within 45 days of placement.

Fourth Phase: Prosthetic stage

It involved fabrication of metallo-ceramic fixed prosthesis for both arches. The single piece casting trial was done to assess the passive fit and margins. Occlusal records were obtained. Laboratory technician was guided to use the tooth mounted casts (initially used for fabricating vacuum formed stents) as antagonists while layering the ceramic on the working cast framework. This was done to ensure that the esthetics was not significantly altered. In the subsequent visit, bisque-bake trial was done and the final adjustments were made in the mouth in static and dynamic occlusion. After glazing, the prosthesis was placed using temporary cement (Figure-2).

Avoiding the period of edentulism by providing fixed solution in the interim period using teeth and implants in

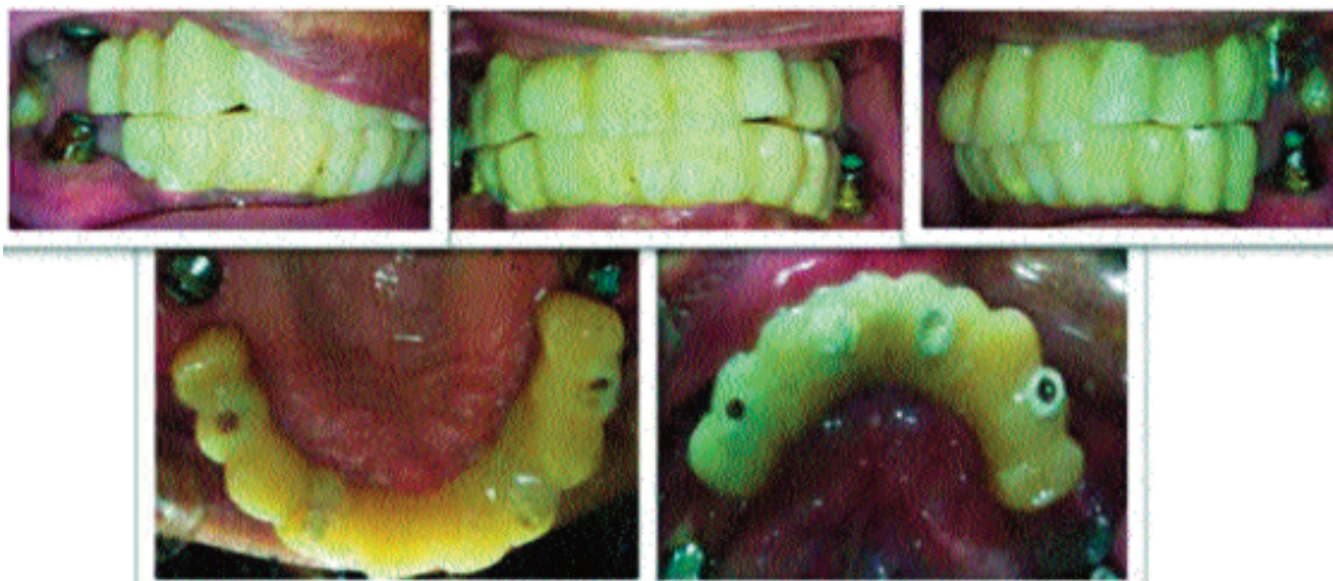

Figure-1: Screw retained upper and lower temporary prostheses extending upto premolars region.

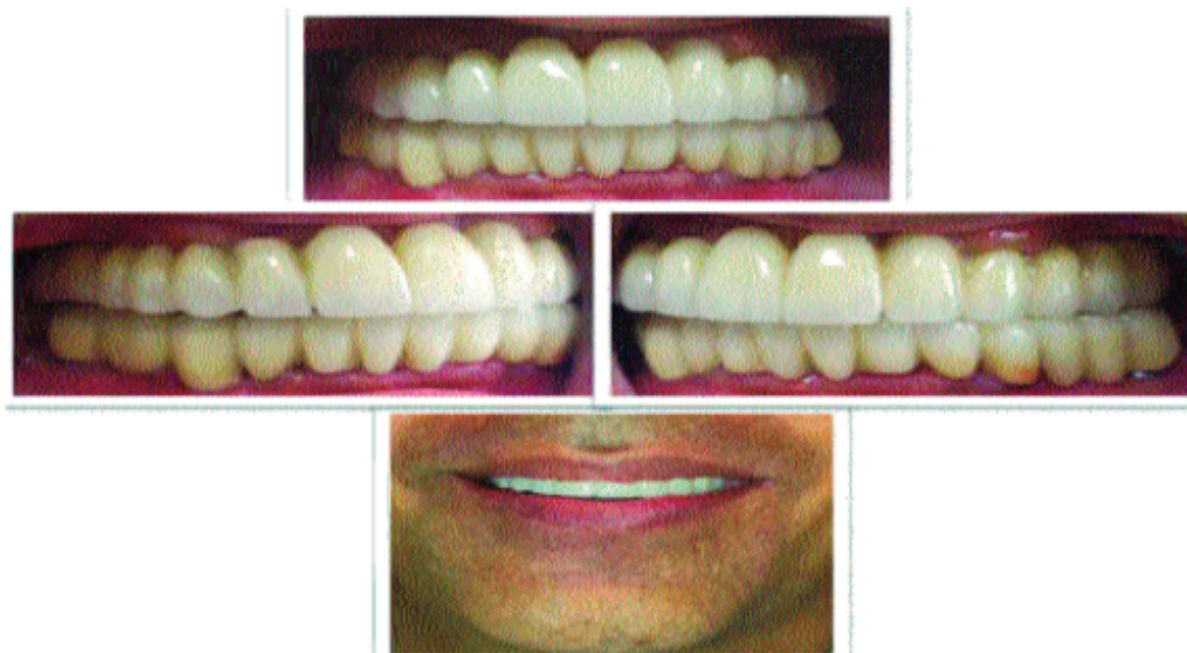

Figure-2: Appearance of the final prostheses.

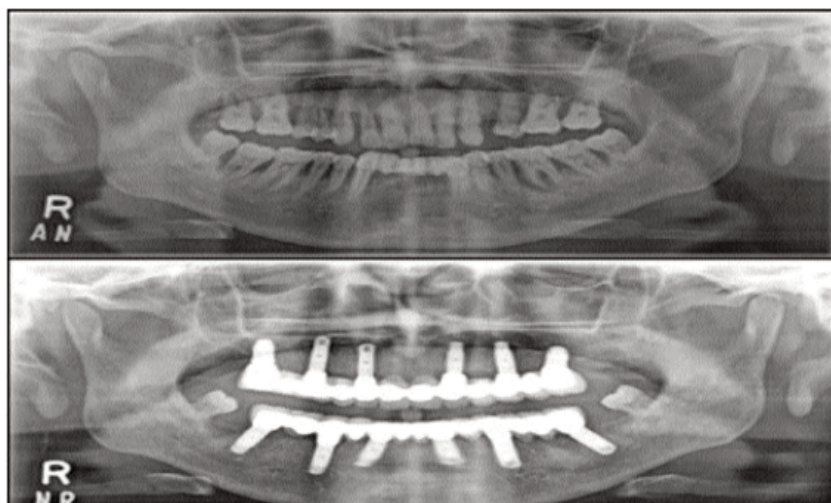


Figure-3: Comparison of pre-operative and final panoramic images.

a stage-wise manner was appreciated by the patient and was extremely pleased with the esthetic and functional outcome (Figure-3). Patient was kept on initial follow up 1 month post-insertion, then 6 months and then annual follow-ups for routine hygiene maintenance appointments. He was doing well on 24 months post implant surgery.

Discussion

Dental implants may be preferable to conventional

dentures in patients with compromised supporting bone or mucosa, xerostomia, allergy to denture materials, severe gag reflex, susceptibility to candidiasis, diseases affecting orofacial motor function or in patients who demand optimal bite force, esthetics, and phonetics.⁵

The main predictors for implant success are the quantity and quality of bone, the patient's age, the dentist's experience, location of implant placement, length of the implant, axial loading, and oral hygiene maintenance. Primary predictors of implant failure are poor bone quality, chronic periodontitis, systemic diseases, smoking, unresolved caries or infection, advanced age, implant location, short implants, acentric loading, an inadequate number of implants, parafunctional habits and absence/loss of implant integration with hard and soft tissues. Inappropriate prosthesis design may also contribute to implant failure.⁶

The transition of patients from a dentate state to an implant-supported restoration requires significant planning. Traditionally, protocols have included the extraction of teeth and interim use of a removable prosthesis. Newer protocols include approaches to decrease the period of

time a patient is required to use a traditional denture.⁷

There are four basic interim approaches that can be used to transition a patient from a dentition with guarded prognosis to a reconstructed arch; use of a provisional removable denture, immediate loading of dental implants with a provisional fixed partial denture, placement of transitional mini-implants to support a fixed provisional prosthesis, staged extraction of teeth and coordinated placement of dental implants.⁸ We took the fourth option.

Our main concerns in this case of periodontally compromised patient were the outcome of implants and whether to manage it with immediate loading versus conventional loading approach. Moreover, the patient (a medically qualified surgeon himself) had high esthetic demands, which made the interim phase of the treatment more critical.

There were three sets of temporary prostheses employed in the present case, the first one was tooth borne, the second one was tooth and implant borne and the third set was a screw-retained implant borne interim prosthesis. This staged extraction technique along with strategic implant placement led to ease of retaining the temporary or provisional restoration in place and at the same time addressing patient's esthetic issues as well.

According to a systematic review, the implant loading protocol (immediate loading vs. conventional loading) did not affect the survival of the implants (p -value= 0.47). There was no statistically significant difference in marginal bone loss (p -value= 0.24) The reported mechanical and biological complications were common to both types of intervention, with the exception of probing depth, which was greater for the immediate loading technique, although that was not statistically significant (p -value = 0.43).⁹ In the present case report, following the attainment of primary stability of >30 Ncm, the dental implants were loaded early (within 45 days) which turned out to be functionally and esthetically favorable to the patient.

Another systematic review assessed the long-term (>5 years) clinical and/or radiographic outcomes of patients with periodontitis submitted to periodontal therapy/maintenance and implant placement. The results demonstrated that patients with a diagnosis of periodontitis had satisfactory implants outcomes as found by the high implant survival rate (92.1%) after 10

years of follow up.¹⁰

Conclusion

Contrary to general belief, immediate placement and early loading of implants for full mouth reconstruction can be a predictable option in cases of advanced periodontitis. The key is proper planning and execution of the implant surgery and prosthetics.

Disclaimer: None to declare.

Conflict of Interest: Since the present manuscript is a case report that does not require an IRB certificate, but a letter of approval from the head of the department was obtained stating that ethical practices were followed in the management & reporting of the case. As one of the co-authors happens to be the head of the department also, so this may constitute a potential conflict of interest.

Funding Disclosure: None to declare.

References

1. Mijiritsky E, Mazor Z, Lorean A, Mortellaro C, Mardinger O, Levin L. Transition from hopeless dentition to full-arch fixed-implant-supported rehabilitation by a staged extraction approach: rationale and technique. *J Craniofac Surg.* 2014; 25: 847-50.
2. Bahat O, Sullivan RM. Parameters for successful implant integration revisited part I: immediate loading considered in light of the original prerequisites for osseointegration. *Clin Implant Dent Relat Res.* 2010; 12: e2-12.
3. Qamheya AH, Yenyol S, Arisan V. Full Mouth Oral Rehabilitation by Maxillary Implant Supported Hybrid Denture Employing a Fiber Reinforced Material Instead of Conventional PMMA. *Case Rep Dent.* 2015; 2015: 841745.
4. Gianserra R, Cavalcanti R, Oreglia F, Manfredonia MF, Esposito M. Outcome of dental implants in patients with and without a history of periodontitis: a 5-year pragmatic multicentre retrospective cohort study of 1727 patients. *Eur J Oral Implantol.* 2010; 3: 307-14.
5. Sugeran PB, Barber MT. Patient selection for endosseous dental implants: oral and systemic considerations. *Int J Oral Maxillofac Implants.* 2002; 17: 191-201.
6. Porter JA, von Fraunhofer JA. Success or failure of dental implants? A literature review with treatment considerations. *Gen Dent.* 2005; 53: 423-32.
7. Sharma AB, Yonemura CY, Curtis DA, Finzen FC. Transitioning patients: teeth to implants. *J Calif Dent Assoc.* 2008; 36: 269-73.
8. Cordaro L, Torsello F, Ercoli C, Gallucci G. Transition from failing dentition to a fixed implant-supported restoration: a staged approach. *Int J Periodontics Restorative Dent.* 2007; 27: 481-7.
9. Kim KK, Sung HM. Outcomes of dental implant treatment in patients with generalized aggressive periodontitis: a systematic review. *J Adv Prosthodont.* 2012; 4: 210-7.
10. Faggion CM Jr, Giannakopoulos NN. Critical appraisal of systematic reviews on the effect of a history of periodontitis on dental implant loss. *J Clin Periodontol.* 2013; 40: 542-52.