

Central venoplasty in AV (Arteriovenous) fistula dysfunction a palliative endovascular approach

Tariq Ashraf, Naeem Mengal, Naveed Ullah Khan, Parveen Akhtar

Abstract

The ultimate treatment of chronic kidney disease is renal transplant. Patients with CKD who need temporary haemodialysis have to have indwelling catheters. The catheters used are either temporary or permacath (A permacath is a piece of plastic tubing very similar to jugular catheter used for haemodialysis). The issues with these catheters are stenosis of central vein especially subclavian. Central venous stenosis leads to impairment in optimal dialysis. We report two cases of central venous stenosis in which patients presented with pain and oedema of the arm. Venogram showed totally occluded right subclavian vein and left innominate vein. Venoplasty was done which on followup showed a normalization of arm and resumption of dialysis through AV fistula.

Keywords: Central Venous Stenosis, AV (Arteriovenous) Fistula and Venoplasty.

Introduction

Among all chronic ailments, chronic kidney disease (CKD) is a worldwide problem. The prevalence of CKD was found to be 12.5% among Pakistani adults.¹ Patients with CKD indicated for dialysis undergo temporary haemodialysis with indwelling catheters waiting for AV fistula to mature.² In one of the studies done in Pakistan showed usage of central venous catheter access for haemodialysis was 74.2% through temporary catheter and 5.8% through permacath.³ The most common cause of AV fistula in patients with chronic haemodialysis other than AV fistula failure is central venous stenosis.

.....
Department of Cardiology, National Institute of Cardiovascular Diseases (NICVD), Karachi.

Correspondence: Parveen Akhtar. Email: p146499@hotmail.com

Most of the patients had previous placement of temporary catheter in central vein especially subclavian vein.^{4,5} For patients with haemodialysis incidence of central venous stenosis was reported to be 11 to 40%. In another reported study patients who underwent subclavian catheterization and with nonfunctional AV-fistula, 25% of patients had central venous stenosis of subclavian type.⁶

We present two case reports of central venous stenosis, one of right subclavian vein and the other left innominate vein. One of the first case reports in Pakistan.

Case-1

An 80 year old woman, diabetic, hypertensive, ischaemic heart disease with history of chronic kidney disease from

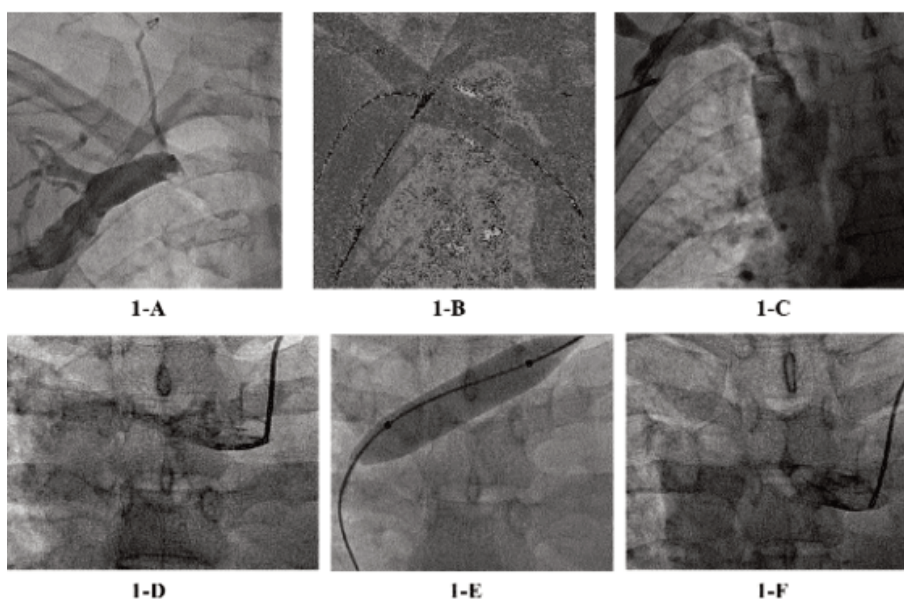


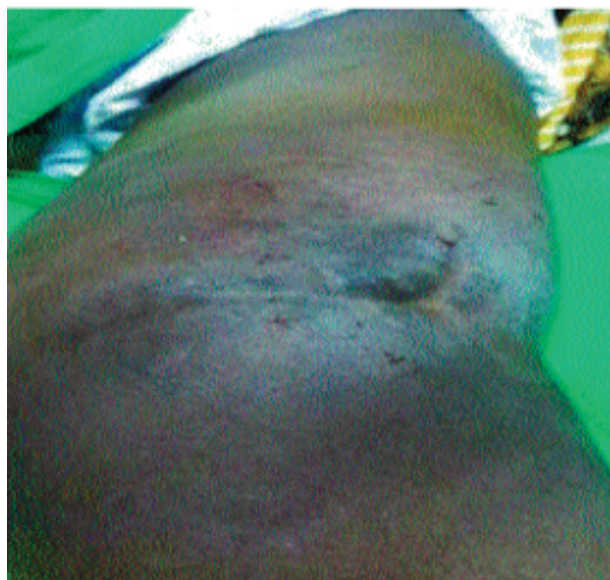Figure-1: Case-1 (1-A) Right Subclavian Venous Stenosis. (1-B): PTA to Subclavian Lesion. (1-C): Normal flow in Subclavian Vein upto Superior Venacava. Case-2 (1-D): Left In-nominate Venous Stenosis. (1-E): PTA to Left In-nominate Vein. (1-F): Normal flow in left In-nominate Vein.

last two years was seen on July 2014 and followed till June 2015 at National Institute of Cardiovascular Diseases (NICVD), Karachi. An AV-fistula was developed in the left forearm, which failed to function. So another AV-fistula

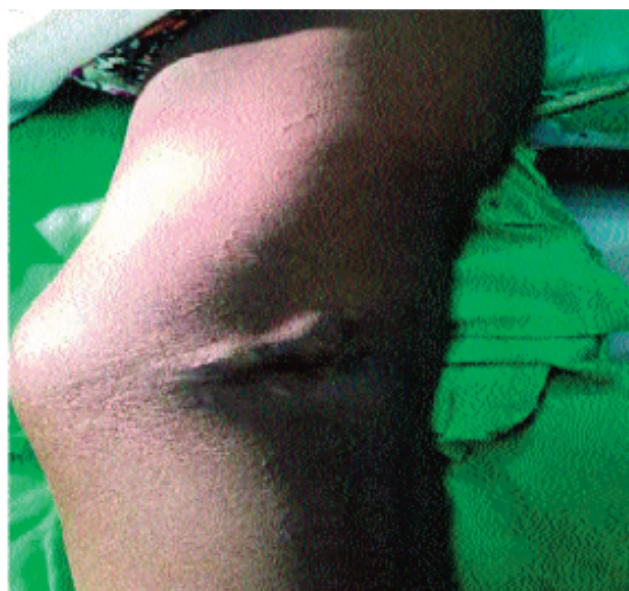was developed in the left wrist and then in the right wrist. Finally brachio-cephalic fistula was made on the right forearm. A temporary double lumen catheter was placed in the right subclavian vein for temporary dialysis for one month. Haemodialysis was started through right forearm fistula. After two months, the patient developed pain and oedema of right upper limb. Incomplete dialysis was carried out through AV-fistula. Ultrasound doppler showed no thrombus in AV-fistula. Venogram showed a totally occluded right subclavian vein. Right subclavian venoplasty was done with a 12x40 balloon (Boston scientific) by using a terumo wire for crossing the lesion and .035 Amplatz wire as rail road for balloon (Figure-1 A,B,C). Oedema and pain was relieved on third day and patient started regular haemodialysis through AV-fistula. After six months patient again developed pain and oedema in right upper limb. Venogram showed restenosis of subclavian vein which was again dilated with the same size balloon. She was intervened for the third time after 6months with similar symptoms. The patient died after three months due to cardiac event.

Case-2

A 39 year old woman, non-diabetic, hypertensive on haemodialysis through left brachio-basilic vein, was seen in November 2015, presented with history of pain and oedema of left arm after she had temporary catheter for dialysis. Venogram showed a left innominate vein stenosis. Venoplasty with a 10x40mm balloon was used (Figure-1 D,E,F). On the third day oedema and pain was reduced to normal level (Figure-2).



2-A



2-B

Figure-2: Case 2 (2-A and 2-B) Before and after PTA of Left Arm.

Discussion

Percutaneous transluminal angioplasty (PTA) of central venous stenosis provides excellent immediate results but long term patency reported to be 10-30% at one year and restenosis were reported.^{7,8} In our first case restenosis was found to be present after 6 months in which PTA was repeated while in second case no restenosis was observed at 6months follow up.

Stent implantation in cases where there is recurrence of central vein stenosis is indicated. Long term patency with stent implantation has been shown in cases with failed PTA.⁹ In a study no particular difference of primary patency between PTA and stent groups were found in follow up from 30 to 180 days.¹⁰ Secondary patency up to 360 days were also similar. In our first case repeated restenosis, stent implantation could have been a second option.

Most therapies of central vein stenosis are evolved as designed for management of arterial lesions. Number of studies for management of such lesions is lacking. Drug eluting stents, brachytherapy, cutting balloons may be an effective preventive strategies for central venous stenosis for optimal outcomes in patient with dialysis. Moreover avoiding and minimizing the placement of central venous catheter may prevent the issues of stenosis.¹¹

Conclusion

Subclavian catheter placement (temporary or permacath) lead to central venous stenosis that lead to arm swelling

and dysfunction of AV-fistula. Main stay of treatment is PTA or stent placement which can restore function of AV-fistula. Multiple PTA can be done to restore function of fistula.

Disclaimer: None.

Conflict of Interest: None.

Funding Support: None.

References

- Jessani S, Bux R, Jafar TH. Prevalence, determinants and management of chronic kidney disease in Karachi, Pakistan. A community based cross-sectional study. *BMC Nephrol* 2014; 15: 90.
- O Hare AM, Bertenthal D, Walter LC, Gang AX, Covinsky K, Kaufman JS. When to refer patients with chronic kidney disease for vascular access surgery. Should age be a consideration. *Kidney Int* 2007; 71: 555-61.
- Mahmood SN, Mukhtar KN, Iqbal N, Umair SF. Predialysis care & types of vascular access employed in incident hemodialysis patients: A study from Pakistan. *Pak J Med Sci* 2013; 29: 828-31.
- Lumsden AB, MacDonald MJ, Isikar H, Martin LG, Kikeri D, Harker LA, et al. Central venous stenosis in the hemodialysis patient: Incidence and efficacy of endovascular treatment. *Cardiovasc Surg* 1997; 5: 504-9.
- Schwab S, Quarles D, Middleton J, Cohan R, Saeed M, Dennis V. Hemodialysis-associated subclavian vein stenosis. *Kidney Int* 1998; 33: 1156-9.
- Agarwal AK, Patel BM, Farhan NJ. Central venous stenosis in hemodialysis patients is a common complication of ipsilateral central vein catheterization. *J Am Soc Nephrol* 2004; 15: 368A-9.
- Sprouse LR 2nd, Lesar CJ, Meier GH 3rd, Parent FN, Demasi RJ, Gayle RG, et al. Percutaneous treatment of symptomatic central venous stenosis. *J Vasc Surg* 2004; 39: 578-82.
- Quinn SF, Schuman ES, Demow TA, Standage BA, Ragsdale JW, Green GS, et al. Percutaneous transluminal angioplasty versus endovascular stent placement in the treatment of venous stenosis in patients undergoing hemodialysis: Intermediate result. *J Vasc Interv Radiol* 1995; 6: 851-5.
- Hage P, Vorwerk D, Piroth W, Schurmann K, Gunther RW. Treatment of hemodialysis related central venous stenosis or occlusion: Results of primary Wallstent placement and follow up in 50 patients. *Radiology* 1999; 212: 175-80.
- Maya I, Allon M. Retrospective evaluation of central venous stenosis treatment: Stents vs angioplasty. *NKF Spring Clinical meetings Abstract*, A43, 2006.
- Shi YX, Ye M, Liang W, Zhang H, Zhas YP, Zhang JW. Endovascular treatment of Central venous stenosis & obstruction in hemodialysis patients. *China Med J (Eng)* 2013; 126: 426-30.