

## Transcranial approach to craniopharyngiomas; review of management and outcomes

Muhammad Junaid,<sup>1</sup> Syed Sarmad Bukhari,<sup>2</sup> Muhammad Azmat Khan,<sup>3</sup> Mamoon-Ur-Rashid<sup>4</sup>

### Abstract

Craniopharyngiomas are rare tumours of the central nervous system. Their successful treatment is marred by a high rate of recurrence and postoperative complications. Their occurrence is sufficiently rare to merit treatment at specialized high volume centers. We have described our experience with these tumours because we feel that published literature is rare from our region. We treated 7 patients during this period. Their complete history was taken and full neurological examination was performed. Scans included a plain head CT and an MRI scan with contrast. Follow up was done at 2 weeks, 1 month, 3 months, 6 months, 1 year and 2 year following surgery. The outcome in all patients was classified as according to the Karnofsky outcome scale for brain tumours. Craniopharyngiomas are a rare and challenging form of tumour to treat due to its close proximity to vital structures. Treatment is usually multi-disciplinary at reducing recurrence and maintaining quality of life.

**Keywords:** Craniopharyngioma, Transcranial, Surgery.

### Introduction

Craniopharyngiomas are very rare tumours of the central nervous system. They were named by Harvey Cushing and described as being derived from "epithelial rests ascribable to an imperfect closure of the hypophysial or craniopharyngeal duct".<sup>1</sup> Since this early description by Cushing, the treatment strategies for these tumours have undergone significant advancement. We have unearthed significant insight into the embryology, pathophysiology, diagnosis, treatment and prognosis of this rare tumour. These are graded as WHO grade I and classified as giant when exceeding in diameter greater than 5 cm.<sup>2</sup>

The annual incidence of Craniopharyngiomas is reported between 0.5 and 2.5 new cases per million per year with a much higher incidence in the paediatric population (5.25 cases per million). The two subtypes are adamantinomatous and papillary with the prior having a

bimodal distribution and the latter occurring exclusively in adults. Sex predilection is often not demonstrable. In a study from Islamabad, there were 10 cases reported from a 4 year and 8 months period. All of these were in the paediatric population.<sup>3</sup>

The treatment options for these tumours include observation, surgery with gross total or near total excision by craniotomy or transnasaltransphenoidal endoscopic, radiotherapy with conventional external beam, conformal or stereotactic, cyst chemotherapy with bleomycin and interferon and systemic chemotherapy with interferon alfa - 2a.<sup>4</sup> The variety of treatment options available is a testament to the difficulty in achieving complete cure with a single modality alone.

In our local experience there are no published reports on craniopharyngioma outcomes from the region of Peshawar. Only papers citing the relative frequencies of these tumours amongst intracranial neoplasms are available. We will attempt to give a succinct view of our experience with these tumours. Consent was taken from the patients/family prior to writing this manuscript.

### Case Series

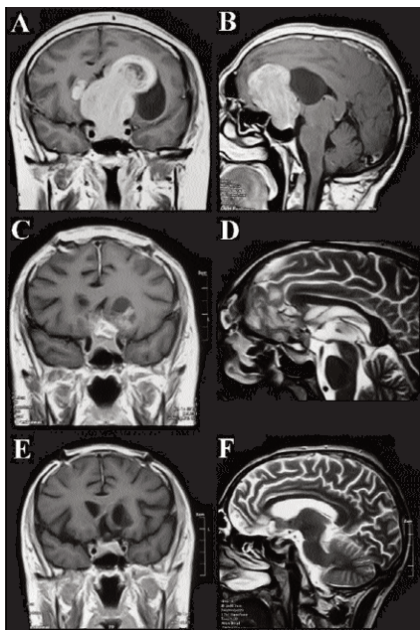
This is a retrospective chart review study of patients with biopsy proven craniopharyngiomas who underwent surgery at our center from 2011 to 2015. We treated 7 patients during this period. Their complete history was taken and full neurological examination was performed. Scans included a plain head CT and an MRI scan with contrast. Follow up was done at 2 weeks, 1 month, 3 months, 6 months, 1 year and 2 year after surgery. Follow up MRI was done at 1 month, 6 months, 1 year and 2 years. All patients received external beam radiotherapy at a referral center with doses varying from 6 to 12 Gy. A total of seven patients were operated. Their individual characteristics are given in Table-1. The outcome in all patients was classified as according to the Karnofsky outcome scale for brain tumours. None of our patients developed postoperative diabetes insipidus. One patient presented with diabetes insipidus which did not resolve postoperatively. This was probably due to damage to hypothalamus by the tumour. After 1 year, recurrence occurred in 1 patient who was lost to follow up and did

<sup>1</sup>Bahria University Medical and Dental College, Karachi, <sup>2,4</sup>Khyber Teaching Hospital, <sup>3</sup>Combined Military Hospital, Peshawar.

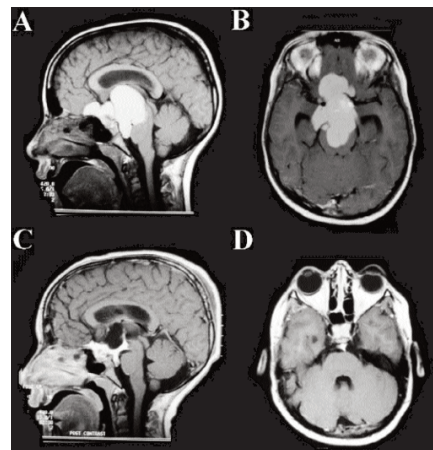
**Correspondence:** Syed Sarmad Bukhari. Email: sarmadbukhari@gmail.com

**Table-1:** Patient characteristics at presentation, clinical findings and outcomes.

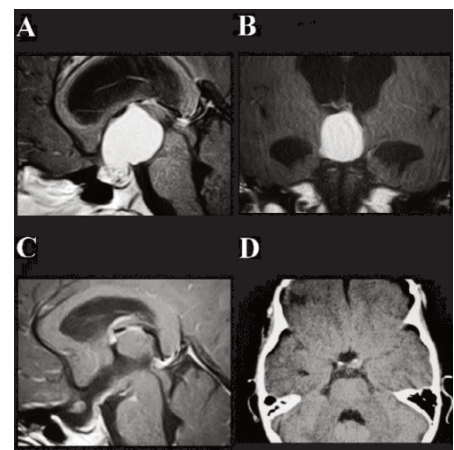
Patient Number	Age	Sex	Presenting Complaints	Clinical findings	Investigations performed and findings	Intervention	Histopathological diagnosis	Outcome
1	6 years	Female	1 month of undiagnosed headache	None	MRI and CT scan of brain with contrast showed a cystic space occupying lesion in the suprasellar area	Craniotomy with gross total excision and right sided VP shunt placement	Craniopharyngioma	Outcome Score 70 (cares for self: unable to carry on normal activity or to do active work)
2	9 years (Figure-2)	Male	Loss of consciousness	Bilateral papilloedema	MRI and CT with contrast showing space occupying sellar and suprasellar lesion	Craniotomy and gross total excision	Craniopharyngioma	Score 60 (requires occasional assistance: cares for most needs)
3	40 years (Figure-1)	Male	Visual deterioration and complete loss of vision in right eye	Bilateral papilloedema	MRI and CT with contrast showing solid space occupying lesion in the parasellar region	Craniotomy and near total excision	Craniopharyngioma	Score 80 (normal activity with effort: some signs of symptoms)
4	20 years	Male	Headache	Bilateral papilloedema	MRI and CT with contrast showing sellar space occupying lesion	Craniotomy and gross total excision	Craniopharyngioma	Score 70 (cares for self: unable to carry on normal activity or to do active work)
5	10 years (Figure-3)	Male	Headache, vomiting and visual deterioration for the last one month	Bilateral papilloedema	MRI and CT brain with contrast showing solid space occupying lesion in sellar area	Craniotomy and gross total excision	Craniopharyngioma	Score 70 (cares for self: unable to carry on normal activity or to do active work)
6	13 years	Male	Poor school performance, headache and visual deterioration for one year	Bilateral papilloedema	MRI and CT scan of brain with contrast showed a cystic space occupying lesion in the suprasellar area	Craniotomy and gross total excision	Craniopharyngioma	Score 60 (requires occasional assistance: cares for most needs)
7	10 years	Male	Poor school performance, headache and visual deterioration for one year	Bilateral papilloedema	MRI and CT scan of brain with contrast showed a cystic space occupying lesion in the suprasellar area	Craniotomy and near total excision	Craniopharyngioma	Score 60 (requires occasional assistance: cares for most needs)



**Figure-1**



**Figure-2**



**Figure-3**

**Figure-1:** MRI scans from a 40 year old male patient with craniopharyngioma involving the suprasellar area with downward displacement of the sellaturcica. The tumor had extended superiorly and anterior.

**Figure-2:** MRI scan of a 9 year old, male child with cystic craniopharyngioma. 2a and 2b are preoperative MRI images in the sagittal and axial cut showing a large cystic craniopharyngioma with some anter.

**Figure-3:** 10 year old boy with a solid craniopharyngioma. 3a and 3b are preoperative images showing significant hydrocephalus development due to direct pressure on the aqueduct of Sylvius in this locate.

not seek radiotherapy. After 2 years recurrence occurred in none of the other patients.

## Discussion

The location of these tumours around vital structures gives rise to the innate difficulty in complete removal without causing additional deficits. An important example of this would be the overwhelming majority of patients who develop central diabetes insipidus following excision. This is due to the close relation of the hypothalamus to this area. Preoperatively 17%-27% of children with craniopharyngiomas have been reported to present with CDI while the incidence is close to 60% postoperatively. In our study, all of our patients developed CDI which was managed accordingly with fluid resuscitation only.<sup>5</sup> The difficulty in approaching the tumour and its possible extensions makes management fraught with difficulties. The key to successfully treating craniopharyngiomas lies in methodical planning of your approach and technical expertise of this area of the brain.<sup>6,7</sup>

The incidence of craniopharyngiomas in Pakistan is currently not reported owing to the paucity of published material and the general lack of a culture where surgeons are encouraged to report their work. The worldwide incidence has been cited as 5-10% of paediatric brain tumours and 1.2-4% of adult brain tumours with no sex or racial predilection. Retrospective studies from Pakistan have reported male to female ratios varying from 2.5 to 1.0. However these studies have been limited to being local experiences with a small number of patients. The authors believe that larger representative samples were considered, the sex predilection would disappear.<sup>3</sup>

Bartlett treated 11 patients with regular neurological and endocrine review and 5 of these patients did not require treatment for the next 15 years.<sup>8</sup> Surgery remains the mainstay of treatment in most selected cases. Total excision is carried out wherever possible but this usually may not be the case due to involvement of vital structures for tumours that involve the hypothalamus. A variety of approaches are available to reach this area with the most suitable one selected depending on the size and extension of the tumour. These include trans-lamina terminalis, bifrontal basal interhemispheric approach, transsphenoidal and extended transsphenoidal, pterional, orbitozygomatic, interhemispheric transcallosal and the transcortical/trans ventricular approach. Each of the approaches has its own pros and cons and has to be considered in the context of the exposure it provides. In our series we were able to achieve gross total resection in 5 patients and near total resection in 2 patients. Following

gross resection, recurrence rates have been quoted between 0-50% in different series after 7-10 years. This demonstrates the high rate of complete resection failure in a fair proportion of patients. Several surgeons make a case for aggressive surgery regardless but the associated morbidity and mortality weaken this argument and suggest combination with radiotherapy to improve outcomes.<sup>9,10</sup> Radiotherapy is currently one of the most important tools used in Pakistan and the world over to manage craniopharyngiomas. Saleem et al have described their pioneering results with gamma knife surgery in Karachi, Pakistan. They have reported a response rate of 77% and 88.5% respectively and the clinical outcome was considered excellent in 10 patients, good in 15, fair in 6, and poor in 4 according to a scale described by Kobayashi et al.<sup>11,12</sup> This series also reports no pituitary dysfunction following treatment. We referred all patients to radiotherapy.

Researchers have noticed significant difficulties with occupational, academic and social functioning in patients following surgery which have been attributed to brain injury. Preece D et al<sup>13</sup> have described an excellent account of the neuropsychological effects of treatment in patients with craniopharyngiomas. Some of these deficits remained static while others improved over time. This account would suggest that the neuropsychological aspects of treatment will be an important consideration in the times to come.<sup>13</sup>

## Conclusion

Craniopharyngiomas are a rare and challenging form of tumour to treat due to its close proximity to vital structures. Treatment is usually multi-disciplinary at reducing recurrence and maintaining quality of life. A combined registry of these patients needs to be set up in Pakistan in order to better treat them. This would improve follow up and reduce the exorbitant long term loss to follow up seen in our population.

## Limitations

The study is limited by its small sample size and relatively short term follow up when compared with much larger international trials.

**Disclaimer:** The study was previously accepted in abstract form for the 85th Annual Meeting of the American Association of Neurological Surgeons at Los Angeles, USA. It was presented as an electronic poster on April 22-26, 2017.

**Conflicts of Interest:** None.

**Funding Sources:** None.

## References

1. Winn H, Winn H. Youman's Neurological Surgery. 6th ed. Philadelphia: Saunders, 2004.
  2. Pascual JM, Prieto R, Dufourny IC, Simoes RG, Carrasco R. Hypothalamus-referenced classification for craniopharyngiomas: evidence provided by the endoscopic endonasal approach. *Neurosurg Rev* 2013; 36: 337-9.
  3. Bilqees F, Samina K, Mohammad T, Khaleeq-uz-Zamaan. Morphological pattern and frequency of central nervous system tumours in children. *J Ayub Med Coll Abbottabad* 2016; 28: 44-6.
  4. Jeswani S, Nuño M, Wu A, Bonert V, Carmichael JD, Black KL, et al. Comparative analysis of outcomes following craniotomy and expanded endoscopic endonasal transsphenoidal resection of craniopharyngioma and related tumours: a single-institution study. *J Neurosurg* 2016; 124: 627-38.
  5. Edate S, Albanese A. Management of electrolyte and fluid disorders after brain surgery for pituitary/suprasellar tumours. *Horm Res Paediatr* 2015; 83: 293-301.
  6. Campbell PG, McGettigan B, Luginbuhl A, Yadla S, Rosen M, Evans JJ. Endocrinological and ophthalmological consequences of an initial endonasal endoscopic approach for resection of craniopharyngiomas. *Neurosurg Focus* 2010; 28: E8.
  7. Xing H, Xing H, Hui P, Yang B. Removal of craniopharyngioma via fronto-basal interhemispheric approach. *Oncol Lett* 2016; 12: 147-9.
  8. Bartlett JR. Craniopharyngiomas—a summary of 85 cases. *J Neurol Neurosurg Psychiatry* 1971; 34: 37-41.
  9. Hoffman HJ, De Silva M, Humphreys RP, Drake JM, Smith ML, Blaser SI. Aggressive surgical management of craniopharyngiomas in children. *J Neurosurg* 1992; 76: 47-52.
  10. Hoffmann A, Warmth-Metz M, Gebhardt U, Pietsch T, Pohl F, Kortmann RD, et al. Childhood craniopharyngioma - changes of treatment strategies in the trials KRANIOPHARYNGEOM 2000/2007. *Klin Paediatr* 2014; 226: 161-8.
  11. Kobayashi T, Kida Y, Mori Y, Hasegawa T. Long-term results of gamma knife surgery for the treatment of craniopharyngioma in 98 consecutive cases. *J Neurosurg* 2005; 103(6 Suppl): 482-8.
  12. Saleem MA, Hashim AS, Rashid A, Ali M. Role of gamma knife radiosurgery in multimodality management of craniopharyngioma. *Acta Neurochir Suppl* 2013; 116: 55-60.
  13. Preece D, Allan A, Becerra R. A case study of the neuropsychological outcomes following microsurgery, conventional radiotherapy and stereotactic radiotherapy for an adult's recurrent craniopharyngioma. *Brain Inj* 2016; 30: 104-11.
-