

## Caught in the act — Migration of a large right atrial thrombus to pulmonary artery during transthoracic echocardiography — A case report

Bilal Hussain,<sup>1</sup> Fateh Ali Tipoo Sultan,<sup>2</sup> Talha Shahzad,<sup>3</sup> Sumaira Punjani<sup>4</sup>

### Abstract

In cases of pulmonary embolism, the visualization of a free-floating right heart thrombus on conventional transthoracic echocardiography is extremely rare. Even rarer is an echocardiographic recording of migration of a free-floating clot from the right heart into the pulmonary vasculature leading to pulmonary embolism. We present a unique case of an elderly man who presented with dyspnoea, in whom a routine 2-D bed side transthoracic echo recorded the live transit of a free floating thrombus from the right heart into the pulmonary artery resulting in pulmonary embolism. The patient remained haemodynamically stable and was managed with anticoagulation. Our case objectively highlights the rare occurrence of free floating right heart thrombi and their association with pulmonary embolism and also focuses on the options of management of such thrombi.

**Keywords:** Case Report, Echocardiography, Pulmonary Embolism, Thrombosis.

### Introduction

The visualization of a free-floating right heart thrombus in cases of acute pulmonary embolism is a rare phenomenon.<sup>1,2</sup> A high incidence of in-hospital mortality is reported in patients with free floating right heart thrombi due to sudden pulmonary embolism.<sup>3</sup> Thus, right heart thrombus is considered a therapeutic emergency due to risk of sudden death.<sup>4-6</sup>

In Pakistan, free floating thrombi remain largely under diagnosed and are likely mistaken for intracardiac structures. The objective visualization and transthoracic echocardiographic recording of the embolization of a free floating right heart clot to the pulmonary vasculature is unique and has never been described from Pakistan. We present a unique case of an elderly man who presented with dyspnoea, in whom a routine 2-D bed side transthoracic echo recorded the live transit of a thrombus

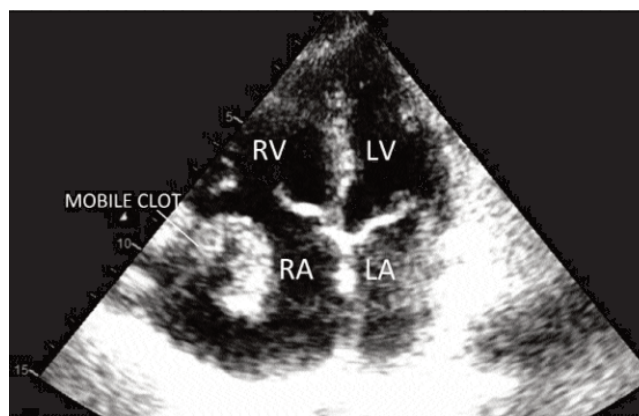
from the right heart into the pulmonary artery, resulting in pulmonary embolism that was managed successfully with anticoagulation.

### Case Report

A 70 year old man presented to the Emergency Department of The Aga Khan University Hospital Karachi in December 2015 with symptoms of worsening shortness of breath, cough and purulent sputum. Clinical examination revealed blood pressure of 118/60 mmHg, irregular pulse of 130 beats per min, oxygen saturation of 92% on 2 litres of oxygen and crepitations in the upper left lung field. He was admitted with the provisional diagnosis of community acquired pneumonia and managed with broad spectrum antibiotics.

His ECG showed Atrial Fibrillation with rapid ventricular rate. Laboratory investigations showed haemoglobin of 14.0 mg/dl, Total Leucocyte Counts of 12.8x10<sup>9</sup> per litre with 83% neutrophils, platelets of 79x10<sup>9</sup> per litre and serum creatinine of 1.2 mg/dl.

An echocardiogram was requested to assess the cardiac function. Transthoracic echocardiogram was done on portable GE Vivid S6 machine that showed dilated right

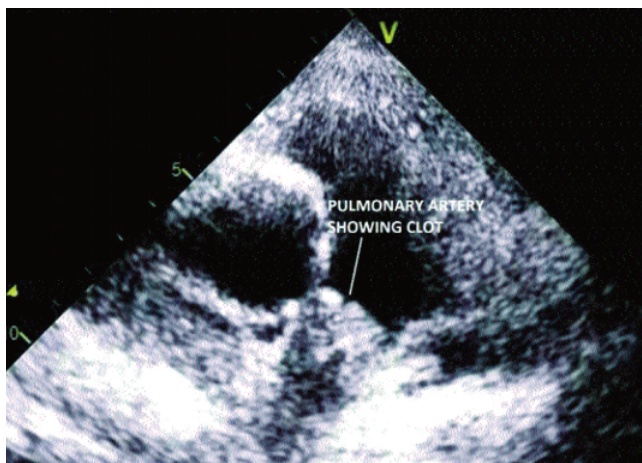


Labelled in the figure are: RV: Right Ventricle; RA: Right Atrium; LV: Left Ventricle; LA: Left Atrium.

**Figure-1:** 2-D echo image showing the apical four chamber view of the heart. An echogenic, large, free floating serpentine mass is seen in right atrium consistent with clot.

.....  
<sup>1</sup>Resident, Adult Cardiology, <sup>2</sup>Section of Cardiology, Department of Medicine, <sup>3</sup>Section of Pulmonary Medicine, Department of Medicine, <sup>4</sup>Section of Cardiology, Department of Medicine, Aga Khan University Hospital, Karachi.

**Correspondence:** Bilal Hussain. Email: bilal\_observer@hotmail.com



**Figure-2:** 2-D echo image showing the para-sternal short axis view at aortic valve level. The clot is visualized lodged in the pulmonary artery causing pulmonary embolism.

atrium with a very large (6x6cm), mobile, serpentine, echogenic density in the right atrium (Figure-1) consistent with thrombus. Right and left ventricular systolic functions were normal. Severe tricuspid regurgitation was noted with peak pressure gradient of 60 mmHg. During the echocardiographic study in the same setting, it was observed that the large, mobile thrombus had disappeared from the right atrium and was found lodged in the right pulmonary artery (Figure-2).

The patient remained haemodynamically stable during this period and did not show any decompensation clinically. Surgery and catheter based aspiration of the clot was offered but declined by the patient. Thrombolysis was considered as an option if the patient developed haemodynamic instability, yet the patient was reluctant for thrombolysis because of high risk of bleeding in view of low platelet counts. The patient agreed for and was started on therapeutic anticoagulation initially with low molecular weight heparin for two days and then switched to warfarin. He had no major bleeding on anticoagulation and his platelet count remained static.

The patient was discharged on warfarin in a stable condition and was doing fine on telephonic follow up.

## Discussion

In this report, we present a unique case of large mobile right atrial thrombus with witnessed migration to the pulmonary artery on echocardiogram, resulting in pulmonary embolism. Free-floating right heart thrombi can be observed in patients with pulmonary embolism; however, it is a rarity to observe thrombus migration from the right heart to pulmonary artery during

echocardiography.

Echocardiography has remained an important tool for the diagnosis of pulmonary embolism. It allows for a rapid bedside, noninvasive investigation in an intensive care setting. The common echo findings in cases of suspected pulmonary embolism include right ventricular dilatation and dysfunction with increased pulmonary artery pressures.

In case of pulmonary embolism, echocardiography may detect right heart thrombi. Morphologically, these right heart thrombi can be divided into two types, A and B. Type A thrombi mostly represent peripheral venous clots which lodge into the right heart, they have a serpentine shape and are extremely mobile. Type B thrombi have broad-based attachments to the right atrial or ventricular wall and are less mobile.<sup>6</sup>

A possible explanation for the under diagnosis of free floating right heart thrombi is their resemblance with other intracardiac structures. These thrombi can be easily mistaken for other structures within the right heart and need to be differentiated from congenital structures and acquired conditions. These thrombi closely mimic other right heart structures such as the chiari network, persistent eustachian or thebesian valves and pathological structures such as vegetations and intracardiac tumours.<sup>7</sup> In such cases transesophageal echocardiography should be considered.

On echocardiography, a prevalence of 3.7% for free floating right heart thrombi has been reported in haemodynamically stable patients<sup>2</sup> whereas, a prevalence of floating right heart thrombi as high as 18% was reported in a series of haemodynamically unstable patients undergoing echocardiography.<sup>8</sup> These thrombi can embolize causing compromise of pulmonary circulation leading to severe hypoxia and sudden cardiac death. Thus, they are considered to be an extreme therapeutic emergency.<sup>9</sup> Clinical consequences of such thrombus transition tend to depend not only on clot size but also on overall clot burden. The overall mortality rate in patients with right heart thrombi has been reported to be as high as 20%.

There is no consensus on the management of these thrombi and the therapeutic option is usually decided by the haemodynamic status of the patient. Surgery,<sup>10</sup> thrombolysis,<sup>11</sup> percutaneous aspiration and anticoagulation<sup>12</sup> all have been proposed as options of treatment. There exists no consensus on management and the choice of therapy is dictated by the haemodynamic parameters of the patients. In

haemodynamically unstable patients, both surgery and thrombolysis appear beneficial. Chartier et al. reported that there was no significant difference between these therapeutic approaches in terms of in-hospital mortality.<sup>3</sup>

In patients that are haemodynamically stable, another option of treatment is systemic anticoagulation.<sup>12</sup> The risk of using anticoagulation therapy alone is of clot embolization to the already compromised pulmonary circulation. However, successful treatment of type A right heart thrombus with anticoagulation alone has been reported.<sup>13</sup> In our case, the patient had no follow up after discharge and thus, no repeat investigations such as an echo or CT scan could be done to document complete successful treatment of the pulmonary embolism via anticoagulation alone. However, on telephonic follow up he was clinically stable and was making good progress.

### Conclusion

Though the occurrence of free floating right heart thrombi and their association with pulmonary embolism have been reported, an echocardiographic recording of migration of a free-floating clot from the right heart into the pulmonary vasculature leading to pulmonary embolism is a unique objective evidence of this phenomenon. The management of such right heart thrombi remains debatable with management dictated by haemodynamic status of the patient. Currently options of treatment include surgical treatment, thrombolysis, anticoagulation and percutaneous aspiration. Further studies in this regard are required to establish guidelines for management of such patients.

**Informed Consent:** Written informed consent of the patient was obtained.

**Disclaimer Statement:** None.

**Conflict of Interest:** None to declare.

**Funding Disclosure:** None to declare.

Approval from Department for Submission of case report: Obtained.

### References

1. Goldhaber SZ, Visani L, De Rosa M. Acute pulmonary embolism: clinical outcomes in the International Cooperative Pulmonary Embolism Registry (ICOPER). *Lancet* 1999; 353: 1386-9.
2. Torbicki A, Galié N, Covezzoli A, Rossi E, De Rosa M, Goldhaber SZ. Right heart thrombi in pulmonary embolism: results from the International Cooperative Pulmonary Embolism Registry. *J Am Coll Cardiol* 2003; 41: 2245-51.
3. Chartier L, Béra J, Delomez M, Asseman P, Beregi JP, Bauchart JJ, et al. Free-floating thrombi in the righthear: diagnosis, management, and prognostic indexes in 38 consecutive patients. *Circulation* 1999; 99: 2779-83.
4. Kanjirakadavath B, Krishnan MN, Vinayakumar D, Raju D, Nithin PG, Rajesh KF, et al. A floatingright heart thrombus in transit across tricuspid valve causing an endocardial friction rub. *Indian Heart J* 2013; 65: 457-9.
5. Redberg RF, Hecht SR, Berger M. Echocardiographic detection of transient right heart thrombus: now you see it, now you don't. *Am Heart J* 1991; 122: 862-4.
6. The European Cooperative Study on the clinical significance of right heart thrombi. European Working Group on Echocardiography. *Eur Heart J* 1989; 10: 1046-59.
7. Panidis IP, Kotler MN, Mintz GS, Ross J. Clinical and echocardiographic features of right atrial masses. *Am Heart J* 1984; 107: 745-58.
8. Casazza F, Bongarzone A, Centonze F, Morpurgo M. Prevalence and prognostic significance of right-sided cardiac mobile thrombi in acute massive pulmonary embolism. *Am J Cardiol* 1997; 79: 1433-5.
9. Chapoutot L, Nazeyrollas P, Metz D, Maes D, Maillier B, Jennesseaux C, et al. Floating right heart thrombi and pulmonary embolism: diagnosis, outcome and therapeutic management. *Cardiology* 1996; 87: 169-74.
10. Farfel Z, Shechter M, Vered Z, Rath S, Goor D, Gafni J. Review of echocardiographically diagnosed right heart entrapment of pulmonary emboli-in-transit with emphasis on management. *Am Heart J* 1987; 113: 171-8.
11. Pierre-Justin G, Pierard LA. Management of mobile right heart thrombi: a prospective series. *Int J Cardiol* 2005; 99: 381-8.
12. Agnelli G, Becattini C. Anticoagulant treatment for acute pulmonary embolism: a pathophysiology-based clinical approach. *Eur Respir J* 2015; 45:1142-9
13. Hinton JW, Lainchbury J, Crozier I. Right atrial mass-A venous thrombosis in transit. *NZ Med J* 2012; 125: 81-3.