

Graft and mesh use in vaginal surgery

Raheela Mohsin Rizvi, Novera Ghayoor Chughtai

Abstract

Pelvic organ prolapse and urinary incontinence are among the most common chronic disorders in women. These are common problems whose pathogenesis remains unclear. As life expectancy increases, significantly greater number of women now present with pelvic organ prolapse and urinary incontinence requiring surgical intervention. Currently, the lifetime risk of undergoing prolapse or continence surgery is one in 11, and up to 30% of patients will require repeat reconstructive surgery and repeat surgery for incontinence in 10%. In an attempt to improve surgical outcomes and to preserve vaginal capacity and coital function, a number of synthetic and biological prostheses have been developed. This review aims to look at the role of graft and mesh in vaginal surgery. We conducted a search for English-language articles published during 1997 to 2016, using MEDLINE, PubMed and United States' National Library of Medicine databases. We reviewed around 50 papers but referenced only 30 for this article. The literature review provided us a new insight regarding safety of mesh. Polypropylene mesh is safe for vaginal surgery if used by experienced surgeons. The safety of mesh becomes compromised in the hands of commercial surgical kit providers. All the new mesh tailored kits should undergo evidence-based trials and then can be safely used worldwide.

Keywords: Mesh, Graft, Pelvic organ prolapse, Urinary incontinence.

Introduction

Pelvic organ prolapse (POP) and urinary incontinence (UI) affect nearly one quarter of women in the United States (US) and it is estimated that stress urinary incontinence (SUI) alone results in more than \$12 billion in annual expenditures.¹ Although many non-surgical treatments exist, 11% to 19% of women undergo surgery.² However, even after surgery, up to one-third of women have recurrent symptoms and require an additional operative procedure.³ Surgical mesh has been promoted for the treatment of women with POP to improve long-term outcomes similar to mesh use for hernia repair, but during

last decade pharmaceutical-driven use of mesh kits brought some serious complication. In 2012, the US Food and Drug Administration (FDA) issued the first safety communication regarding serious complications associated with the use of trans-vaginal mesh for treatment of prolapse.⁴ In 2014, the FDA mandated premarket studies to evaluate the safety and effectiveness of vaginal mesh implants and, in January 2016, reclassified them as class III high-risk devices.⁵

There is a paucity of evidence regarding the use of mesh in POP repair⁶ and it has been recommended by American Urogynaecologic Society's guidelines developing committee⁷ that placement of vaginal mesh should only be performed by experienced, knowledgeable surgeons who track their outcomes and provide rigorous informed consent. In this article we will review the use of mesh in vaginal surgery along with its complications and latest recommendations.

Terminology

A brief description of the terminology used for pelvic organ prolapse and SUI is given below. This was given by joint committee of International Continence Society (ICS) and International Urogynaecological Association (IUGA) 2016.⁸

Urodynamic stress incontinence: involuntary leakage of urine during filling cystometry, associated with increased intra-abdominal pressure, in the absence of a detrusor contraction. In the circumstances where this diagnosis is only made when the POP is reduced, the additional term "occult" is appropriate.

Pelvic organ refers most commonly to the uterus and/or the different vaginal compartments and their neighbouring organs such as bladder, rectum or bowel.

POP Symptoms

Prolapse symptoms include a departure from normal sensation structure or function, experienced by the woman in reference to the position of her pelvic organs. Symptoms are generally worse in situations when gravity might make the prolapse worse (e.g., after long periods of standing or exercise) and better when gravity is not a factor e.g., lying supine.

.....
Aga Khan University Hospital, Karachi.

Correspondence: Raheela Mohsin Rizvi. Email: raheela.mohsin@aku.edu

Specific Defects Definitions

Anterior vaginal wall (compartment) prolapse is defined as observation of descent of the anterior vaginal wall (compartment). Most commonly this might represent bladder prolapse (cystocele). Higher stage anterior vaginal wall prolapse will generally involve descent of uterus or vaginal vault (if uterus is absent). Occasionally, there might be an anterior enterocele (hernia of peritoneum and possibly abdominal contents), most commonly after prior reconstructive surgery.⁸

Posterior vaginal wall (compartment) prolapse is defined as observation of descent of the posterior vaginal wall. Commonly, this would represent rectal protrusion into the vagina (rectocele). Higher stage posterior vaginal wall prolapse after prior hysterectomy will generally involve some vaginal vault (cuff scar) descent and possible enterocele formation. Enterocele formation can also occur in the presence of an intact uterus.⁸

Vaginal vault (cuff scar) prolapse is the observation of descent of the vaginal vault (cuff scar after hysterectomy).

Graft/Mesh Terminology

Due to increasing use of commercially available mesh kits, new terminology was developed by the joint committee of IUGA and ICS. The group defined various prostheses, grafts, complications related to their use by a standard terminology.^{9,10}

Prosthesis: a fabricated substitute to assist a damaged body part or to augment or stabilise a hypoplastic structure.

Mesh: A (prosthetic) network fabric or structure; open spaces or interstices between the strands of the net. The use of this term would be for POP surgery with synthetic materials.

Mesh kit: A set of articles or equipment utilised for POP surgery containing mesh with a system of trocars designed to achieve mesh fixation or allow mesh passage to or through specific areas within the pelvis.

Implant: A surgically inserted or embedded prosthesis or graft. (Explant: a surgically excised prosthesis or graft).

Tape (Sling): A flat strip of synthetic material. The use of this term would be for incontinence surgery with synthetic materials.

Graft: Any tissue or organ for transplantation. This term will be used to refer to biological materials inserted.

Autologous grafts: From patient's own tissues, e.g., rectus sheath or fascia lata.

Allografts: From postmortem tissue banks.

Xenografts: From other species, e.g. modified porcine dermis, porcine small intestine and bovine pericardium.

Trocar: A surgical instrument with either a pyramidal, conical or needle-type cutting or dissecting point.

Tissue: A collection of similar cells and the intercellular substances surrounding them.

Native: Pertaining to birth — "in situ" autologous.

Prominence: Parts that protrude beyond the surface with no epithelial separation.

Separation: Physically disconnected (e.g. vaginal epithelium).

Exposure: A condition of displaying, revealing, exhibiting or making accessible (e.g. a permanent suture visualised through separated vaginal epithelium).

Extrusion: Passage gradually out of a body structure or tissue (e.g. a permanent suture protruding into the vaginal cavity).

Perforation: Abnormal opening into a hollow organ or viscous.

Dehiscence: A bursting open, splitting or gaping along natural or sutured lines.

Sinus tract formation: (localised) formation of a fistulous tract towards vagina or skin, where there is no visible suture material in the vaginal lumen or overlying skin.

Granulation: Fleishy connective tissue projections on the surface of a wound, ulcer or inflamed tissue surface.

Ulcer: A lesion through the skin or a mucous membrane resulting from loss of tissue, usually with inflammation.

Site-specific defects and use of mesh

Surgical outcome in anterior vaginal wall defects

Cystocele, whether isolated or associated with apical and/ or posterior prolapse, is found in 80% of patients with genital prolapsed.³ The apical involvement of the prolapse is likely to be more common than observed, and combining sufficient support for the apex of the vagina is necessary to ensure durable surgical outcome. Using mesh instead of native tissues may lead to more efficient support of the pelvic floor. A randomised study on 389 women compared Prolift mesh kit with native tissue for

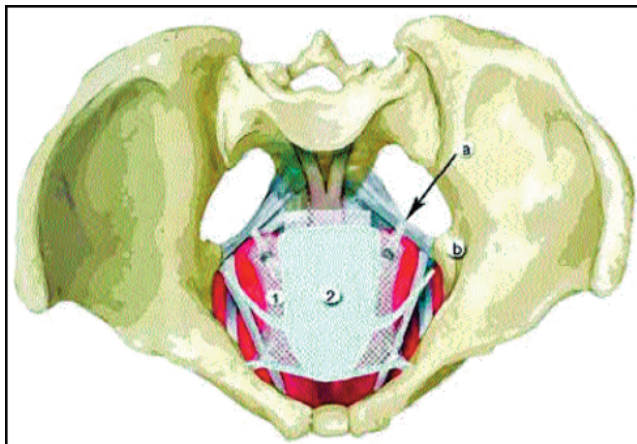


Figure: Shows the anatomical view of the two meshes Elevate and Perigee, used for correction of anterior and apical defects.

repair of cystocele by anterior colporrhaphy.¹¹ The study results revealed that mesh improved anatomical outcomes, but pain and sexual function were not statistically different between groups.

Trocar-based mesh kits like Elevate and Perigee are used to correct anterior and apical defects. The Elevate Ant mesh is fixed using hooks in the sacrospinous ligament on either side, unlike the Perigee mesh, which crosses through the obturator muscle just over the ischial spine (Figure).

A retrospective non-randomised study¹² compared the results of Elevate Ant™ single-incision mesh (Elevate Anterior group) in 84 patients and Perigee™ transvaginal mesh (Perigee group) in 42 patients. Follow-up at 1 and 2 years comprised objective Pelvic Organ Prolapse Quantification System (POP-Q) and subjective (Pelvic Floor Distress Inventory-20 [PFDI-20], Pelvic Floor Impact Questionnaire-7 [PFIQ-7], Pelvic Incontinence Sexual Questionnaire-12 [PISQ-12]) assessments. The primary end-point was objective success which was significantly better with the use of the Elevate Ant mesh with better apical correction at 2 years.

When different trocar-based kits were compared, anterior Prolift and Perigee did not show a difference for anatomic or subjective outcomes, mesh erosion or dyspareunia rates. The risk of repeat surgery for recurrent cases in 5 years showed that the use of mesh for anterior prolapse was associated with an increased risk of any repeat surgery, which was driven by surgery for mesh removal. Native tissue and vaginal mesh surgery had similar 5-year risks of surgery for recurrent prolapsed.¹³

In summary, the heterogeneous evidence comparing use

of various grafts and mesh with each other in repair of anterior vaginal wall prolapse limits our ability to draw conclusions. Like in other comparisons, synthetic non-absorbable mesh tends to provide superior outcomes compared with other surgical repairs.

Surgical Outcome in Posterior Vaginal Wall Defects

The current evidence suggests there is no difference in anatomic and quality-of-life outcomes when using synthetic absorbable mesh, synthetic non-absorbable mesh, or biologic graft compared with native tissue for transvaginal repair of posterior vaginal prolapse.⁶ One study by Paraiso et al. in 2006¹⁴ showed significantly higher anatomic failure rates after graft-augmented repair compared with native tissue posterior colporrhaphy, whereas the other found no difference between groups. Both studies showed no difference for symptomatic outcomes and no graft exposures. Anatomic failure with posterior repair is poorly defined and it occurs less often when polypropylene mesh was used to augment a transperineal levatorplasty.

A prospective multicentre study¹⁵ included 139 women with \geq stage 2 posterior vaginal prolapse and/or apical descent. These women were surgically treated using Elevate Apical and Posterior single-incision mesh system (SIMS) with IntePro Lite for POP repair. Surgical outcome was assessed by clinical examination and cure was defined as reduction in staging of prolapse. The primary endpoint was the percentage of patients with posterior and/or apical stage \leq I ("cure") at follow-up. Secondary endpoints included rate of mesh extrusion and disease-specific quality of life outcomes. One-year follow-up results showed objective posterior wall and apical cure rates to be 92.5 and 89.2%, respectively, with an extrusion rate of 6.5%.

Surgical Outcome in Vault Prolapse

Post-hysterectomy vaginal vault prolapse (PHVP) has a reported incidence of 0.36 to 3.6 per 1,000 woman years or a cumulative incidence of 0.5%.¹⁶ It is usually treated by abdominal Sacrocolpopexy or vaginal sacrospinous fixation (SSF) which is a conventional surgery for both prevention and treatment of vault prolapse. While Level I evidence supports the use of polypropylene mesh in terms of anatomical outcomes in abdominal sacrocolpopexy, evidence is less robust in supporting transvaginal mesh kits balancing anatomical successes.¹⁷ Recently there have been an increase in the use of mesh-based surgery using Prolift and Apogee mesh kits. Prolift aims at support of the weakened vaginal walls of the anterior and posterior compartments and suspension of

the apical compartment by means of a bilateral sacrospinous ligament fixation. By this method Delancy level 1 support¹⁸ is restored. An observational cohort study of 46 patients who had post-hysterectomy vault repair with Prolift showed an anatomic success rate of 91% at 12 months.¹⁹ Prolift has also been compared with SSF in a randomised controlled multicentre trial²⁰ which found that the prolapse recurrence rate was significantly higher at 12 months in the SSF group (39.4%) than in the mesh group (16.9%; $p=0.003$).

There is an overall high, short-term objective success rate (ranging from 87 to 95%) of the commonly used mesh kits in the treatment of apical vaginal prolapse. The mean objective success rate for correction of vault prolapse was highest in the Apogee group, and comparable results were obtained by procedures with the use of polypropylene mesh for apical support. These results are in accordance with the reported long-term success rates of vaginal sacrospinous fixation.²¹

Use of Mesh in Anti-Incontinence Surgery

About 41%²² of women with urinary incontinence report SUI as their primary symptom. The first line of management is behavioural modifications and pelvic floor muscle training, and once it fails, surgical treatment is the mainstay of treatment for SUI.

Midurethral synthetic slings (MUSS) have been established as the surgical intervention of first choice. All commercially available MUSS are made from uncoated, knitted, macroporous, type 1 polypropylene mesh. One of the first commercially available MUSS, known as the tension-free vaginal tape (TVT), is a retropubic sling and remains one of the most popular and widely studied midurethral sling.²³ Due to the recognised complications of retropubic mid-urethral slings such as voiding dysfunction and the potential for bowel, bladder, and vascular injuries, different methods of anatomic placement of the synthetic mesh were designed. In an effort to develop safer and less invasive passage of the trocar, or needle, through the retropubic region a transobturator tape was introduced²⁴ which passes through the obturator and puborectalis muscles, reproducing the natural suspension fascia of the urethra while preserving the retropubic space. Subsequent clinical trials have demonstrated that transobturator slings are associated with equivalent subjective cure rates to retropubic slings, with less associated voiding dysfunction and fewer bladder perforations²⁵ but with lower objective cure rates and greater risk of post-operative neurologic symptoms in the obturator region.

The popularity of MUSS has come under scrutiny with the

FDA's public health notification²⁶ and warning against some MUSS. While the FDA has not yet released its final recommendations on these devices it is recommended that selection of patients, procedure and type of mesh should always be performed by an experienced surgeon.

De-Novo Prolapse Formation in the Non-Affected Vaginal Compartment

A corrective procedure in one compartment might predispose for prolapse in a different anatomic compartment due to further progression of lack of pelvic support.²⁷ The surgical correction of vault prolapse by SSF has been associated with anterior vaginal defects which usually appear one year after surgery. A prospective study of 111 women aimed at the incidence of de novo anterior prolapse after correction of posterior compartment prolapse by mesh kit Elevate® Posterior. De novo anterior prolapse emerged in 3.2-15% of the women,²⁸ although it was found effective in terms of both objective and subjective outcomes.

Mesh Complications

Surgical treatment of POP and stress urinary incontinence (SUI) involves the use of synthetic materials. Placement of synthetic mesh into the vaginal wall, through either the vagina includes the risk of multiple complications.²⁹ The incidence of mesh-related infections and erosion range from 0 to 8%, and 0 to 33%, respectively, in published studies.³⁰

In contrast to mesh used for treating SUI, there is a paucity of data regarding long-term outcomes and complication rates of transvaginally placed mesh for treatment of pelvic organ prolapse. Sutures used to attach prolapse mesh to the vagina and the pelvic sidewall or sacrum act as point loads. Applying point loads during uniaxial loading results in out-of-plane deformation which results in mesh wrinkling, buckling, and/or folding.³¹ In addition to wrinkling with uniaxial loading, prolapse meshes exhibit a marked decrease in pore size and a loss in porosity. After exposing the transvaginal meshes Prolift and Prolift plus M to relatively small loads, Otto et al. detected a loss of porosity in both the arms and central body of the mesh.³² In a further assessment of prolapse meshes loaded in a sacrocolpopexy model, Barone et al. saw similar results.³³

The complications with the use of synthetic mesh occur due to its placement adjacent to the bladder and rectum involving extensive paravesical and pararectal dissection includes the passage of needles blindly through the obturator foramen or the ischioanal fossa which in turn increase the potential for immediate complications like

excessive bleeding, perforation of the bladder, rectum and blood vessels. Delayed complications include mesh erosion, severe mesh infections, deep fascial necrosis, fistulae and dyspareunia.

Mesh Complication with Commitant Vaginal Surgery

Surgery for SUI using midurethral sling along with vaginal hysterectomy and pelvic floor repair has shown no additional morbidity.² A prospective multicentre study³⁴ was conducted to evaluate the anatomical and functional results of a low-weight polypropylene mesh (Ugytex, Sofradim, Trévoux, France, distributed by Bard as Pelvitex) coated with an absorbable film. The Mesh was used for anterior (A), posterior (P) and combined AP repair. Concomitant procedures such as midurethral slings were performed in 70 cases, vaginal hysterectomy in 52, sacrospinous suspension in 13 and trachelectomy in 5 patients. During the one-year follow up, 9 vaginal erosions of the mesh occurred (6.3%). Five out of nine erosions occurred before 3 months, but the median follow-up for the diagnosis of erosion was 80 days (ranging from 38 to 380). Eight out of nine erosions occurred anteriorly, on the distal part of the vertical midline incision. Concomitant vaginal surgery increases the risk of mesh complications as six erosions occurred on the 57 patients with concomitant hysterectomy or trachelectomy (10.5%) and three on the 86 patients with uterine conservation or previous hysterectomy (3.5%) ($p=0.089$).

Conclusion

The heterogeneous evidence comparing use of various grafts and mesh with each other in repair of POP limits our ability to draw conclusions. Polypropylene mesh tends to provide superior outcomes compared with other surgical repairs. For posterior vaginal wall prolapse surgery the current evidence suggests there is no difference in anatomic and quality-of-life outcomes when using synthetic absorbable mesh, synthetic non-absorbable mesh, or biologic graft compared with native tissue for transvaginal repair of posterior vaginal prolapse. Due to close proximity of pelvic viscera like bladder and rectum it is recommended that selection of patients, procedure and type of mesh should always be performed by experienced surgeons. Surgical practices should not be pharmaceutical driven and choice of mesh and the procedure should be evidence based.

Disclaimer: None.

Conflict of Interest: None.

Source of Funding: None.

References

1. Chong EC, Khan AA, Anger JT. The financial burden of stress urinary incontinence among women in the United States. *Curr Urol Rep* 2011; 12: 358-62.
2. Mohsin Rizvi R, Akhtar M, Zuberi NF. A Review of Comparison of Complications of Vaginal Hysterectomy with and without Concomitant Surgery for SUI: A 5 Years' Experience at a Tertiary Care Hospital of Pakistan. *Obstet Gynecol Int* 2013; 2013, Article ID 540646
3. Olsen AL, Smith VJ, Bergstrom JO, Colling JC, Clark AL. Epidemiology of surgically managed pelvic organ prolapse and urinary incontinence. *Obst Gynecol* 1997; 89: 501-6.
4. Menchen LC, Wein AJ, Smith AL. An appraisal of the Food and Drug Administration warning on urogynecologic surgical mesh. *Curr Urol Rep* 2012; 13: 231-9.
5. U.S. Food and Drug Administration. FDA strengthens requirements for surgical mesh for the transvaginal repair of pelvic organ prolapse to address safety risks. [Online] [Cited 2016 Feb 2]. Available from URL: <http://www.fda.gov/NewsEvents/Newsroom/PressAnnouncements/ucm479732.htm>.
6. Schimpf MO, Abed H, Sanses T, White AB, Lowenstein L, Ward RM, et al. Graft and Mesh Use in Transvaginal Prolapse Repair: A Systematic Review. *Obstet Gynecol* 2016; 128: 81-91
7. American Urogynecologic Society's Guidelines Development Committee. Guidelines for privileging and credentialing physicians for sacrocolpopexy for pelvic organ prolapse. *Female Pelvic Med Reconstruct Surg* 2013; 19: 62-5.
8. Haylen BT, Maher CF, Barber MD, Camargo S, Dandolu V, Digesu A, et al. Erratum to: An International Urogynecological Association (IUGA)/International Continence Society (ICS) joint report on the terminology for female pelvic organ prolapse (POP). *Int Urogynecol J* 2016; 27: 655-84.
9. Haylen BT, Freeman RM, Swift SE, Cosson M, Davila GW, Deprest J, et al; International Urogynecological Association; International Continence Society; Joint IUGA/ICS Working Group on Complications Terminology. An International Urogynecological Association (IUGA)/International Continence Society (ICS) joint terminology and classification of the complications related directly to the insertion of prostheses (meshes, implants, tapes) and grafts in female pelvic floor surgery. *Neurourol Urodyn* 2011; 30: 2-12.
10. Haylen BT, Freeman RM, Lee J, Swift SE, Cosson M, Deprest J, et al; International Urogynecological Association; International Continence Society. International Urogynecological Association (IUGA)/International Continence Society (ICS) joint terminology and classification of the complications related to native tissue female pelvic floor surgery. *Neurourol Urodyn* 2012; 31: 406-14.
11. Altman D, Väyrynen T, Engh ME, Axelsen S, Falconer C. Anterior colporrhaphy versus transvaginal mesh for pelvic-organ prolapse. *N Engl J Med* 2011; 364: 1826-36.
12. Lamblin G, Gouttenoire C, Panel L, Moret S, Chene G, Courtieu C. A retrospective comparison of two vaginal mesh kits in the management of anterior and apical vaginal prolapse: long-term results for apical fixation and quality of life. *Int Urogynecol J* 2016; 27: 1847-55.
13. Funk MJ, Visco AG, Weidner AC, Pate V, Wu JM. Long-term outcomes of vaginal mesh versus native tissue repair for anterior vaginal wall prolapse. *Int Urogynecol J* 2013; 24: 1279-85.
14. Paraiso MF, Barber MD, Muir TW, Walters MD. Rectocele repair: a randomized trial of three surgical techniques including graft augmentation. *Am J Obstet Gynecol* 2006; 195: 1762-71.
15. Lukban JC, Roovers JP, VanDrie DM, Erickson T, Zylstra S, Patel MP, et al. Single-incision apical and posterior mesh repair: 1-year prospective outcomes. *Int Urogynecol J* 2012; 23: 1413-9.
16. Freeman RM, Pantazis K, Thomson A, Frappell J, Bombieri L, Moran

- P, et al. A randomised controlled trial of abdominal versus laparoscopic sacrocolpopexy for the treatment of post-hysterectomy vaginal vault prolapse: LAS study. *Int Urogynecol J* 2013; 24: 377-84.
17. Maher C, Feiner B, Baessler K, Christmann-Schmid C, Haya N, Marjoribanks J. Transvaginal mesh or grafts compared with native tissue repair for vaginal prolapse. *Cochrane Database Syst Rev* 2016; 2: CD012079.
 18. DeLancey JO. Fascial and muscular abnormalities in women with urethral hypermobility and anterior vaginal wall prolapse. *Am J Obstet Gynecol* 2002; 187: 93-8.
 19. Milani AL, Withagen MI, Vierhout ME. Trocar-guided total tension-free vaginal mesh repair of post-hysterectomy vaginal vault prolapse. *Int Urogynecol J* 2009; 20: 1203-11.
 20. Halaska M, Maxova K, Sottner O, Svabik K, Mlcoch M, Kolarik D, et al. A multicenter, randomized, prospective, controlled study comparing sacrospinous fixation and transvaginal mesh in the treatment of posthysterectomy vaginal vault prolapse. *Am J Obstet Gynecol* 2012; 207: 301
 21. Feiner B, Jelovsek JE, Maher C. Efficacy and safety of transvaginal mesh kits in the treatment of prolapse of the vaginal apex: a systematic review. *BJOG: Int J Obstet Gynaecol* 2009; 116: 15-24.
 22. Jokhio AH, Rizvi RM, Rizvi J, Macarthur C. Urinary incontinence in women in rural Pakistan: prevalence, severity, associated factors and impact on life. *BJOG: Int J Obstet Gynaecol* 2013; 120: 180-6.
 23. Novara G, Artibani W, Barber MD, Chapple CR, Costantini E, Ficarra V, et al. Updated systematic review and meta-analysis of the comparative data on colposuspensions, pubovaginal slings, and midurethral tapes in the surgical treatment of female stress urinary incontinence. *Eur Urol* 2010; 58: 218-38.
 24. Delorme E. [Transobturator urethral suspension: mini-invasive procedure in the treatment of stress urinary incontinence in women]. *Prog Urol* 2001; 11: 1306-13.
 25. Rothschild JG, Dmochowski RR. Mesh for Stress Incontinence. *Current Bladder Dysfunction Reports* 2012; 7: 210-4.
 26. Murphy M, Holzberg A, van Raalte H, Kohli N, Goldman HB, Lucente V. Time to rethink: an evidence-based response from pelvic surgeons to the FDA Safety Communication: "UPDATE on Serious Complications Associated with Transvaginal Placement of Surgical Mesh for Pelvic Organ Prolapse". *Int Urogynecol J* 2012; 23: 5-9.
 27. Miedel A, Tegerstedt G, Mörlin B, Hammarström M. A 5-year prospective follow-up study of vaginal surgery for pelvic organ prolapse. *Int Urogynecol J* 2008; 19: 1593-601.
 28. Nyssönen V, Santala M, Ala-Nissilä S, Bloigu R, Haarala M. Posterior Transvaginal Mesh without Concurrent Surgery: How Does it have an Effect on the Untreated Vaginal Compartment? *Gynecol Obstet Invest* 2017; 82: 66-71
 29. Hammett J, Peters A, Trowbridge E, Hullfish K. Short-term surgical outcomes and characteristics of patients with mesh complications from pelvic organ prolapse and stress urinary incontinence surgery. *Int Urogynecol J* 2014; 25: 465-70.
 30. Falagas ME, Velakoulis S, Iavazzo C, Athanasiou S. Mesh-related infections after pelvic organ prolapse repair surgery. *Eur J Obstet Gynecol Reprod Biol* 2007; 134: 147-56.
 31. Barone WR, Amini R, Maiti S, Moalli PA, Abramowitch SD. The impact of boundary conditions on surface curvature of polypropylene mesh in response to uniaxial loading. *J Biomech* 2015; 48:1566-74
 32. Otto J, Kaldenhoff E, Kirschner-Hermanns R, Mühl T, Klinge U. Elongation of textile pelvic floor implants under load is related to complete loss of effective porosity, thereby favoring incorporation in scar plates. *J Biomed Mater Res A* 2014; 102: 1079-84.
 33. Barone WR, Moalli PA, Abramowitch SD. Textile properties of synthetic prolapse mesh in response to uniaxial loading. *Am J Obstet Gynecol* 2016; 215: 326
 34. de Tayrac R, Devoldere G, Renaudie J, Villard P, Guilbaud O, Eglin G; French Ugytex Study Group. Prolapse repair by vaginal route using a new protected low-weight polypropylene mesh: 1-year functional and anatomical outcome in a prospective multicentre study. *Int Urogynecol J* 2007; 18: 251-6.
-