

Varied percutaneous and endovascular management of large iatrogenic Profunda Femoris artery pseudoaneurysm

Wasey Jillani, Raza Sayani, Tanveer Ul Haq, Masood Umer, Muhammad Azeemuddin

Abstract

The case of an elderly male diagnosed with a large iatrogenic pseudoaneurysm arising from the profunda femoris artery on ultrasound examination is presented. The immediate postoperative period was uneventful; however later he developed leg swelling and mild oozing at the incision site. In view of deranged renal function CT angiogram was not done and decision was made to treat the pseudoaneurysm with percutaneous thrombin injection. Almost complete thrombosis was achieved however a small residual portion remained patent near the neck. Later limited contrast angiography was done which re-demonstrated a small aneurysm. Instead of embolizing the vessel completely repeat prolonged balloon inflation was done which later showed no further filling of the pseudoaneurysm.

Keywords: Pseudoaneurysm, Thrombin, Angioembolization.

Introduction

Pseudoaneurysm and haemorrhage of the Profunda Femoris artery (PFA) are rare injuries and have been reported following trauma or orthopaedic procedures performed in the proximal femur. These constitute 0.2% of all PFA injury cases.¹ These may be due to the trauma itself due to dislodged fragment or iatrogenic in nature. Presentation may be acute or delayed. If it is not diagnosed properly and timely, this injury can be life- or limb- threatening.² Clinical examination definitely plays an important role. Doppler ultrasound may be helpful however CT angiography is the best non-invasive tests for diagnosis. Various treatment options are available which include repeat surgical intervention; this is often difficult because of old age, large pseudoaneurysm and associated swelling. Endovascular techniques play a critical role in minimally invasive way.^{3,4} Coil embolization may control bleeding however may result in occlusion of significant segment of arterial supply. Percutaneous thrombin is increasingly being used and considered a standard option in treatment of pseudoaneurysm. Balloon occlusion technique is a well-known option for

treatment of venous extravasation during venoplasties.

Case Report

We present the case of a 68-years-old male who underwent intertrochanteric femur fracture repair using Dynamic hip screw in February 2016. The immediate postoperative period was uneventful; however 2 weeks later he developed leg swelling and had oozing at the site of the surgical scar. He was haemodynamically stable and was referred to the Department of Radiology, Aga Khan University Hospital, Karachi for evaluation of deep vein thrombosis (DVT). On ultrasound, no DVT was seen, however a large pseudoaneurysm measuring 9.5 cm in diameter was seen arising from the profunda femoris artery. It showed yin yang color flow within it. Patent superficial femoral and popliteal arteries were also demonstrated on Doppler examination. CT scan angiogram was advised but could not be done at this stage because of raised creatinine.

After discussion with the patient, family and the primary team, decision was made to treat the pseudoaneurysm with percutaneous thrombin injection. Patient was moved to the angiography suite. Thereafter a 22 G spinal needle was inserted into the pseudoaneurysm under ultrasound guidance and 500 IU of thrombin was injected. (Figure-1a) There was progressive thrombosis of the pseudoaneurysm, and within approximately 3 minutes, there was near complete thrombosis. (Figure-1b) Dressing

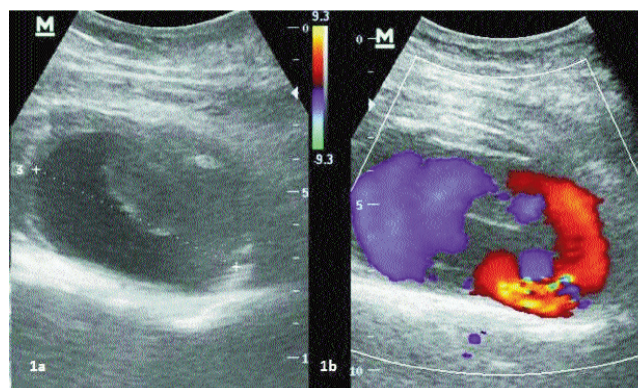


Figure-1: a) Left sided pseudoaneurysm, with partial thrombosis. b) Colour Flow Doppler Swirling flow of blood within the pseudoaneurysm.

.....
Aga Khan University Hospital, Karachi.

Correspondence: Raza Sayani. Email: sayani_raza@yahoo.com

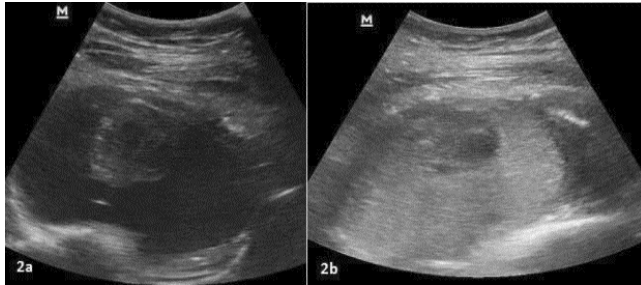


Figure-2: a) Ultrasound shows 22 G spinal needle within the pseudoaneurysm. b) Ultrasound shows near complete thrombosis of the pseudoaneurysm.



Figure-3: a) Angiogram revealed 1 cm residual pseudoaneurysm (arrow). b) shows inflated balloon at the site of rent. c) Showed Complete thrombosis of the pseudoaneurysm with patent profunda femoris artery.

was done and patient was shifted back to special care. There was no more soakage from the surgical site.

Follow-up ultrasound the next day demonstrated near complete thrombosis of the pseudoaneurysm, with minimal residual filling near the neck. Patient was advised follow up however in view of the patient and family concern, diagnostic angiography was planned with limited contrast.

On angiography, there was redemonstration of a small portion of the pseudoaneurysm from profunda femoris branch (Figure-2a). The wire was negotiated distally in patent vessel and a 6 x 40 (eV3 Evercross) balloon was inflated (Figure-2b). After 4 inflations of 5 minutes each, repeat angiographic run revealed complete closure of rent with no further filling of the pseudoaneurysm. (Figure-2c)

Patient was vitally stable after the procedure and followed up for 6 months with complete resolution of pseudoaneurysm. Informed consent was obtained from family for publishing this case.

Discussion

Pseudoaneurysms or haemorrhage of the profunda

femoris artery following femoral trauma or orthopaedic repair remains relatively uncommon however they do occur.^{5,6} Diagnosing arterial injury after DHS fixation may be difficult because of its atypical clinical picture and since other postoperative complications can lead to thigh swelling, such as deep vein thrombosis or consequence of the trauma that has caused the fracture. Other clinical signs, such as presence of a palpable bruit and pulsatility of the swelling, are not useful to differential diagnosis since pseudoaneurysms and haematoma after PFA injury are located deep in the intramuscular space.

Early utilization of imaging may be helpful in diagnosis and treatment. Duplex ultrasonography, computed tomography angiography and conventional angiography may be used. Initially angiogram after Doppler examination was advised in our case but could not be done because of deranged renal function.

Surgical repair is a difficult choice in these patients because of old age and history of recent surgical status. Manual or ultrasound guided compression for superficial femoral artery pseudoaneurysm has been tried with good results⁷ however our patient was uncomfortable with mild compression and hence this could not be attempted.

The embolization of the profunda femoris artery branch leading to haemorrhage or pseudoaneurysm, is a relatively straight forward choice however it results in occlusion of the vessel which may be not be an ideal situation. We tried a varied approach to preserve the patency of the vessel.

In recent years, endovascular repair of femoral artery haemorrhage or pseudoaneurysms with covered stents have become feasible however cost was also a limiting factor in our case.

The percutaneous injection of thrombin into the pseudoaneurysm under duplex ultrasound guidance is a therapeutic option that avoids the transarterial catheterization however this was not completely successful in our case.^{8,9}

The cause of failure of complete thrombosis may be low dose for this large pseudoaneurysm. This along with patient's reluctance for repeat procedure was the cause for an alternate management.

Prolonged balloon inflation is a technique which is often used in venous ruptures during venoplasty and proved useful in our case.^{10,11}

This varied approach may be helpful in cases where there are cost issues, non-availability of covered stents and

desire to save the native vessel.

Disclaimer: None to declare.

Conflict of Interest: None to declare.

Funding Disclosure: None to declare.

References

1. Murphy PG, Geoghegan JG, Austin O, More-O'Ferrall R, Quinlan WR, Keaveny TV. Pseudoaneurysm of the profunda femoris artery due to intertrochanteric fracture of the hip. *Arch Orthop Trauma Surg.* 1999; 119: 117-8.
2. Webber GW, Jang J, Gustavson S, Olin JW. Contemporary Management of Postcatheterization Pseudoaneurysms." *Circulation.* 2007; 115: 2666-74.
3. Walid A, Haq TU, Sayani R, Rehman ZU, "Embolization with Histoacryl Glue of an Anastomotic Pseudoaneurysm following Surgical Repair of Abdominal Aortic Aneurysm," *Case Rep Vasc Med.* 2013; 2013: 761384.
4. Sayani R, Qamari NA, Saeed MA, Ali M. Rare case of isolated internal iliac artery pseudoaneurysm presenting with rupture. Successful angioembolization using coils and histoacryl glue. *Pak J Radiol.* 2016; 26: 258-60.
5. Kizilates U, Nagesser SK, Krebbers YM, Sonneveld DJ. False aneurysm of the deep femoral artery as a complication of intertrochanteric fracture of the hip: Options of open and endovascular repair. *Perspect Vasc Surg Endovasc Ther.* 2009; 21: 245-8.
6. Akgül C, Hansen LG, Jonung TJ, Thomassen . Pseudoaneurysm in the femoral artery after repeated hip surgery — combined thrombolytic and surgical treatment. *Ugeskr Laeger.* 2003; 165: 583-5.
7. Kontopodis N, Tsetis D, Tavlas E, Dedes A, Ioannou CV. Ultrasound Guided Compression Versus Ultrasound Guided Thrombin Injection for the Treatment of Post-Catheterization Femoral Pseudoaneurysms: Systematic Review and Meta-Analysis of Comparative Studies. *Eur J Vasc Endovasc Surg.* 2016; 51: 815-23.
8. Luedde M, Krumsdorf U, Zehelein J, Ivandic B, Dengler T, Katus HA, et al. Treatment of iatrogenic femoral pseudoaneurysm by ultrasound-guided compression therapy and thrombin injection. *Angiology.* 2007; 58: 435-9.
9. Wixon CL, Philpott JM, Bogey WM Jr, Powell CS. Duplex-directed thrombin injection as a method to treat femoral artery pseudoaneurysms. *J Am Coll Surg.* 1998; 187: 464-6.
10. Vesely TM. Role of stents and stent grafts in management of hemodialysis access complications. *Semin Vasc Surg.* 2007; 20: 175-83.
11. Weng MJ, Chen MC, Liang HL, Pan HB. Treatment of Hemodialysis Vascular Access Rupture Irresponsive to Prolonged Balloon Tamponade: Retrospective Evaluation of the Effectiveness of N-Butyl Cyanoacrylate Seal-Off Technique. *Korean J Radiol.* 2013; 14: 70-80.