

## A huge Thornwaldt's cyst causing hearing loss in an adult patient

Nazim Bozan,<sup>1</sup> Yunus Feyyat Sakin,<sup>2</sup> Pinar Kundi,<sup>3</sup> Muzaffer Ari,<sup>4</sup> Ferhat Bozkus<sup>5</sup>

### Abstract

Nasopharynx (NP) is anatomically difficult to explore adequately. The pharyngeal bursa (PB) is a recess lined with respiratory epithelium along the posterior wall of the nasopharynx between the longus capitis muscles. If the opening through which the bursa drains into the nasopharynx becomes obstructed, a Thornwaldt's cyst (TC) might develop. Small-sized cysts are mostly asymptomatic, whereas large-sized cysts may lead to various nasal and otologic symptoms depending on their localization. In this report, we present a 71-year-old case with a huge TC who presented to our clinic with the complaints of snoring, nasal obstruction, periodic halitosis, postnasal drip, headache, and hearing loss in the left ear and underwent total excision of the cyst through transnasal endoscopy. The diagnosis and treatment characteristics of the case are presented with the review of the literature.

**Keywords:** Thornwaldt's cyst, Hearing loss, Endoscopy.

### Introduction

The pharyngeal bursa (PB) is a recess lined with respiratory epithelium along the midline posterior superior wall of the nasopharynx between the longus capitis muscles. PB is located superior to the superior constrictor muscle, at the level of the lateral pharyngeal recess (fossa of Rosenmüller). If the opening through which the bursa drains into the nasopharynx becomes obstructed, a Thornwaldt's cyst (TC) might develop.<sup>1</sup>

Surgery is the mainstay treatment of TC. However, no surgery is needed if the cyst is small-sized and causes no disturbing symptoms. Common surgical methods used in the treatment of TC include abscess drainage, cyst excision, and marsupialization.<sup>1,2</sup> In this report, we present a case with TC who underwent total excision of the cyst through transnasal endoscopy. The diagnosis and treatment characteristics of the case are presented with the review of the literature.

.....  
Department of Otorhinolaryngology, <sup>1,3</sup>Yuzuncu Yil University Faculty of Medicine, Van, <sup>2</sup>Diyarbakir Training and Research Hospital, Diyarbakir, <sup>4</sup>Mardin State Hospital, Mardin, <sup>5</sup>Harran University Faculty of Medicine, Sanliurfa, Turkey.


**Correspondence:** Nazim Bozan. Email: drnzmbozan@hotmail.com

### Case Report

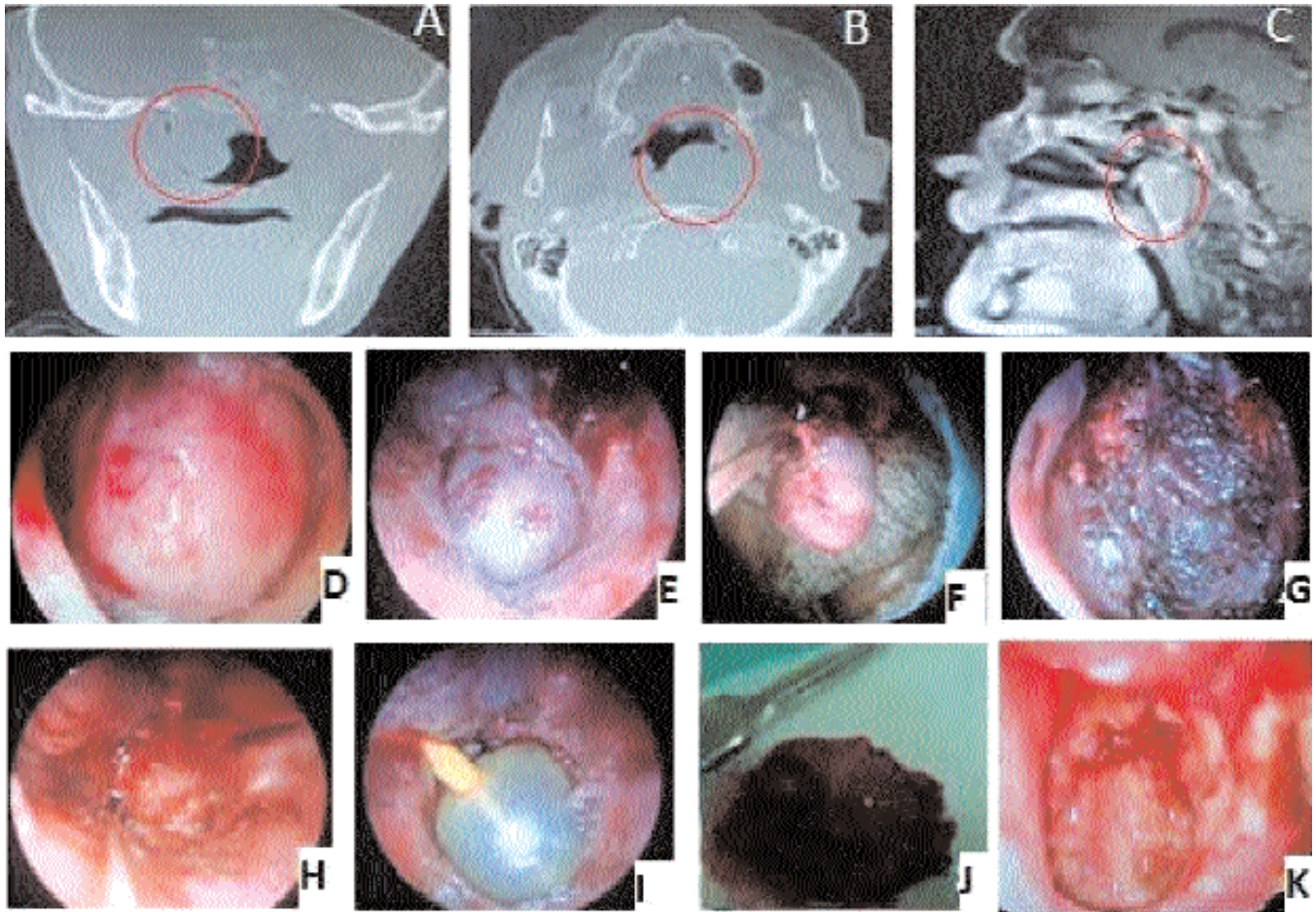
A 71-year-old male patient presented to us at the Yuzuncu Yil University Hospital, Van, Turkey in May 2013 with a one-year history of snoring, nasal obstruction, periodic halitosis, postnasal drip, occipital headache, and hearing loss. These symptoms gradually became worse within the last three months. The history revealed that the patient had presented to several clinics due to these complaints and had used various medical therapies with a prediagnosis of sinusitis but had no improvement of symptoms.

An endoscopic examination showed a fluctuating, soft cystic mass measuring 3x3.5 cm, covered with firm mucosa in the nasopharyngeal space, and completely obstructing the airway in the left side of the nasopharynx. Pure tone audiometry concluded conductive hearing loss in the left ear (Figure-1 A).

A computed tomography (CT) scan revealed soft-tissue density measuring approximately 3 cm in diameter on the posterolateral wall of the left nasopharynx, obstructing the lumen and showing exophytic growth towards the lumen. A sagittal-plane CT scan showed a 33x17x28 mm mass on the posterolateral wall of the left nasopharynx, also showing exophytic growth towards the lumen and obstructing the lumen. Due to its intensive purulent content, the mass did not have a cystic appearance but appeared as a soft tissue lump (Figure- 2 A, B). A nasopharyngeal magnetic resonance imaging (MRI) detected a 33x17x28 mm cystic mass in the left half of the nasopharynx, slightly hyperintense on T1-weighted series and hyperintense on T2-weighted series, causing airway obstruction on the left nasal passage, and showing



**Figure-1:** (A) Pure tone audiometry at presentation. (B) Pure tone audiometry at 3-month follow-up.



**Figure-2:** (A) A coronal view of the cyst on paranasal sinus tomography. (B) An axial view of the cyst on paranasal sinus tomography. (C) A view of the cyst on nasopharyngeal MRI. (D) An endoscopic view of the cyst obstructing the left choana. (E-F) Endoscopy-guided elevation and total excision of the cyst. (G-H) Bleeding control via cauterization following the excision of the cyst. (I) The Foley catheter balloon inflated for bleeding control in the left nasal airway. (J) Postoperative view of the cyst following excision. (K) An endoscopic view of the nasopharynx at postoperative day 10.

minimal peripheral enhancement after intravenous contrast injection (Figure-2 C).

After informed consent from the patient was obtained, endoscopic surgery was performed under general anaesthesia. In the left nasopharyngeal space, local infiltration anaesthesia was performed using a 0-degree endoscope with an 18-gauge spinal needle (lumbar puncture needle). By using a transnasal endoscopic approach, the left nasal cavity was entered and the total excision of the cyst was performed by bipolar cautery, bistoury, elevator, and cup forceps (Figure-2 D-J). Pathological examination revealed a cyst capsule including tissue fragments with moderate lymphocytic and histiocytic infiltration in its stroma covered by respiratory epithelium. Depending on the clinical and histopathological findings, the patient was considered to have a Thornwaldt's cyst.

At postoperative day 10, the endoscopic examination showed a normal nasopharynx (Figure- 2 K). At postoperative month 3, the pure tone audiometry was normal (Figure-1 B).

### Discussion

Thornwaldt's cysts are classified as cystic and crusting. The cystic types are more common and do not spontaneously drain into the nasopharynx. In the crusting types, the drainage pathway is open and the cysts regularly and spontaneously drain into the nasopharynx. These cysts also cause a bad smell and an unpleasant taste. The cystic types are often asymptomatic.<sup>3</sup> If the cyst size exceeds 1-2 cm in diameter, they may cause a number of symptoms including persistent postnasal drip, occipital headache, neck stiffness, halitosis, and conductive hearing loss associated with middle ear effusion caused by nasal speech and Eustachian tube dysfunction.<sup>4</sup> Our patient was detected with a 3x3.5

cm fluctuating, soft Thornwaldt's cyst covered with firm mucosa, completely obstructing the airway in the left side of the nasopharynx, and causing middle ear effusion and hearing loss. The symptoms of the patient such as headache, sore throat, nasal obstruction and postnasal drip were compatible with sinusitis. Before presenting to our clinic, the patient had received several medical therapies with a prediagnosis of rhinosinusitis but had no improvement of symptoms. We consider that the physicians in the previous clinics might have missed the Thornwaldt's cyst in our patient since they might have inadvertently focused on the ostiomeatal complex instead of the nasopharynx in endoscopic examinations.

Nasal and nasopharyngeal endoscopic examinations play a key role in the diagnosis of TC. In particular, these examinations should be performed in patients presenting with persistent nasal obstruction and postnasal drip in order to avoid missing the diagnosis of TC. Moreover, imaging techniques also play an important role in the diagnosis of the Thornwaldt's cysts that are asymptomatic, submucosal, or smaller than 10 mm in size. Common imaging techniques include nasopharyngeal MRI and CT.<sup>5</sup> On MRI, TC shows characteristic bright signal intensity both on T1- and T2-weighted images, which may be associated either with the protein content of the cyst or intracystic bleeding. The characteristic localization of TC and its characteristic pattern on MRI are the specific features that help distinguish TC from the adenoid tissue.<sup>6</sup> TC can be easily missed if the nasopharyngeal space is not examined adequately and no CT or MRI scan is performed. In addition, waiting for the fluid appearance on CT may be misleading for the physician. As we encountered in our patient, the fluid appearance on CT may not indicate the presence of cystic lesions. On the other hand, soft-tissue lumps may be seen in the posterior superior wall of the nasopharynx. If the specimens are obtained on the coronal plane with a diagnosis of sinusitis, the soft-tissue lumps on the posterior wall may not be detected.

Differential diagnosis of TC should include choanal polyp, angiofibroma, nasopharynx cancer, mucosal and adenoid retention cysts, chordoma, meningomyeloceles and meningoceles, adenoid retention cysts, branchial cleft cysts, and Rathke's pouch cysts.<sup>6,7</sup>

Surgical treatment of TC can be performed under local or general anaesthesia, depending on the cyst size and the symptoms caused by the cyst. However, no surgery is needed in small-sized and asymptomatic cysts. In the cysts

causing disturbing symptoms and growing towards the torus tubarius, an endoscopic endonasal or transoral approach can be performed. With the transoral approach, the marsupialization method can be performed to completely remove the anterior wall of the cyst. In this approach, the marsupialization of the cyst with the use of a 70-degree endoscope and an angled microdebrider causes less bleeding and less trauma to the surrounding tissue.<sup>8</sup> However, since the tissue integrity of the cyst is impaired by the microdebrider, histopathological examination may become difficult. In our patient, a transnasal endoscopic approach was performed under general anaesthesia for the total excision of the cystic mass. No recurrence occurred during the postoperative follow-up.

### Conclusion

In conclusion, endoscopic examination of the nasopharynx should definitely be performed in the patients presenting with the symptoms including headache, nasal obstruction, postnasal drip, and hearing loss. In addition, Thornwaldt's cyst should be kept in mind in such patients. This institutional ethical approval obtained case report is noteworthy since it demonstrated that a huge Thornwaldt's cyst is likely to be amongst the pathologies causing conductive hearing loss associated with unilateral middle ear effusion.

### Acknowledgements

The authors declare no competing interest. No financial support was received for this paper.

**Disclaimer:** None.

**Conflict of Interest:** None.

**Funding:** None.

### References

1. Battino RA, Khangure MS. Is that another Thornwaldt's cyst on MRI? *Austr Radiol.* 1990; 34:19-23.
2. Weissman JL. Thornwaldt cyst. *Am J Otolaryngol.* 1992; 13: 381-5.
3. Cho HS, Byeon HK, Kim JH, Kim KS. Thornwaldt's cyst presenting only as occipital headache: a case report. *Headache.* 2009; 49:307-10.
4. Miller RH, Sneed WF. Thornwaldt's bursa. *Clin Otolaryngol. Allied Sci.* 1985; 10:21-5.
5. Yanagisawa E, Yanagisawa K. Endoscopic view of Thornwaldt cyst of the nasopharynx. *Ear Nose Throat J.* 1994; 73:884-5.
6. Miyahara H, Matsunaga T. Thornwaldt's disease. *Acta Otolaryngol.* 1994; 517:36-9.
7. Daboin KP, Neto A, Perez VO, Luna MA. Nasopharyngeal adenocarcinomas: a clinicopathologic study of 44 cases including immunohistochemical features of 18 papillary phenotypes. *Ann Diagn Pathol.* 2006; 10:215-21.
8. Eloy P, Watelet JB, Hatert AS, Bertrand B. Thornwaldt's cyst and surgery with power instrumentation. *B-ENT.* 2006; 2:135-9.