

## Preventive role of magnesium sulphate on dexamethasone induced testicular injury in albino rats

Hemant Kumar,<sup>1</sup> Inayatullah,<sup>2</sup> Aisha Qamar<sup>3</sup>

### Abstract

**Objective:** To evaluate the protection provided by magnesium sulphate on corticosteroid-induced testicular injury in albino rats.

**Methods:** This experimental study was conducted at Jinnah Postgraduate Medical Centre, Karachi, from August 1 to 20, 2012, and comprised albino rats. About 90-120 days old and weighing 200-230 gm. They were divided into 3 groups. Group A comprised controls, Group B animals were administered dexamethasone 4mg/kg body weight per day intra-peritoneally, and Group C animals were given magnesium sulphate 20mg/kg body weight per day intramuscularly, with dexamethasone at same dose as in Group B. Rats were sacrificed at the end of study period after recording their final weight. A midline abdominal incision was made and extended downward to the scrotum. Both testes were removed. Sections from both testes were prepared and stained with periodic acid-Schiff -Iron Haematoxylin.

**Results:** Of the 30 rats, each group had 10(33.33%). The mean final body weight was 251.80±1.35gm in Group A, 204.60±1.88gm in Group B and 236.00±2.52gm in Group C. The mean diameter of seminiferous tubules was 268.40±7.30µm in Group A, 177.00±10.90µm in Group B and 238.40±2.42µm in Group C. The mean thickness of germinal epithelium was 85.26±1.93µm, 32.40±3.26µm and 60.40±3.18µm in the three groups, respectively.

**Conclusion:** The use of dexamethasone caused testicular injury, which ameliorated significantly by the concomitant use of magnesium sulphate.

**Keywords:** Corticosteroid, dexamethasone, testicular injury, seminiferous tubules, magnesium sulphate. (JPMA 66: 1407; 2016)

### Introduction

Infertility has become a major clinical problem and 50% of cases are attributable to the male partner.<sup>1</sup> Spermatogenesis is a complex process of germ cell proliferation and differentiation which leads to the production and release of spermatozoa from the testis.<sup>2</sup> A large number of environmental factors adversely affect spermatogenesis. These testicular toxicants include heat,<sup>1</sup> nano-particles such as titanium oxide<sup>2</sup> and zinc oxide,<sup>3</sup> obesity<sup>4,5</sup> and dexamethasone.<sup>6</sup>

Glucocorticoids are widely used pharmacological agents for a variety of allergic, autoimmune, inflammatory and neoplastic disorders. In addition to the beneficial effects, they also lead to numerous changes in various biological systems, including the reproductive system, producing many unwanted effects, such as testicular degeneration, even when given in therapeutic doses.<sup>7,8</sup>

Minerals account for 4% of the weight of the body and are required for the normal growth and maintenance of the body. The body contains about 22 known minerals, the majority are believed to be essential for life, e.g. sodium, potassium, magnesium, calcium, chloride, phosphorus, zinc, etc. Deficiency of these elements can lead to serious disorders.<sup>9</sup> Magnesium is the second abundant intracellular cation acting as a co-factor in more than 500 proteins participating in many biological reactions needed for cell function.<sup>10,11</sup> Deficiency of magnesium in the body is associated with the development of diabetic nephropathy<sup>12</sup> and retinopathy in addition to other effects.<sup>13</sup> Magnesium sulphate supplementation also improves oxidative stress in sodium-metavanadate-induced lipid peroxidation.<sup>14</sup>

In the pilot study, zinc had also been used to observe its protective effects on dexamethasone-induced testicular injury. Zinc with dexamethasone-treated animals showed insignificant increase in body weight and protection on testicular damage when compared with magnesium+dexamethasone-treated animals. Moreover, zinc has already been used twice earlier at the Basic Medical Sciences Institute (BMSI), last being in 2008 in azathioprine-induced testicular damage. Among

.....  
Department of Anatomy, <sup>1</sup>Hamdard College of Medicine and Dentistry, Hamdard University, Karachi, <sup>2</sup>Gaju Khan Medical College, Swabi, KPK, <sup>3</sup>Bahria University Medical and Dental College, Karachi.

**Correspondence:** Hemant Kumar. Email: hemant\_chandani@yahoo.com

minerals, magnesium has never been used as a protective agent in research on testicular histology throughout the world. That is why magnesium sulphate has been used in this research.

Since glucocorticoids, such as dexamethasone, have been prescribed so widely these days for their beneficial effects, the present study was designed to evaluate the adverse effect of dexamethasone on rat testicular tissue, and to find a suitable agent for neutralising or minimising the damaging effects of dexamethasone. Magnesium sulphate was used to observe whether it ameliorates the testicular damage caused by dexamethasone.

## Materials and Methods

This experimental study was conducted at BMSI, Jinnah Postgraduate Medical Centre (JPMC), Karachi, Pakistan, from August 1 to 20, 2012, and comprised albino rats. Ethical approval was obtained from the institutional review board.

Young male albino rats aged about 90-120 days and weighing 200-230gm were included. The rats were divided into 3 groups according to the treatment given. Group A was comprised controls, Group B animals were administered dexamethasone at the dose of 4mg/kg body weight per day intraperitoneally,<sup>8</sup> whereas Group C animals were given magnesium sulphate at the dose of 20mg/kg body weight per day intramuscularly,<sup>15</sup> with dexamethasone at the same dose as in Group B. The animals were observed for one week before the commencement of the study for the assessment of their health status and food intake.

The rats were sacrificed at the end of the study period, i.e. 20 days after recording their final weight. A mid-line incision was made, extended downward to the scrotum. Both the testes were removed. The testes were fixed in Bouin's fluid<sup>16</sup> for 24 hours. After 24 hours, each testis was cut longitudinally into two equal halves and again placed in fresh Bouin's fluid for another 24 hours. The tissues were kept in capsules and then washed in running tap water for 3 to 4 hours to remove excess fixative. After fixation, tissues were processed in ascending grades of alcohol, infiltrated and embedded in paraffin. Then, 5µm thick longitudinal sections were cut on rotary microtome. Sections of tissue were floated on hot water bath at 42°C and transferred on albumenised glass slides. The slides were placed on hot plate at 37°C for 24 hours for fixation of tissues and stained with periodic acid-Schiff (PAS)-Iron Haematoxylin technique<sup>16</sup> for the morphology, and measurement of diameter and thickness of germinal epithelium in seminiferous tubules. The statistical significance of differences of quantitative changes

between the experimental and control groups was evaluated by the paired sample Student's t-test.  $P \leq 0.05$  was considered significant. SPSS 20 was used for data analysis.

## Results

Of the 30 rats included, there were 10(33.33%) in each group. The mean final body weight was  $251.80 \pm 1.35$  gm in Group A,  $204.60 \pm 1.88$  gm in Group B and  $236.00 \pm 2.52$  gm in Group C (Figure-1).

PAS-Iron Haematoxylin-stained 5µm thick testicular sections in Group A animals showed that seminiferous tubules had even diameters within the section, lined by stratified germinal epithelium with intact basement

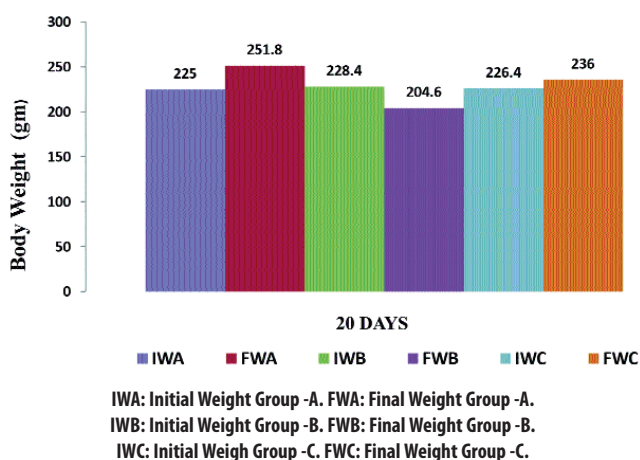


Figure-1: Mean body weight (gm) of albino rats in different groups.

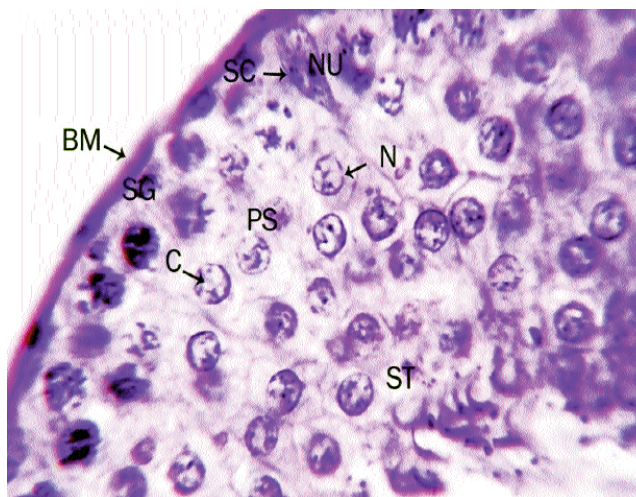
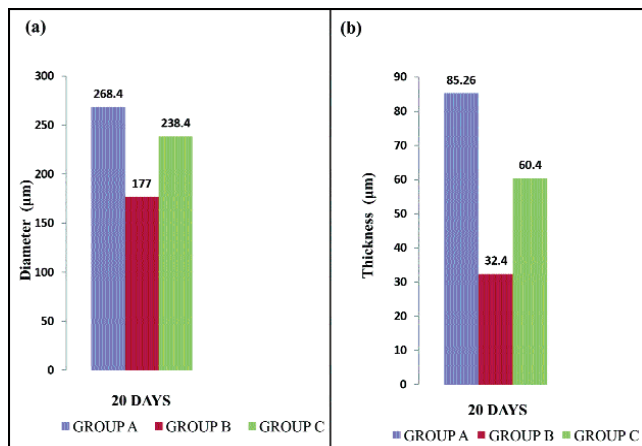
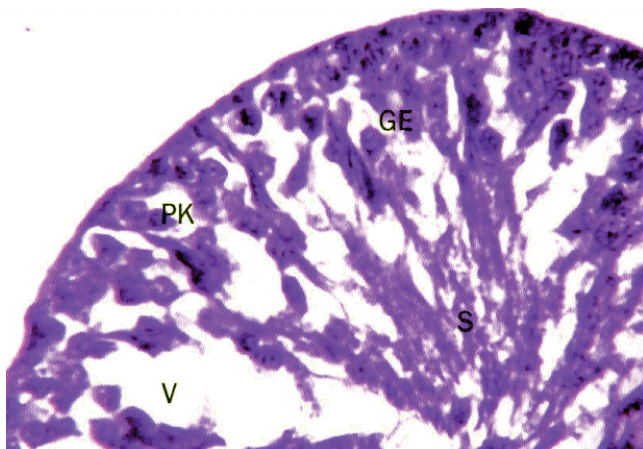


Figure-2: PAS-iron Haematoxylin stained, 5µm thick section of testis of control Albino rat, showing a part of seminiferous tubule with intact basement membrane (BM), Spermatogonia (SG), Primary spermatocytes (PS), Spermatids (ST), Sertoli cells (SC), Nucleus (N), Nucleoli (NU) and Chromatin network(C). Photomicrograph 100 X.



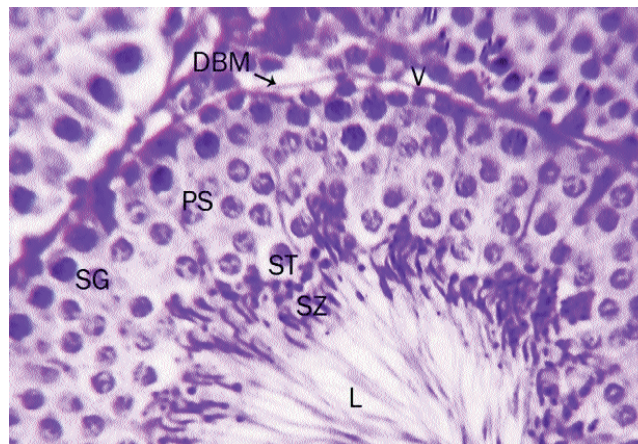**Figure-3:** a) Mean Diameter ( $\mu\text{m}$ ) of Seminiferous Tubules of Albino Rats in Different Groups. b) Mean Thickness ( $\mu\text{m}$ ) of Germinal Epithelium of Seminiferous Tubules of Albino Rats in Different Groups.



**Figure-4:** PAS-iron Haematoxylin stained, 5μm thick section of testis of dexamethasone treated albino rat, showing part of seminiferous tubule, scanty germinal epithelium (GE), marked vacuolation (V), slough (S) and pyknotic nuclei (PK). Photomicrograph 100 X.

membrane. Multilayer germinal epithelium was observed with several types of spermatogenic cell (Figure-2). The mean diameter of seminiferous tubules in Group A was  $268.40 \pm 7.30 \mu\text{m}$  (Figure-3a), whereas the mean thickness of germinal epithelium was  $85.26 \pm 1.93 \mu\text{m}$  (Figure-3b).

Examination of PAS Iron Haematoxylin-stained testicular sections of Group B animals showed damaged seminiferous tubules with distorted shapes and reduced diameter. There was thinning of germinal epithelium along with marked vacuolation within the seminiferous tubules. The tubules showed debris within the lumen because of sloughing of germ cells as well as pyknotic nuclei. The germinal epithelium was disorganised (Figure-



**Figure-5:** PAS-iron Haematoxylin stained, 5μm thick section of testis of dexamethasone with magnesium sulphate treated albino rat, showing all series of germ cells i.e., spermatogonia (SG), primary spermatocyte (PS), spermatid (ST), spermatozoa (SZ), vacuoles (V), and detached basement membrane (DBM). Photomicrograph 100 X.

4). Seminiferous tubules had a mean diameter of  $177.00 \pm 10.90 \mu\text{m}$  in Group B. The mean thickness of germinal epithelium in Group B was  $32.40 \pm 3.26 \mu\text{m}$ .

PAS-Iron Haematoxylin-stained testicular sections in Group C animals revealed highly restored seminiferous tubules with slightly altered shape and detachment of basement membrane (Figure-5). The thickness of germinal epithelium was near to control but still showed some vacuoles. The mean diameter of seminiferous tubules in Group C was  $238.40 \pm 2.42 \mu\text{m}$ , whereas the mean thickness of germinal epithelium was  $60.40 \pm 3.18 \mu\text{m}$ .

## Discussion

Infertility has become a major problem in both men and women. Normal spermatogenesis represents a precisely regulated balance between continuous cell proliferation and concomitant programmed cell death. The causes of impaired spermatogenesis are multi-factorial, including environmental, nutritional, behavioural, genetic and hormonal factors, as well as drugs.<sup>17</sup>

Glucocorticoids are the hormones secreted by the adrenal cortex, and affect the activity of almost every cell in the body. They modulate the expression of approximately 10% of our genes, and are essential for life. The use of glucocorticoids has increased extensively these days because of their efficacy as potent anti-inflammatory drugs. However, with their increasingly known therapeutic benefits, they are found to be involved in the pathogenesis of many diseases and produce many unwanted effects when given therapeutically.<sup>7,18</sup> It has

been observed that dexamethasone also acts as testicular toxicant leading to infertility.<sup>8</sup>

Magnesium is an essential nutrient that acts as a cofactor in numerous enzymatic reactions including energy metabolism, and proteins and nucleic acids biosynthesis.<sup>19</sup>

The body weight of dexamethasone-treated animals was highly significantly decreased compared to the control. This was most likely due to anorexia, decreased protein synthesis and increased protein degradation. These findings were similar to a study<sup>20</sup> which observed that dexamethasone reduces body weight due to its catabolic effects on protein and collagen turnover. Another study<sup>21</sup> reported decreased body weight in agreement to the present study, in dexamethasone-induced arthritic rats, which caused suppression of protein synthesis and decreased energy intake.

In the current study, there was improvement in body weight in Group C animals when magnesium sulphate was given along with dexamethasone, as compared to dexamethasone only. This was most likely due to increased intestinal absorption by magnesium, as well as synthesis of nucleic acids as explained by Saris.<sup>22</sup>

In Group B animals, there was distorted shape of seminiferous tubules, along with marked vacuolation and sloughing of germ cells. Pyknotic nuclei were also visible. The diameter of seminiferous tubules was also reduced with decreased thickness of germinal epithelium. There are many reasons for these changes. Glucocorticoid receptors (GRs) of Sertoli cells are necessary to support normal testicular functions. Dexamethasone decreases the concentrations of these receptors as demonstrated in a study,<sup>23</sup> in addition to luteinizing hormone receptor, 24-dehydrocholesterol reductase, glutathione S-transferase, and aromatase in stallion testes after using dexamethasone in a dose of 10mg/kg intraperitoneally for 7 days. Animal models lacking GRs showed morphological changes, including low number of Sertoli cells, low number of spermatocytes and spermatids, and decreased seminiferous tubule formation. In another study,<sup>6</sup> dexamethasone-induced spermatogenesis defects including epithelial vacuolisation, sloughing of germ cells, reduction of seminiferous tubule diameter, reduction in the number of sperm heads and significant maturation arrest were in agreement with the present study. However, another study<sup>24</sup> found that diameters of seminiferous tubules were markedly increased with atrophy of testes and absence of elongated spermatozoa in mice after a single intraperitoneal injection of 3-methyl-4-nitrophenol at 100 mg/kg body weight after one week, which was in disagreement with our study.

The testicular morphology was restored to a great extent in magnesium sulphate with dexamethasone receiving Group C animals, revealing slightly altered shape of seminiferous tubules. The tubular diameter and epithelial height were also increased as compared to dexamethasone-treated group. The protective effect of magnesium sulphate can be explained by its free radical scavenging effects. It also modulates testicular-free radical production. These findings are similar to a study<sup>25</sup> which observed significant improvement in morphology of testes after ethanol-induced testicular damage, by using Magnesium isoglycyrrhizinate (45 mg/kg/day intraperitoneally) for 18 days, along with ethanol for the same duration. They also observed that magnesium can cross the blood-testis barrier and reach concentrations that can exert an antioxidant effect.

## Conclusion

Dexamethasone caused testicular damage when given for 20 days. Moreover, magnesium sulphate was found to be effective in preventing this testicular damage. The use of corticosteroids has increased greatly these days because of their therapeutic efficacy in various diseases, so this study may be expanded to human subjects to observe if magnesium sulphate plays a beneficial role in patients taking corticosteroids on a long-term basis, such as asthma, autoimmune diseases, chronic inflammation, etc.

**Disclaimer:** None.

**Conflict of Interest:** None.

**Source of Funding:** None.

## References

1. Paul C, Murray AA, Spears N, Saunders PT. A single, mild, transient scrotal heat stress causes DNA damage, subfertility and impairs formation of blastocysts in mice. *Reproduction* 2008; 136: 73-84.
2. Orazizadeh M, Khorsandi L, Absalan F, Hashemitabar M, Daneshi E. Effect of beta-carotene on titanium oxide nanoparticles-induced testicular toxicity in mice. *J Assist Reprod Genet* 2014; 31: 561-8.
3. Talebi AR, Khorsandi L, Moridian M. The effect of zinc oxide nanoparticles on mouse spermatogenesis. *J Assist Reprod Genet* 2013; 30: 1203-9.
4. Du Plessis SS, Cabler S, McAlister DA, Sabanegh E, Agarwal A. The effect of obesity on sperm disorders and male infertility. *Nat Rev Urol* 2010; 7: 153-61.
5. Eskandar M, Al-Asmari M, Chaduvula SB, Al-Shahrani M, Al-Sunaidi M, Almushait M, et al. Impact of Male Obesity on Semen Quality and Serum Sex Hormones. *Adv Urol* 2012: 407601.
6. Khorsandi L, Mirhoseini M, Mohamadpour M, Orazizadeh M, Khaghani S. Effect of curcumin on dexamethasone-induced testicular toxicity in mice. *Pharm Biol* 2013; 51: 206-12.
7. Buckingham JC. Glucocorticoids: exemplars of multi-tasking. *Br J Pharmacol* 2006; 147: 258-68.
8. Orazizadeh M, Khorsandi LS, Hashemitabar M. Toxic effects of dexamethasone on mouse testicular germ cells. *Andrologia* 2010; 42: 247-53.
9. Barasi ME. Minerals, Electrolyte and Fluid: Human Nutrition. 2nd

- ed. London: Arnold a member of the Hodder Headline Group; 2003.
10. Han JU. About uses of Magnesium during perioperative period. *Korean J Anesthesiol* 2012; 62: 509-11.
  11. Kuzenkov VS, Krushinskii AL. Protective Effect of Magnesium Nitrate against Neurological Disorders provoked by Cerebral Ischaemia in Rats. *Bull Exp Biol Med* 2014; 157: 688-91.
  12. Parvizi MR, Parviz M, Tavangar SM, Soltani N, Kadkhodae M, Seifi B, et al. Protective effect of magnesium on renal function in STZ-induced diabetic rats. *J Diabetes Metabol Disord* 2014; 13: 84
  13. Dasgupta A, Sarma D, Saikia UK: Hypomagnesemia in type 2 diabetes mellitus. *Indian J Endocrinol Metab* 2012, 16:1000-3.
  14. Scibior A, Golebiowska D, Niedzwiecka I. Magnesium can protect against vanadium-induced lipid peroxidation in the hepatic tissue. *Oxid Med Cell Longev* 2013; 2013: 802734.
  15. Yuanqiao HE, Zeng F, Liu Q, Ju W, Fu H, Hao H, et al. Protective effect of magnesium isoglycyrrhizinate on ethanol induced testicular injury in mice. *J Biomed Res* 2010; 24:153-60.
  16. Bancroft JD, Gamble M. *Theory and practical of Histological Techniques*. 6th ed. Edinburg: Elsevier Churchill Livingstone; 2008: 25-27,136-38.
  17. Turner TT, Lysiak JJ. Oxidative stress: a common factor in testicular dysfunction. *J Androl* 2008; 29: 488-98.
  18. Orazizadeh M, Hashemitabar M, Khorsandi L. Protective effect of minocycline on dexamethasone induced testicular germ cell apoptosis in mice. *Eur Rev Med Pharmacol Sci* 2009; 13: 1-5.
  19. Nyam. Magnesium nutrition and health. *Caribbean Food Nutrition Institute* 2005; 1-2.
  20. Crofton PM, Shrivastava A, Wade JC, Srephen R, Kelnar CJH, Mcintosh N, et al. Effects of dexamethasone treatment on bone and collagen turnover in preterm infants with chronic lung disease. *Pediatr Res* 2000; 48: 155-62.
  21. Caparroz-assef SM, Bersani-Amedo CA, Kelmer-Bracht AM, Bracht A, Ishii-Iwamoto EL. The metabolic changes caused by dexamethasone in the adjuvant-induced arthritic rat. *Mol Cell Biochem* 2007; 302: 87-98.
  22. Saris NE, Mervaala E, Karppanen H, Khawaja JA, Lewenstam A. Magnesium. An update on physiological, clinical and analytical aspects. *Clin Chem Acta* 2000; 294: 1-26.
  23. Niknafs B, Mirzaei N, Anarcoolij. Protective effects of melatonin on Dexamethasone toxicity in seminiferous tubules in comparison with testosterone treatment. *Jokull* 2015; 65: 22.
  24. Bu T, Jia Y, Lin J, Mi Y, Zhang C. Alleviative effect of quercetin on germ cells intoxicated by 3-methyl-4-nitrophenol from diesel exhaust particles. *J Zhejiang Univ Sci B* 2012; 13: 318-26.
  25. He Y, Zeng F, Liu Q, Ju W, Fu H, Hao H, et al. Protective Effect of Magnesium Isoglycyrrhizinate on Ethanol-Induced Testicular Injuries in Mice. *J Biomed Res* 2010; 24: 153-60.
-