

Modified Limberg's flap versus primary closure for treatment of pilonidal sinus disease: A comparative study

Faisal Shabbir,¹ Mahmood Ayyaz,² Muhammad Waris Farooka,³ Asad Ali Toor,⁴ Hassan Sarwar,⁵ Awais Amjad Malik⁶

Abstract

Objectives: To compare the outcome of Rhomboid excision and Modified Limberg's flap closure with excision and primary closure for the treatment of Sacrococcygeal Pilonidal sinus.

Methods: The study was conducted at the Surgical Department of Mayo Hospital, Lahore, from 2009 to 2012. A total of 60 patients of pilonidal sinus were randomly divided into two equal groups. The patients were operated under general anaesthesia in prone position by Rhomboid excision and Modified Limberg's flap closure with a closed suction drain in group 1, and excision and primary closure over a drain in group 2. Patients were followed up for 12 months for surgical complications of the treatment. SPSS 17 was used for statistical analysis.

Results: In group 1 there were 27(90%) males and 3(10%) females, while group 2 had 28(93.3%) males and 2(6.7%) females. The infection rates were observed to be 2(7%) in group 1 and 8(26.6%) ($p < 0.038$) in group 2. The recurrence rate was only 1(3.3%) in group 1 compared to 4(13.3%) in group 2. Average hospital stay was 1.63 ± 0.67 days group 1 and 2.8 ± 1.24 days in group 2.

Conclusion: Modified Limberg's flap closure is an effective treatment modality for pilonidal sinus disease with 1.5 times less infection rate, 4 times less recurrence rate and 40% in-hospital time.

Keywords: Pilonidal sinus, Rhomboid excision, Modified Limberg's flap. (JPMA 64: 1270; 2014)

Introduction

Pilonidal sinus disease affects young adults commonly between age range of 17-38 years.¹ It causes discomfort that may interfere with daily life or employment, sometimes for prolonged periods. Aetiology of this disease is uncertain but relates to the implantation of loose hair in to the depth of the natal cleft. Factors that influence the condition are the nature of hairs, force of implantation and vulnerability of the skin. Obese individuals having deeper inter-gluteal grooves and excessive hair are found to be more commonly affected.^{2,3} It appears most frequently in Sacrococcygeal (natal cleft) region. However, rarely it may be located in the axilla, umbilicus, pubis, inter-mammary region, scalp, ear, amputation stumps, genital tracts of both men and women, inter-digital webs of hairdressers, and hands of farmers who shear sheep.⁴

Common presenting complaints include pain, swelling and discharge when these sinuses become infected.⁵ Despite surgical therapy, dating back more than a century, management remains controversial. The management of pilonidal sinus is frequently unsatisfactory. No current method satisfies all the necessary requirements for the

ideal treatment, namely rapid healing, minimal hospital admission, minimal patient inconvenience, and low recurrence. Conservative non-operative management, closed methods, laying open of the track, wide excision and open drainage, wide excision and primary closure and limited excision are the methods currently used.⁶ Studies have shown that Rhomboid excision and Modified Limberg's flap closure can be performed for managing primary or recurrent pilonidal sinus with a low complication rate, short hospital stay, short time to return to normal activity, and good long-term results.⁷

We hypothesised that there is no difference between excision with direct primary closure and local transpositional Modified Limberg's flap closure in the treatment of sacrococcygeal pilonidal disease as regards to post-operative complications.

The objective of the study was to compare the outcome of Rhomboid excision and Modified Limberg's flap closure with that of excision and direct primary closure for the treatment of sacrococcygeal pilonidal sinus.

Patients and Methods

The study was conducted at the Surgical Department of Mayo Hospital, Lahore, from 2009 to 2012. A total of 60 patients were randomly divided into two equal groups using the lottery method to prevent selection bias. Outcome measurements were complication rates,

¹Mayo Hospital, ^{2,3,5,6}Services Institute of Medical Sciences, ⁴National Hospital & Medical Centre, Lahore.

Correspondence: Asad Ali Toor. Email: toor.asad@gmail.com

including infection and recurrence, hospital stay, and time to return to normal activity. Patients over 13 years of age with sacrococcygeal pilonidal sinus were included. Patients with recurrent pilonidal sinus were excluded.

Patients were admitted through outpatient department (OPD) and detailed data was noted, including demographic information, socioeconomic status and profession. The patients were asked about the symptoms, duration and severity, and examined for the severity of the problem and any previous surgical treatment for pilonidal sinus. Informed consent was obtained from the patients and approval was granted by the institutional ethics review committee. Patients were then operated by Rhomboid excision and Modified Limberg's Flap technique with a closed suction drain and were allocated as group 1. The other ones were operated by excision and primary closure over a drain and were placed in group 2 (Figure). Both groups were followed up for twelve months (after one week, two weeks, six months and twelve months) for surgical complications of the treatment, including post-operative infection, and recurrence, duration of hospital stay and return to work.

Data was analysed using SPSS 17. Descriptive analysis was done for demographic variables. T-test was applied to quantitative variables. Variables analysed were post-operative infection, length of hospital stay, recurrence and return to normal activity.

Results

Each group had 30(50%) patients. In group 1 there were 27(90%) males and 3(10%) females, while group 2 had 28(93.3%) males and 2(6.7%) females.

In group 1, discharging sinuses were reported in 23(76.7%) patients, 3(10%) complained of swelling and 4(13.3%) had pain. In group 2, 20(66.7%) patients presented with discharging sinus, 6(20%) had swelling and 4 (13.3%) had pain (Table-1).

In group 1, 2 (6.6%) patients had infection and 1(3.3%) presented with recurrence. In group 2, 8 (26.6%) patients

Figure-A: Elliptical excision

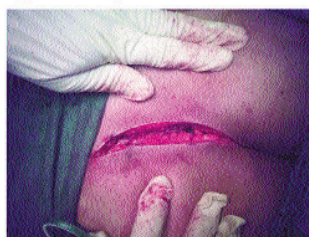

Figure-B: Primary closure with drain

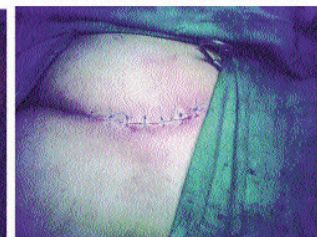

Figure-C: Rhomboid excision of the Limberg's flap

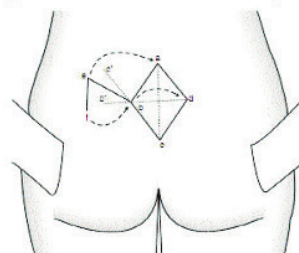


Figure-D: Modification in Limberg's flap




Figure-E: Final view of modified Limberg's flap.

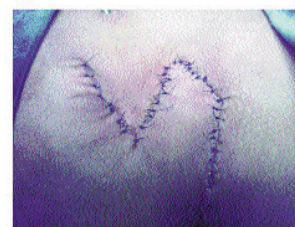

Table-2: Post-operative complications (n = 60).

| Postoperative complication | Modified Limberg's Procedure | | Primary Closure | |
|----------------------------|------------------------------|------------|-----------------|------------|
| | No. of patients | Percentage | No. of patients | Percentage |
| Infection | 2 | 6.6 | 8 | 26.6 |
| Recurrence | 1 | 3.3 | 4 | 13.3 |

had infection and 4(13.3%) had recurrence (Table-2). The mean hospital stay was 1.63±0.67 days in groups 1 and 2.8±1.24 days in group 2. Statistically, the difference between the hospital stay was significant (p<0.04).Patients returned to work within 13.43±1.52 days

Table-1: Frequency distribution of patients (n=60).

| Local finding | Modified Limberg's Procedure | | Primary Closure | |
|----------------------------|------------------------------|------------|-----------------|------------|
| | No. of patients | Percentage | No. of patients | Percentage |
| Redness | 4 | 13.3 | 4 | 13.3 |
| Swelling | 3 | 10.0 | 6 | 20.0 |
| Discharging sinus | 23 | 76.7 | 20 | 66.7% |
| Tuft of hairs | 26 | 86.7 | 25 | 83.3 |
| Multiple tracks | 27 | 90.0 | 28 | 93.3 |
| Multiple external openings | 25 | 83.3 | 24 | 80.0 |

Table-3: Comparison of Mean Hospital Stay and Mean time to return to work (n=60).

| Postoperative complication | Modified Limberg's Procedure | Primary Closure | P-value |
|------------------------------------|------------------------------|-----------------|---------|
| Mean hospital Stay (days) | 1.63 ± 0.67 | 2.8 ± 1.24 | P<0.04 |
| Mean time to return to work (days) | 13.43 ± 1.52 | 15.7 ± 4.09 | p<0.05 |

in group 1 and 15.7±4.09in group 2 (p<0.05) (Table-3).

Discussion

Simple excisional techniques are associated with high morbidity and recurrence owing to the continuing presence of the natal cleft. Recurrence rates of 7-42 percent have been reported following excision and primary closure^{8,9} which in our study was 13% while 0-5 percent recurrence has been reported in literature after Rhomboid excision and Modified Limberg's flap closure³ which was about 3% in our study. Researchers have concluded that flap reconstruction was superior to excision and primary closure for pilonidal disease and Modified Limberg's flap was superior with regards to wound infection and recurrence.¹⁰⁻¹³ In this study, same trend was observed). Post-operative infection rate is 4 times higher after primary closure.

A study reported on 100 consecutive age and gender matched patients, while comparing both techniques, that quality of life improved by shorter hospital stay, earlier healing, shorter time of work, lower rate of complications, lower pain perception and improved general health were the main advantages of Modified Limberg's flap in pilonidal surgery.¹⁴ All together these parameters added to patient's comfort and satisfaction after surgical treatment. Another study showed that morbidity developed in 24 patients treated by primary excision (infection rate was 10, flap oedema 13, wound dehiscence 5), whereas only 3 patients had these morbidities after Modified Limberg's flap procedure (infection 2 and flap oedema 1). Eleven patients had recurrence after primary closure and no recurrence for Modified Limberg's flap.¹¹

Recurrence and complications are associated with obesity as in our study obese patient with body mass index (BMI) >35 had prolonged drain output and hospital stay as well as complications occurred more frequently than non-obese patients.^{3,6,15}

Hospital stay depends not only on healing time, but also on hospital discharge policy e.g., day-care surgery or specific discharge days. A study noted hospital stay of 1 to 2 days for Modified Limberg's flap; while another reported that the mean hospital stay was 7.9 days. One study concluded hospital stay of 3.1±0.30 days. The patients in other studies¹⁶⁻¹⁹ had hospital stay of 4.1 days. While

comparing both procedures, one study found it to be 2.9 days for Modified Limberg's flap and 4.8 days for primary closure. In this study the mean hospital stay was 1.6±0.67 days for Modified Limberg's flap and 2.8±1.24 days for primary closure which is quite significantly comparable with other studies.¹⁶⁻¹⁹

Conclusion

Although the study had a small number of patients and short follow-up period, but it can be safely said that for primary sacrococcygeal pilonidal sinus disease, Rhomboid excision with Modified Limberg's transposition flap is an effective treatment in terms of its low complication rate, a short hospital stay, short time to return to normal activity, low recurrence rate, patient comfort and good long-term results.

Acknowledgement

We are grateful to Prof. Muhammad Arshad Cheema for his guidance.

References

1. Shah A Waheed A, Malik A. Recurrence rates in pilonidal sinus surgery comparison of two techniques (Karydakis versus conventional open excision). *Pak Journal Medical and Health Sci* 2009; 3: 41-8.
2. Rafi Y, Butt TM, Rehman HA, Rafiq K, Chaudhary AM. Pilonidal disease: a conservative approach to the problem. *Ann King Edward Med Uni* 2001;7: 83-4.
3. Cubukcu A, Gonullu NN, Paksoy M, Alponat A, Kuru M, Ozbay O. The role of obesity on the recurrence of pilonidal sinus disease in patients, who were treated by excision and Limberg flap transposition. *Int J Colorectal Dis* 2000; 15: 173-5.
4. Chaudhary ZA, Akhter MJ, Rafi Y, Syed AS, Chaudhary AM. Primary closure after pilonidal sinus excision. *Ann King Edward Med Uni* 1997; 2: 9-10.
5. Adanali G, Senen D, Tuncel A, Ibrahimoglu D, Erdogan B. Squamous cell carcinoma developing in a pilonidal sinus. *Plast Reconstruct Surg* 2002; 110: 1367-8.
6. Mohamed HA, Kadry I, Adly S. Comparison between three therapeutic modalities for non-complicated pilonidal sinus disease. *Surgeon* 2005; 3: 73-7.
7. Chintapatla S, Safarani N, Kumar S, Haboubi N. Sacrococcygeal pilonidal sinus: historical review, pathological insight and surgical options. *Tech Coloproctol* 2003; 7: 3-8.
8. Urhan MK, Kucukel F, Topgul K, Ozer I, Sari S. Rhomboid excision and Limberg flap for managing pilonidal sinus: results of 102 cases. *Dis Colon Rectum* 2002; 45: 656-9.
9. Sondenaa K, Nesvik I, Andersen E, Natas O, Soreide JA. Bacteriology and complications of chronic pilonidal sinus treated with excision and primary suture. *Int J Colorectal Dis* 1995; 10: 161-6.

10. Mahdy T. Surgical treatment of the pilonidal disease: primary closure or flap reconstruction after excision. *Dis Colon Rectum* 2008; 51: 1816-22.
 11. Akca T, Colak T, Ustunsoy B, Kanik A, Aydin S. Randomized clinical trial comparing primary closure with the Limberg flap in the treatment of primary sacrococcygeal pilonidal disease. *Br J Surg* 2005; 92: 1081-4.
 12. Iesalnieks I, Furst A, Rentsch M, Jauch KW. [Primary midline closure after excision of a pilonidal sinus is associated with a high recurrence rate]. *Chirurg* 2003; 74: 461-8.
 13. Eryilmaz R, Sahin M, Alimoglu O, Dasiran F. Surgical treatment of sacrococcygeal pilonidal sinus with the Limberg transposition flap. *Surg* 2003; 134: 745-9.
 14. Ertan T, Koc M, Gocmen E, Aslar AK, Keskek M, Kilic M. Does technique alter quality of life after pilonidal sinus surgery? *Am J Surg* 2005; 190: 388-92.
 15. Arda IS GL, Sevmi? S, Hiçsönmez A. High body mass index as a possible risk factor for pilonidal sinus disease in adolescents. *World J Surg* 2005; 29: 469-71.
 16. Milito G, Morco G, Gallinella MM, Crocoli A, Spyrou M, Farinon AM. Modified Limberg's transposition flap for pilonidal sinus. Long term follow up of 216 cases. *Ann Ital Chir* 2007; 78: 227-31.
 17. Misiakos EP, Troupis T, Hatzikokolis S, Macheras A, Liakakos T, Patapis P, et al. Limberg flap reconstruction for the treatment of pilonidal sinus disease. *Chirurgia (Bucur)* 2006; 101: 513-7.
 18. Jaschke CW, Mahrlein R, Mangold G. [Results of the Limberg transposition flap in the treatment of pilonidal sinus]. *Zentralblatt Fur Chirurgie* 2002; 127: 712-5.
 19. Bozkurt MK, Tezel E. Management of pilonidal sinus with the Limberg flap. *Dis Colon Rectum* 1998; 41: 775-7.
-