

# CARDIO-AUDITORY SYNDROME: CASE REPORTS AND EPIDEMIOLOGICAL STUDY

Pages with reference to book, From 159 To 163

Muhammad Ilyas, Sher Muhammad Khan, S.M. Husnain Sherazi, Mukammal Shah, Anwar-ul-Hassan ( Muhammadi Hospital, Peshawar. )

## Abstract

Four cases of cardioauditory-syndromc arc reported in the adults, 3 males and one female, age range 16-45 years (mean 28 years). Two cases required permanent pacemaker implantation for resistant syncopal attacks. Fourteen close relatives of these two cases were studied for electrocardiographic abnormalities and one female, 45 years old, showed prolonged Q-T interval without deafness. The other two cases demonstrated ectopic beats and tachycardia.

In a survey of 176 deaf-mute children long Q-T interval syndrome (LQTI) was found in 11 children (6.3%) in 4 children (2.3%) it was present at rest only, in another 4 children (2.3%) it developed after exercise, while it was present both at rest and after exercise in 3 children (1.7%). Long Q-T syndrome (LQTS) was found in 4 children (2.3%) (JPMA 30:159, 1980).

## Introduction

Cardio-auditory syndrome or surdo-cardiac syndrome characterised by cardiac conduction disturbances associated with congenital deafness was first reported by Jervell and Lange-Nielson (1959). The cardiac conduction disturbances include prolonged C-T interval, dysrhythmias including heart block, syncopal attacks, and sudden death in infants (Fraser et al., 1964). This syndrome in the absence of deafness has been described as Romano-Ward Syndrome (Romano et al., 1963; Ward, 1969). This syndrome usually manifests in the infancy and childhood but may appear in adults (Mathews et al., 1972).

We report 4 cases of cardioauditory syndrome with deafness manifesting in the adulthood; two cases presented with syncopal attacks, one with complete A-V block and the other with sick sinus syndrome, and in both these cases permanent cardiac pacing was carried out.

A study for long Q-T interval (LQTI) and the long Q-T syndrome (LQTS) in families of these cases, and from an epidemiological survey in deaf-mute children is also reported.

## Material and Methods

Two cases of congenital deafness who presented with syncopal attacks are reported, and 14 close blood relatives of these two cases were also studied for Q-T interval abnormality. Two other cases with congenital deafness and cardiac conduction disturbance are also described. The school study included 176 deaf-mute children from Peshawar, Abbottabad and Rawalpindi.

## Case Reports

### Case No. 1

Mr. S.B.K., a 16 years young man, from Peshawar presented in the out-patient department of the Muhammadi Hospital, Peshawar on January 5, 1976 with prolonged syncopal attacks, and gave a history of syncopal attacks for 6 months, increased in the past one week. He also gave a history of

palpitation and generalised weakness for 8 months and deafness since birth.

On examination nerve deafness and low I.Q. were demonstrated. The pulse was 30 minutes, blood pressure 100,70 syncopal attacks were observed during examination. Investigations: haemoglobin 80%, serum urea 35 mg 100 ml and serum potassium 4.5 meq L. Chest X-ray showed increased cardiothoracic-ratio and electrocardiogram showed complete atrioventricular dissociation with atrial rate 82/min and ventricular rate 30/min and syncopal attacks demonstrated ventricular asystole. Atropine 2 mg administered intravenously showed no effect and response to sublingual and oral long acting isoprenaline was unsatisfactory. In view of recurrent prolonged syncopal attacks a transvenous right ventricular endocardial pacing was carried out on the day of admission, and because of persistent heart block a Medtronic 5944 ventricular inhibited demand pacemaker was implanted on January 13, 1976 (Fig. 1).



Fig. 1. Mr. S.B.K., a. complete heart block, b. right ventricular endocardial pacing.

The heart size regressed to normal and he was discharged home on January 28, 1976.

#### Case No. 2

Mr. M.A.K., 35 years old, an Afridi tribesman from Dara Adam Khel, presented in the Muhammadi Hospital, Peshawar on April 23, 1976 with history of syncopal attacks for 4 weeks and palpitation with fatigue feeling for 6 years, and deafness since birth.

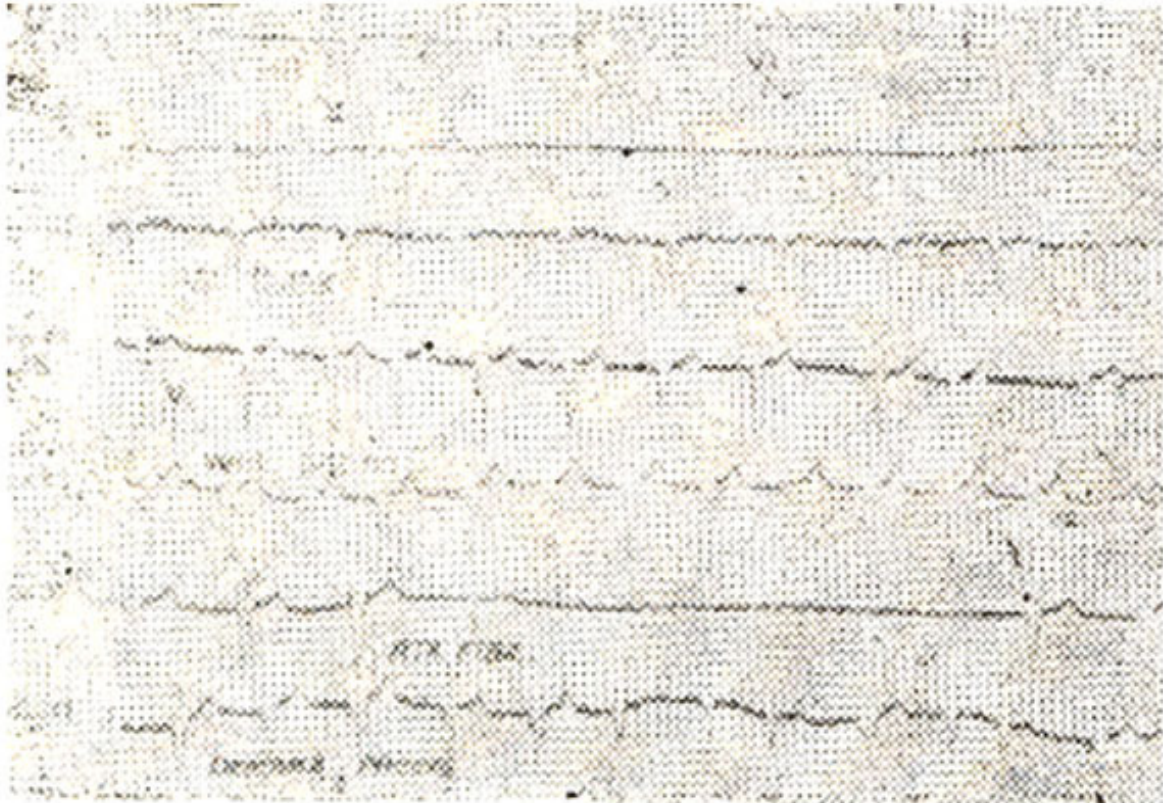
On examination, even deafness was demonstrated; the pulse was 40 per minute and blood pressure 110/70 mg Hg. During examination prolonged syncopal attacks with convulsions and anginal chest pain were observed. Investigations: haemoglobin 95°C, serum urea 40 mg per 100 ml., serum creatinine 1.4 mg per 100 ml and serum potassium 5 meq/L. Chest X-ray showed increased cardiothoracic ratio and electrocardiogram showed complete atrioventricular dissociation with varying atrial rate of 100-120 per minute and ventricular rate 30 per minute. Intravenous atropinisation produced no effect and he responded poorly to sublingual and long acting isoprenaline table I.

Table I: Clinical Analysis of Cardioauditory Syndrome

Case No.	Age Years	Sex	Deafness	Symptoms	ECG	Q-Tc sec.	Follow-up
1. S.B.K.	16	M	+	Syncopal Episodes	CHB	—	PACING
2. M.A.K.	35	M	+	Palpitations	SSS	—	PACING
3. S.A.	43	F	+	Palpitations	SSS AE	0.45 0.40	DIAZEPAM
4. S.K.	17	M	+	Palpitations	PSVT AE	0.45 0.46	DILANTIN
5. I.K.	56	F	—	Syncopal episodes	SSS RWS	0.52	SAVENTRINE

RWS: Romano-Ward Syndrome, CHB: complete heart block, SSS: sick sinus syndrome, AE: After exercise.

Over the course of the next few days a variety of rhythm disorders were recorded (Fig. 2);



*Fig. 2.* Mr. M.A.K., a. complete atrioventricular dissociation, b. nodal rhythm with atrial standstill, c. atrial flutter, d. irregular sinus rhythm with nodal escape beats, e. right ventricular pacing, f. underlying atrial fibrillation with asystole, g. demand pacing.

including complete S-A block with nodal escape rhythm and atrial standstill (April 24), atrial flutter (April 25) and unstable sinus rhythm with nodal escape beats (April 26). Transvenous right ventricular endocardial pacing was carried out on April 28 and on April 30 atrial fibrillation with complete heart block also recorded. A Medtronic 5944 ventricular inhibiting demand pacemaker was implanted on May 18, and he was sent home on June 3, 1976.

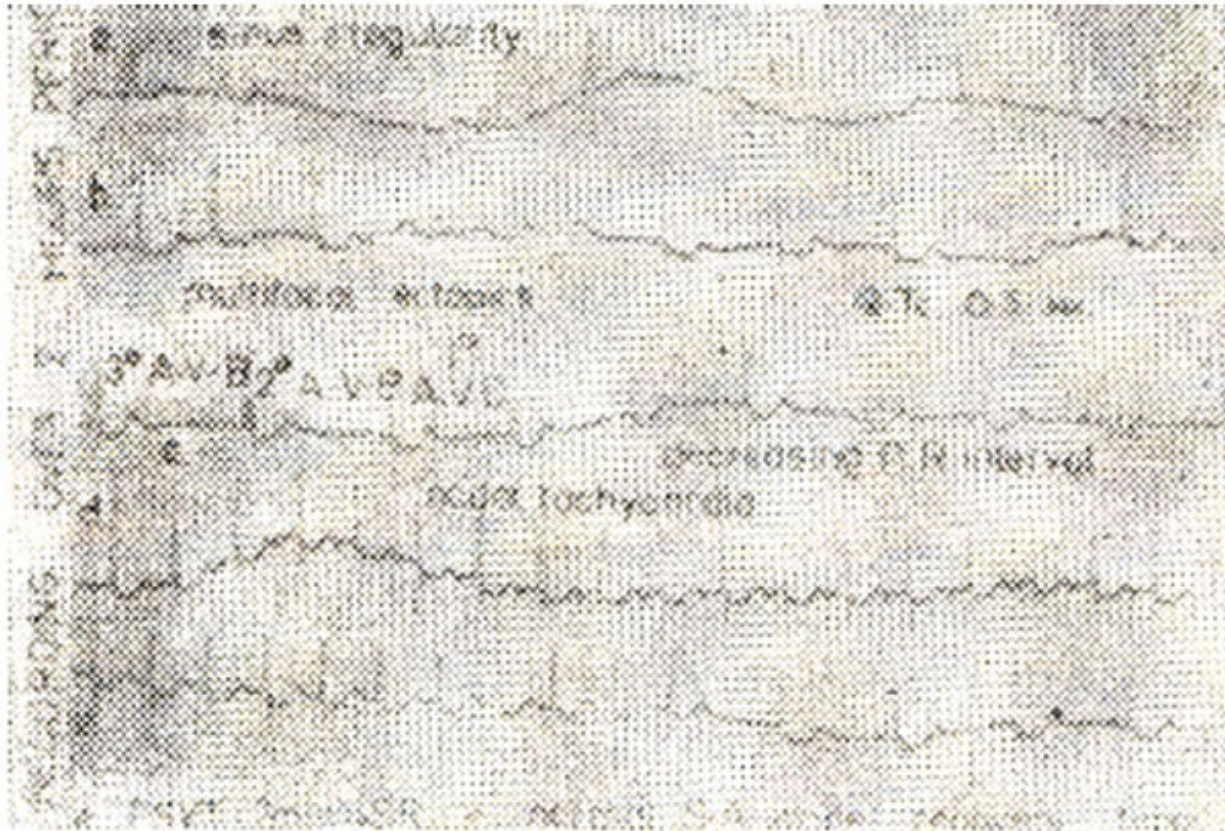
#### **Family Study**

7 close blood relatives for Case 1, parents and siblings, were examined for cardiac conduction disturbance but no abnormality was recorded and Q-T interval was normal in all these subjects. 7 close blood relations of Case 2, parents and siblings, were also examined for cardiac conduction disturbance. One aunt, Mrs. S.F. 45 years, showed prolonged Q-T interval of 0.44 sec.

#### **Case No. 3**

Mrs. S.A., 45 years, with congenital deafness since childhood presented with history of shortness of breath and palpitation on May 28, 1975. On examination she was found to have congestivecardiac

failure. Chest X-ray showed cardiac enlargement and marked pulmonary venous congestion. Electrocardiogram showed corrected T-Q interval of 0.5 sec with sinus irregularity, multifocal ectopics and varying A-V block. A run of nodal tachycardia, at the rate of 150 per minute lasting for 7 minutes, simulating rapid atrial pacing, was also recorded which sinoverted spontaneously without delayed sinus node recovery time (Fig. 3).

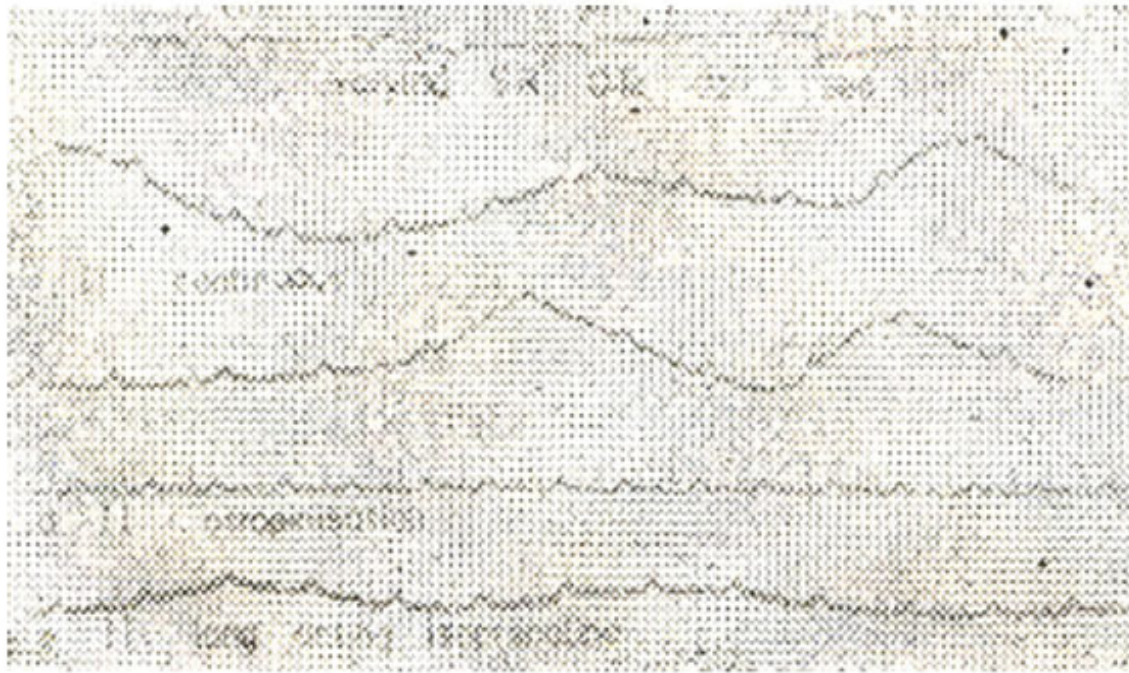

*Fig. 3.* Mrs. S.A., a. sinus irregularity, b. multifocal ectopics (Q-Tc 0.5 sec.), c. varying atrioventricular block, d-e (continuous): nodal tachycardia (7 minutes) terminating spontaneously into sinus rhythm with normal sinus node recovery time.

These changes were recorded over two hours period. She was digitalised with control of failure but the sick sinus syndrome did not resolve completely.

#### **Case No. 4**

Mr. S.A.K., 17 years, with congenital deafness, presented with complaints of episodes of palpitations on July 7, 1977. Electrocardiogram showed a corrected Q-T interval of 0.45 sec at rest and this increased to 0.46 sec after exercise (Fig. 4a).



*Fig. 4. Mr. S.A.K. 17 years: a. prolonged Q-Tc 0.45 sec., b and c. sinus irregularity, d and e. normalisation with atropine and isoprenaline.*

At times, sinus irregularity was recorded, which normalised with atropine and isoprenaline (b.c.d.e). Episodes of supraventricular tachycardia were also recorded. The patient was given phenytoin-sodium (DILANTIN) 100 mg three times a day which controlled the paroxysm of ectopic tachycardia.

#### **Epidemiological Study**

Deaf-mute children from four Deaf-Dumb schools in Peshawar, Abbottabad and Rawalpindi have been surveyed for electrocardiographic abnormality of Q-T interval prolongation. Following physical examination, a 12 lead electrocardiogram was recorded, and a long lead II rhythm strip was recorded which was repeated after exercise. Corrected Q-T interval (Q-Tc) was calculated from Bazett's formula:

#### **Q-Tc: Q-T interval**

#### **R-R interval**

The series included 176 children, 129 males and 47 females, age range 8-15 years, mean 12 years. Children with corrected Q-T interval of 0.45 seconds or more were regarded to have long Q-T interval (LQTI). 11 children (6.3%) had LQTI, either at rest or after exercise: 4 children (2.3%) had LQTA, at rest, in 4 children (2.3%) this developed only after exercise and in 3 children (1.7%) it was recorded both at rest and after exercise (Table II).

Table II: Long Q-T Interval and Syndrome.

Long Q-T Interval (LQTI)  
D & D N. 196 Q-Tc  $\geq$  0.45 sec.

<i>Before Exercise</i>	<i>After Exercise</i>	<i>Before and After Exercise</i>
4 (2.3%)	4 (2.3%)	3 (1.7%)
T. 11/176 Long Q-T Syndrome (LQTS) (LQTI+Syncope) 4/176 (2.3%)	(6.3%)	

One child also demonstrated isolated first degree A-V block (R-R interval 0.2 sec).  
The long Q-T syndrome (LQTS) i.e. deaf-mutism associated with prolonged Q-T interval and syncope, was found in 4 children (2.3%), Fig. 5.



Fig. 5. A male 8 years old deaf-mute boy with syncopal episodes: Lead 2, a. At rest, Q-Tc 0.52 sec., b. After exercise, paradoxically increased Q-Tc 0.60 sec.

**Discussion**

We have seen four cases of cardioauditory syndrome with congenital deafness and cardiac

dysrhythmias. One female Mrs. I.K. 55 years, with long Q-T syndrome (Q-Tc 0.52 sec) and sick sinus syndrome without deafness (Romano-Ward Syndrome) has not been included in this report (Table 1). Our series include cases presented in older age group and two of these required permanent pacemaker implantation. Mathews et al (1972) have also reported cases manifesting in the adulthood.

In a survey of 178- deaf-mute school children we found long Q-T interval (LQTI) in 11 children (6.3%) and long Q-T syndrome (LQTS) in 4 children (2.3%). The data on LQTS is not known from the Afro-Asian countries, and it may be similar to that of S-T variant, another repolarisation disorder, with well marked racial variation. 7.4% of adult male population in India (Srikantia et al., 1968) and 25% adult male negro population (Grusin, 1954) (2.3%) have been reported to have S-T variant.

Schwartz et al (1975) reviewed the world literature on long CVP syndrome (LQTS) and observed that 170 out of 200 cases were reported in the previous 5 years, indicating increasing awareness about this condition.

Pathogenesis of long Q-T syndrome is unknown but it is postulated to be due to abnormalities in the vascularisation of the sinus node or due to adrenergic overstimulation (Mass and McDonald, 1971). Pharmacologic blockade of stellate ganglion has produced shortening of Q-T interval in some cases and prolongation in other (Mass and McDonald, 1971; Vincent et al., 1974). Q-T interval may be prolonged after exercise probably due to abnormal response to sympathetic stimulation and some alterations in the T Wave may be demonstrated after exercise (Schwartz, 1974). The mode of inheritance of long Q-T syndrome when associated with nerve deafness appears to be autosomal recessive (Fraser et al., 1964), and autosomal dominant in the absence of deafness (Barlow et al., 1964; Hashiba, 1978; Wan Chun et al., 1978).

Therapy of long Q-T syndrome consists of the management of associated dysrhythmias. Beta-blocker drugs and diphenylhydantoin have been recommended for control of dysrhythmia (Schwartz, 1973; Rosen et al., 1967). In our series, in Case No. 4 (Mrs. S.A.K.), phenytoin-sodium controlled the episodes of supraventricular tachycardia, and two cases required permanent pacemaker implantation. Roy et al (1976) have also reported pacemaker implantation in a 9 year child with deafness and long Q-T syndrome with 2:1 A-V block and episodes of ventricular fibrillation.

## Acknowledgement

This work was supported by a Research Grant from the Pakistan Heart Foundation. We are also indebted to Mr. Muhammad Iqbal, Mr. Abdul Rashid, Miss Gulshan Ara, and to the Teachers of the Deaf-Mute Schools.

## References

1. Bazett, H.C. (1920) An analysis of the time-relations of electrocardiograms. *Heart*, 7:353.
2. Barlow, J.B., Bosman, C.K. and Cochrane, J.W. (1964) Congenital cardiac arrhythmias. *Lancet*, 2:531.
3. Dolara, A., Tordini, G., Dellocubio, J. et al.(1971)Sindromi cardioauditive: Studies di 262 sordomati, *Giorn. It. Cardiol.*, 1:214.
4. Fraser, G.R., Froggatt, P. and James, T.N. (1964) Congenital deafness associated with electrocardiographic abnormalities, fainting attacks and sudden death. *Quart. J. Med.*, 33:361.
5. Fraser, G.R., Frogatt, R. and Murphy, T. (1964) Genetic-aspects of cardioauditory syndrome of Jervell and Lang Nielsen (Congenital deafness and electrocardiographic abnormalities). *Ann. Hum. Genet.*, 28-133.
6. Grusin, M.B. (1954) Peculiarities of the Africans electrocardiogram and the changes observed in serial studies. *Circulation*, 9:860.

7. Hashiba, Kunitake. (1978) Hereditary QT prolongation syndrome in Japan. *Jap. Cir. J.*, 42:1133.
8. Jervell, A., Lange-Nielson, F. (1959) Congenital deaf-mutism, functional heart disease with prolongation of the Q-T interval and sudden death. *Amer. Heart J.*, 54:59.
9. Jervell, A. (1971) Surdocardiac and related syndromes in children. *Adv. Intern. Med.*, 17:425.
10. James, J.N. (1969) Q-T prolongation and sudden death. *Mod. Cone. Cardiovas. Dis.*, 38:35.
11. Maron, B.J., Clarke, C.E., Goldsteins, R.E. and Epstein, S.E. (1976) Potential role of QT interval prolongation in sudden infant death syndrome. *Circulation*, 54:423.
12. Mathews, E.C. Jr., Blount, A.W. Jr., Townsend, J.I. (1972) Q-T prolongation and ventricular arrhythmias, with and without deafness, in the same family. *Am. J. Cardiol.*, 29:702.
13. Moss, A.J. and McDonald, J. (1971) Unilateral Cervico thoracic sympathetic ganglionectomy for the treatment of long Q-T syndrome. *N. Engl. J. Med.*, 285:903.
14. Pernet, C, Henry, M., Aigle, J.C. (1972) Syndrome cardioauditoy de Jervell at Torsades de piointes. *Arch. Mal. Coeur.*, 65:261.
15. Rosen, M., Lisak, R. and Rubin, K. (1967) Diphanylhydantion in cardiac arrhythmias. *Amer. J. Cardiol.*, 20:674.
16. Romano, C, Gemme, G. and Pongiglions, R. (1963) Aritmie cardioche rare dell'eta pediatrica. *Clin. II. Auessi Sincopaliper fibrillazion ventricolare parossistica. (Pre-zentazion del Primo caso della letterature Pediatrica Italiana) Pediat.*, 45:656.
17. Roy, P.R., Emanuel, R., Ismail, S.A. and Tayib, M.H. (1976) Hereditary prolongation of the Q-T interval: Genetic observations and management in three families with twelve affected members. *Am. J. Cardiol.*, 37:337.
18. Srikantia, S.G., Padmavati, S., Gopalan, C. (1964) The electrocardiogram in some Indian population groups. *Circulation*, 29:118.
19. Sanchez-Cascos, A., Sanchez-Horguindey, L., De Rabago Cardio-auditoy syndrome: cardiac and genetic study *Brit. Heart J.*, 31:26, 1969.
20. Schwartz, P.J., Periti, M., Malliani, A. (1975) The long Q-T Syndrome. *Am. Heart J.*, 89:378.
21. Schwartz, P.J., Malliani, A. (1974) Electrical alterations of the T-Wave: Clinical and experimental evidence of its relationship with the sympathetic nervous system and with long Q-T syndrome. *Am. Heart J.*, 89:45.
22. Schwartz, P.J. The role of beta blockade in therapy of long Q-T syndrome. In *Symposium on Beta-blocking Agent*, Alghero. Italy, 1973.
23. Vincent, G.M., Abildskov, J.A., Burgess, M.J. and Millar, K. (1974) Autonomic manipulation in the inherited long Q-T recurrent syncope syndromes. *Am. J. Cardiol.*, 33:174.
24. Ward, G.C. (1969) New familial cardiac syndrome in child-dren. *JAMA.*, 54:103.
25. Wan-chun, Chen, and Mao-teh, Hus. (1978) Long Q-T syndrome in three siblings of one family. *Chinese Med. J.*, 4:487.