

Extra-Nodal Non-Hodgkin's Lymphomas: A Morphological Study of 23 Patients

Pages with reference to book, From 72 To 75

Khalid Hassan (Al-Nasser Polyclinic, Tabuk, Saudi Arabia.)

A.H. Nagi (Allama Iqbal Medical College, Lahore.)

A.Hayee (King Edward Medical College, Lahore.)

Abstract

A morphological study of 23 cases of extra-nodal non-Hodgkin's lymphomas is presented. The disease was most prevalent in the second decade (30.4%), followed by fourth and fifth decades (26.1%) and seventh decade of life (13.1%), respectively. The male: female ratio was 1.1:1. The commonest primary site of lymphoma was bones, followed by pharynx, skin and other organs. Histologically, according to W.H.O.'s classification of lymphomas (1978), lymphoblastic lymphosarcoma was the commonest (65%), followed by reticulosarcoma (18.8%) and lymphocytic lymphosarcoma (8.7%). Burkitt's lymphosarcoma and Mycosis fungoides were the least common (4.3% each). (JPMA 32:72, 1982).

Introduction

Although the lymphomas usually arise from lymph nodes, in some instances, they may arise primarily at extranodal sites (Rappaport, 1966; Freeman, 1972; Heilman, 1975). Initial extranodal involvement has been observed in 71% (Kim, 1977) to 36% (Reddy, 1977) of adult patients of non-Hodgkin's lymphomas. According to other investigators, the incidence was 8.7% (Goffinet, 1973), 14% (Lotz, 1976) and 24% (Freeman, 1972). Extranodal presentation is more common in children. Wollern (1976) observed initial extra-nodal lymphoma in 53.5% of childhood patients. Skin is a frequent site of primary extranodal involvement (Kim, 1974; Nordqvist, 1975; Edelsen, 1975). The initial clinical signs of lymphoma may be a testicular mass, especially over the age of 50 years (Hamlin, 1971; Tenasbaum, 1972; Wolley, 1976). Pharynx and gastrointestinal tract are not infrequently involved sites (Al-Saleem, 1970; Him, 1974; Hellman, 1975). Other documented primary extra-nodal sites are breast (Freeman, 1972; Wiseman, 1972), bones (Jones, 1973; Hellman, 1975), spleen, (Montanaro 1976), gall bladder (Van Slyck, 1973), salivary glands (Nime, 1976), tongue, uterus and nose (Freeman, 1972).

Materials and Methods

Selection of Patients: Patients showing the following types of features were selected for biopsy from the site of involvement:

- (i) Organomegaly, e.g., of testis, parotid gland, liver and tonsils.
- (ii) Masses at different sites, like skin, subcutaneous tissues, bone, nose, pharynx, palate, large intestine, breast, tongue and chest wall.
- (iii) Pathological fracture of femur.
- (iv) Bleeding per vaginurn (Lymphoma of uterus and cervix).

Processing of Biopsy Material

The biopsy material was fixed in formal saline for 24-48 hours. Bones were decalcified in 8% nitric acid. The tissues were hand-processed through ascending grades of acetone, and cleared in xylene. They were embedded in molten paraffin wax. Blocks were made, and multiple 3-4 micron thick sections were cut. They were stained with Haematoxylin and eosin stains. The sections were examined

under light microscope iOxrtholux II).

Results

Age anJ Sex: Age and sex incidence has been shown in figure 1.

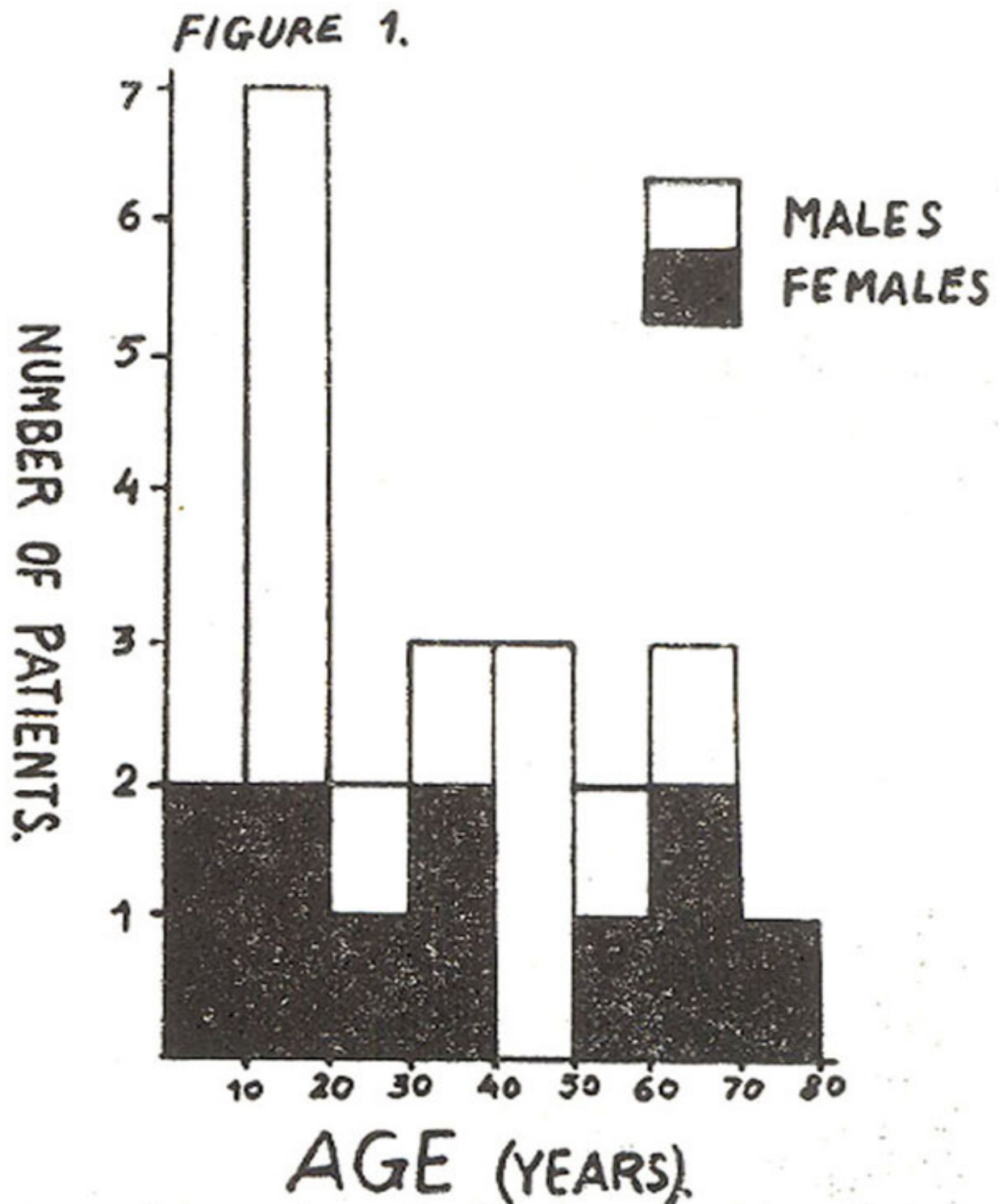


Fig. 1: Age and sex incidence of extranodal non-Hodgkin's lymphomas.

The patients presented between 2-1/2 and 75 years of age, with a peak incidence in the second (30.4%) decade of life. Whereas the male: female ratio was 1 : 1:1, above the age of 50 years, this ratio was 1:2'.

Sues of lavolvenseni: The primary sites of presentation have been detailed in table 1.

Table I
Sites of Lymphomas

<i>Sites of Lymphoma</i>	<i>NUMBER OF PATIENTS</i>					<i>Total</i>
	<i>LB</i>	<i>LC</i>	<i>RC</i>	<i>MF</i>	<i>BL</i>	
Bones						5
Iliac crest	2	—	—	—	—	2
Femur	1	—	1	—	—	2
Tibia	1	—	—	—	—	1
Pharynx						4
Nasopharynx	2	—	—	—	—	2
Laryngopharynx	—	—	1	—	—	1
Tonsils	1	—	—	—	—	1
Skin	1	—	—	1	—	2
Testis	1	—	—	—	—	1
Sub-cutaneous tissue	—	—	1	—	—	1
Chest wall	1	—	—	—	—	1
Tongue	1	—	—	—	—	1
Breast	1	—	—	—	—	1
Nose	1	—	—	—	—	1
Palate	—	—	—	—	1	1
Ethmoid	1	—	—	—	—	1
Parotid gland	—	1	—	—	—	1
Caecum and ascending colon	—	—	1	—	—	1
Liver	—	1	—	—	—	1
Uterus	1	—	—	—	—	1

Bones were the commonest site of involvement (21.7%). These patients presented with unexplainable anaemia, bone swelling (tibia) or pathological fracture (femur). The second commonest site was pharynx (17.4%). In two patients (8.7%), skin was the primary site of lymphoma. One of these two patients showed mycosis fungoides. Other tissues presenting as primary sites were testis, sub-cutaneous tissue, chest wall, tongue, breast, nose, palate, ethmoid, parotid gland, colon, liver and uterus.

Histological Presentation (Table II)

Table II

Histological Types of Extranodal non-Hodgkin's lymphomas in 23 Patients.

<i>Histological Type of Lymphoma</i>	<i>Number of Patients</i>	
	<i>Males</i>	<i>Females</i>
Lymphoblastic Lympho- sarcoma	7	8
Reticulosarcoma	3	1
Lymphocytic Lymphosar- coma	1	1
Mycosis Fungoides	—	1
Burkitt's Lymphosarcoma	1	—

For the histological typing, W.H.O.'s classification of lymphomas (1978) was followed.

Lymphoblastic lymphosarcoma was the commonest histological variant of extranodal non-Hodgkin's lymphoma (65%). On microscopic examination, the tissue showed loss of normal architecture, and was observed to be sheets of lymphoblasts (Fig. 2).




Fig. 2: Photomicrograph in a case of lymphoblastic lymphosarcoma showing proliferation of lymphoblasts. Haematoxylin and eosin stains x 500.

There was no evidence of nuclear cleavage or convolutions.

Reticulosarcoma was observed in 18% of cases. Microscopic examination showed effacement of normal tissue architecture, and infiltration by pleomorphic histiocytes (Fig. 3).

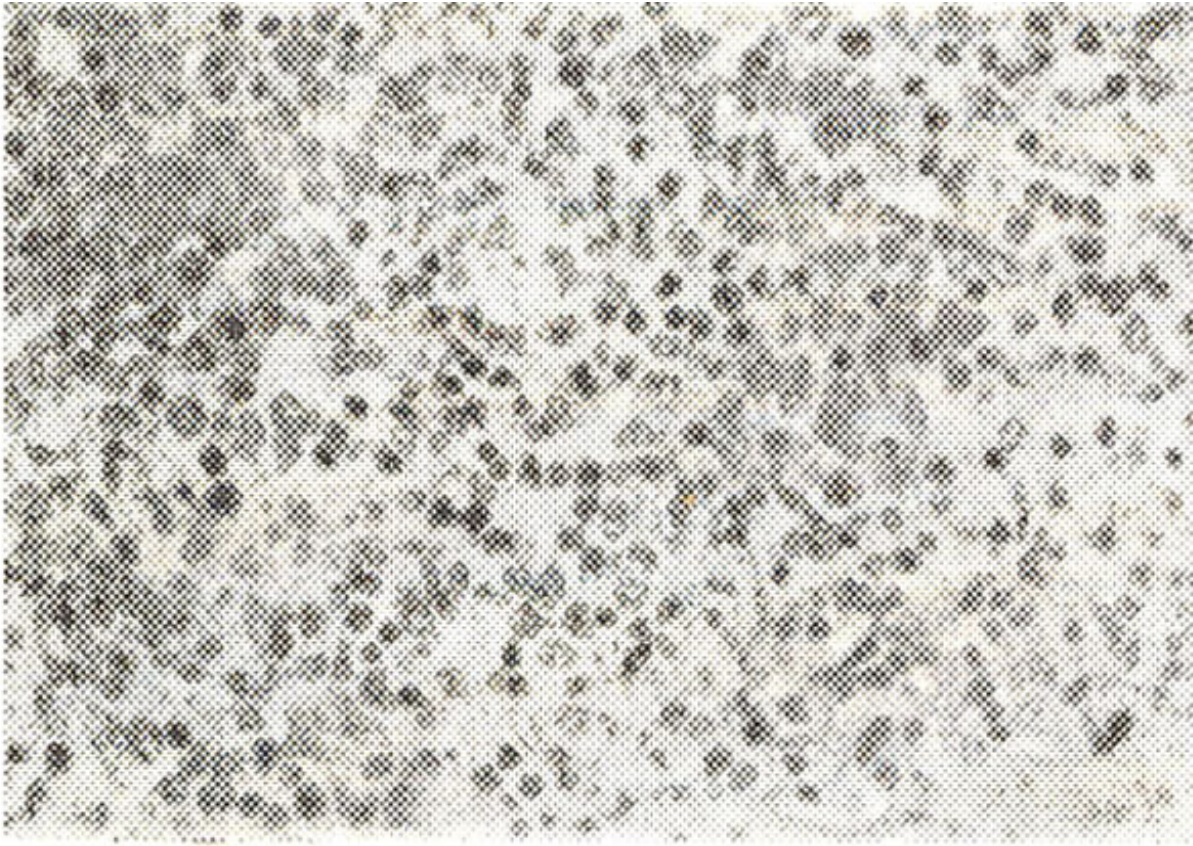


Fig. 3: Photomicrograph in a case of reticulum cell sarcoma, showing proliferation of pleomorphic histiocytes. Haematoxylin and eosin stains. x 500.

One patient showed lymphoblasts as well; these cells constituted 25% of the cells.

Lymphocytic lymphosarcoma of diffuse type was present in 8.7% of patients. The lymphomatous infiltrate comprised of mature lymphocytes, which were represented in sheets. (Fig. 4).

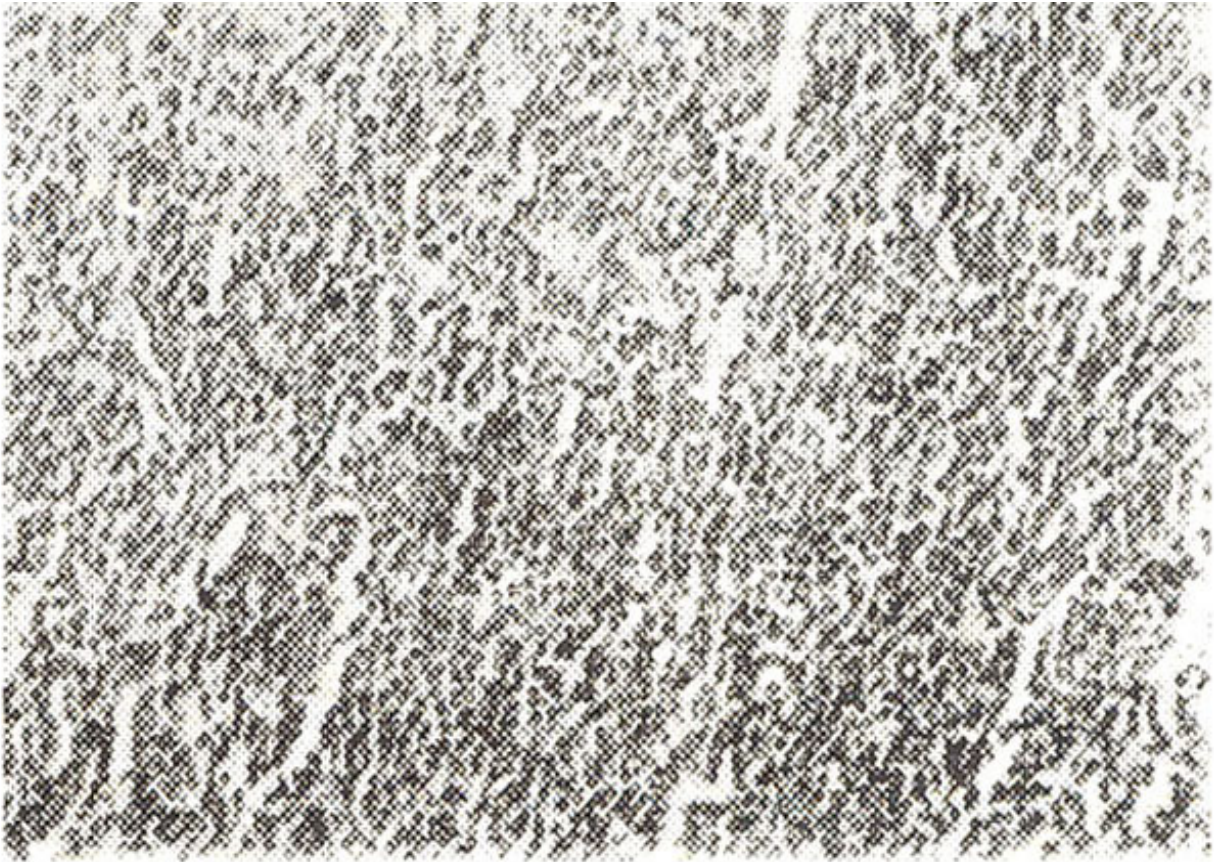

Fig. 4: Photomicrograph in a case of lymphocytic lymphosarcoma, showing proliferation of mature lymphocytes. Haematoxylin and eosin stains. x 200.

The biopsy of skin in patient with Mycosis Fungoides showed replacement of the tissue by 'Mycosis cells' (Fig. 5, 6).



Fig. 5: Photomicrograph in a case of mycosis fungoides, showing sheets of lymphoma cells, with infiltration of epidermis. Haematoxylin and eosin stains. x 200.

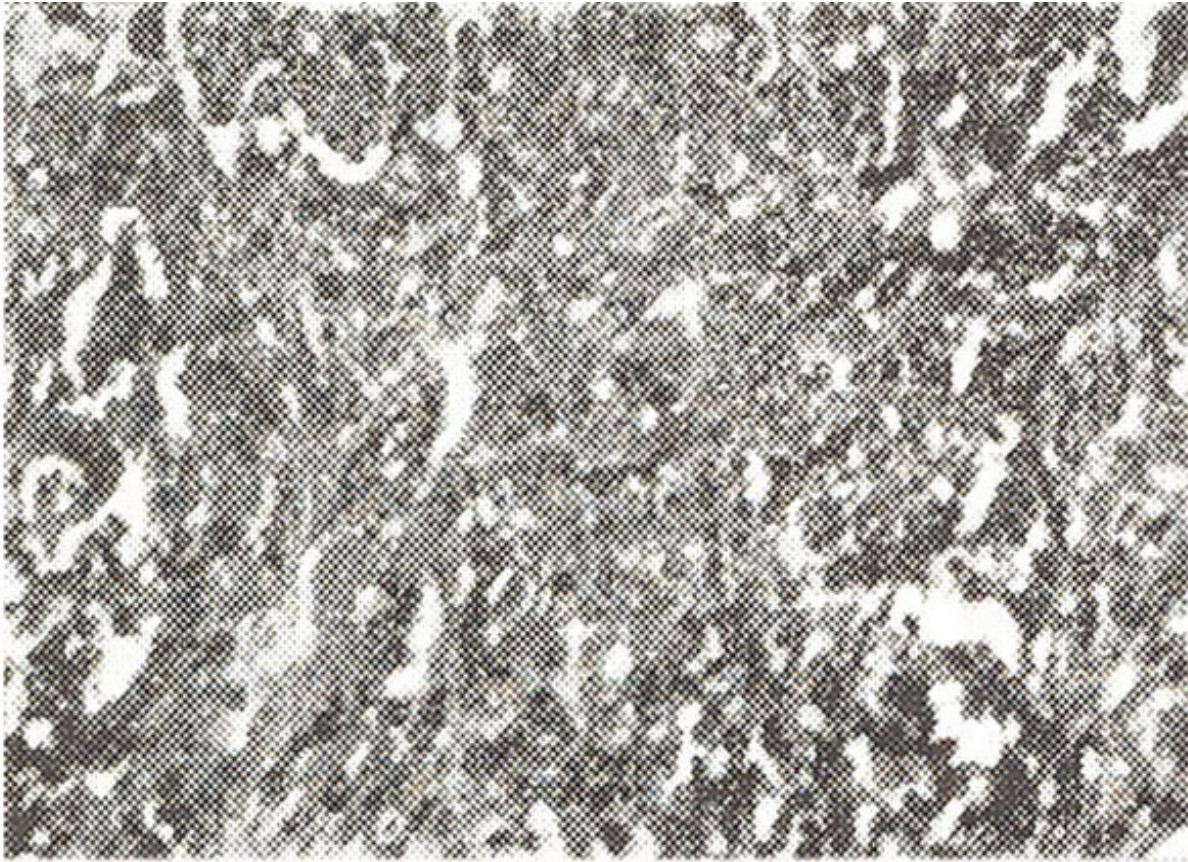


Fig. 6: Photomicrograph in a case of mycosis fungoides, as in figure 5, showing infiltration by mycosis cells and lymphocytes. Haematoxylin and eosin stains. x 500.

Patient having Burkitt's lymphoma showed infiltration by undifferentiated cells, interspersed with histiocytes.

Discussion

Lymphomas, which are malignancies of the lymphoreticular system (Nobrega, 1973), may arise from extranodal sites as primary lesions (Hellman, 1975). More frequent primary extra-nodal sites are skin, gastrointestinal tract and testes (Heliman, 1975; Nordqvist, 1976; Wolley, 1976). Mycosis fungoides is a variant of lymphoma arising from thymus-derived lymphocytes (T-cells) in the skin (Schein, 1976). In tumorous stage, this variant is characterized by extensive infiltration by 'Mycosis cells'. Parkhill (1968) and Al-Saleem (1970) reported 27 and 55 cases, respectively, of primary non-Hodgkin's lymphoma, partial or complete effacement of normal tissue architecture is a persistent feature. In all types of lymphomas (Lotz, 1976).

In the present study, bones were the most commonly involved site (21.7%). In a total of five patients showing lymphoma of the bone, two presented with unexplained anaemia, and were diagnosed after wedge biopsy of the iliac crest. One patient showed pathological fracture of a femur, and two showed bony swelling over the tibia and femur.

Pharynx was the second commonest site of primary lymphomatous infiltration (17.4%). One of these patients, a child of 2-1/2 years, was diagnosed after biopsy of a nasal polyp. She showed a positive direct Coomb's test, and was diagnosed to have an associated auto-immune haemolytic anaemia. Third commonest site was skin (8.7%). Testes and large intestine were less commonly affected. One patient, presenting with bleeding per vaginum, was diagnosed to have lymphoblastic lymphosarcoma of the uterus, after hysterectomy. Burkitt's lymphosarcoma was diagnosed in a patient to arise from palate.

References

1. Al-Saleem, T. and Harnick, R. (1970) Malignant lymphomas of the pharynx. *Cancer*, 26:1383.
2. Edelsen, R., Schein, P. Aftab Ahmad (1975) Cutaneous T cell lymphoma. The Sezary's syndrome, Mycosis fungoides and related disorders. *Ann. Intern. Med.*, 83 :534.
3. Freeman, C., Berg, J.W. Cutter, S.J. (1972) Occurrence and prognosis of extranodal lymphomas. *Cancer*, 29:252.
4. Goffinet, D.R. and Kaplan, H.S. (1973) Staging laparotomy in unselected, previously untreated patients with non-Hodgkin's lymphomas. *Cancer*, 32:672.
5. Hamlin, J.A., Kagan, A.R. and Friedman, N.B. (1972) Lymphomas of the testicle. *Cancer*, 29:1352.
7. Hellman, S., Rosenthal, D.S., Moloney, W.C. et al. (1975) The treatment of non-Hodgkin's lymphoma. *Cancer*, 36:804.
8. Jones, S.E., Fuks, Z., Bull, M., Kadin, M.E., Dorfman, R.F., Kaplan, H.S., Rosenberg, S.A. and Kim, H. (1972) Non-Hodgkin's lymphomas. IV. Clinico-pathologic correlation in 405 patients. *Cancer*, 31:806.
9. Kim, H. and Dorfman, R. (1974) Morphological studies of 84 untreated patients subjected to laparotomy for the staging of non-Hodgkin's lymphomas. *Cancer*, 33:657.
10. Kim, H. and Dorfman, R. (1977) Composite lymphomas. *Cancer* 40:959.
11. Lotz, M.J., Chabner, B., Devita, V.T. Jr., Johnson, R.E. and Berard, W. (1976) Pathological staging of 100 consecutive untreated patients with non-Hodgkin's lymphomas. Extranodal sites of disease. *Cancer*, 37:260.
12. Nime, F.A., Cooper, H.S. and Eggleston, J.C. (1976) Primary malignant lymphomas of the salivary glands. *Cancer*, 37 :906.
13. Nobrega, F.T., Kyle, R.A. and Harrison, E.G. Jr. (1973) Malignant lymphoma including Hodgkin's disease occurring in the vicinity of a large medical centre (Olmsted county) Minn., 1945. *Cancer*, 31:295.
14. Nordqvist, B.C. and Kinney, J.P. (1976) and TB cells and cell-mediated immunity in Mycosis fungoides. *Cancer*, 37 :714.
15. Parkhill, E.M.: Tumours of the oral cavity and pharynx. In atlas of tumour pathology, Section IV, Fasc. 10b, 252-258, 1968.
16. Rappaport, H.: Tumours of haemopoietic system, in atlas of tumour pathology, face 8. Washington, D.C. Armed Forces Institute of Pathology, 1966.
17. Reddy, S., Saxena, V.C., Pellottiere, E.V. and Hendrickson, F.R. (1977) Easily nodal and extra-nodal non-Hodgkin's lymphomas, *Cancer*, 40:98.
18. Schein, P.C., Edelsen, R. (1977) Cutaneous T cell lymphoma. *Cancer*, 38:1858.
19. Tenasbaum, B., Sanenford, R.S., Klinger, M.E. (1976) Testicular tumour. presenting sign of lymphoma. *Cancer*, 5:1223.
20. Van Slyck, E.J. (1972) Lymphocytic lymphosarcoma of gall bladder. *Cancer*, 3:810.
21. Wiseman, C., Liao, K.T. (1972) Primary lymphoma of the breast. *Cancer*, June 1705.
22. Wolley, P., Canellos, G.P. (1976) Extranodal presentation of non-Hodgkin's lymphomas in the

testis. *Cancer*, 38:1026.

23. Wollner, N. (1976) Non-Hodgkin's lymphoma in children. *Paediatric Clin. North Am.* 23:371.