

RADIONUCLIDE EVALUATION OF THE SUPERIOR VENA CAVA AND UPPER THORACIC VEINS IN MEDIASTINAL SYNDROME

Pages with reference to book, From 65 To 71

Durr-e-Sabih, Sher Mohanimad Khan, Zahida Sabih (Atomic Energy Medical Centre, Nishtar Medical College and Hospital, Multan.)

Abstract

Radionuclide studies of the superior vena cava are non-invasive and simple to perform. These studies give information about the patency of the superior vena cava, innominate and the subclavian veins. The site and extent of obstruction can be determined. Since this technique is non-invasive or minimally invasive, it can be repeated as often as required.

The anatomic and physiologic basis of this investigation and methodology of the procedure is given. Two cases are described in detail. The only other investigation giving comparable clinical information is contrast venography which is uncomfortable and carries a definite risk of allergic reaction (JPMA 36 : 65, 1986).

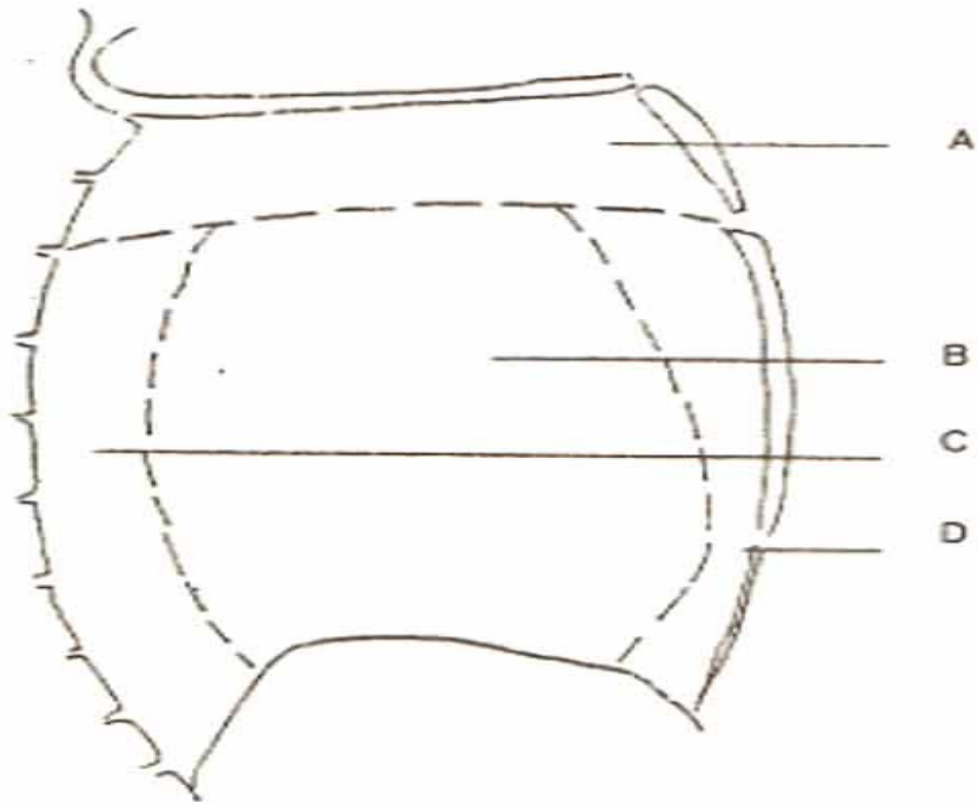
INTRODUCTION

The superior mediastinum has been called the great transportation centre of the body, because through it passes all the food on its way to the gastrointestinal tract, all air which enters or leaves the lungs, all lymph in the thoracic duct, all blood which leaves the heart and returns to it from the superior half of the body¹. Mediastinal pathology causes obstruction, to the blood flow in the superior vena cava.

The purpose of this study was to use radionuclides to assess the blood flow in the superior vena cava, the innominate and the subclavian veins in patients suspected of having mediastinal pathology.

Applied Anatomy of the mediastinum

The mediastinum, occupying the central portion of the chest is divided into four compartments,



KEY (A): SUPERIOR MEDIASTINUM

Trachea, Upper Desophagus, Thymus
 Thoracic Duct, Great Veins,
 Arch of Aorta and its branches
 Phrenic Nerve, Vagus, Left
 Recurrent Layngeal Nerve.

KEY (B): MIDDLE MEDIASTINUM

Heart, Ascending Aorta,
 Great Veins, Pulmonary Artery
 Phrenic Nerves.

KEY (C): POSTERIOR MEDIASTINIM

Desophagus, Thoracic Duct
 Descending Aorta, Symphathetic
 Chain, Intercostal Nerves
 Vagus.

KEY (D): ANTERIOR MEDIASTINUM

Fibroareolar Tissue
 Lymph nodes.

Fig. 1 Compartments of the mediastinum and their contents.

Figure 1 gives these compartments and their contents. Most mediastinal structures are protected against extrinsic pressure, the trachea by its rings, the oesophagus by its posterior position and mobility and the arteries by their muscular walls and high gradient of pressure, but the mediastinal veins with their thin walls and low intraluminal Pressure are susceptible to external pressure, their anterior position makes

them all the more vulnerable by permitting compression against the sternum. Lymph nodes along the right innominate vein, the arch of the azygos and the superior vena cava (the right anterior mediastinal and the right paratracheal chains) drain a major part of the thoracic cavity. The frequency of disease of this part of the body is a constant threat to these lymph nodes with partial or complete obstruction of the superior vena cava from extrinsic pressure or invasion².

The superior vena cava has four tributaries that carry the main burden of shunting blood if it is obstructed. These are: the internal mammary, the azygos, the vertebral and the lateral thoracic routes. All four routes are interconnected and are shown in figure 2.

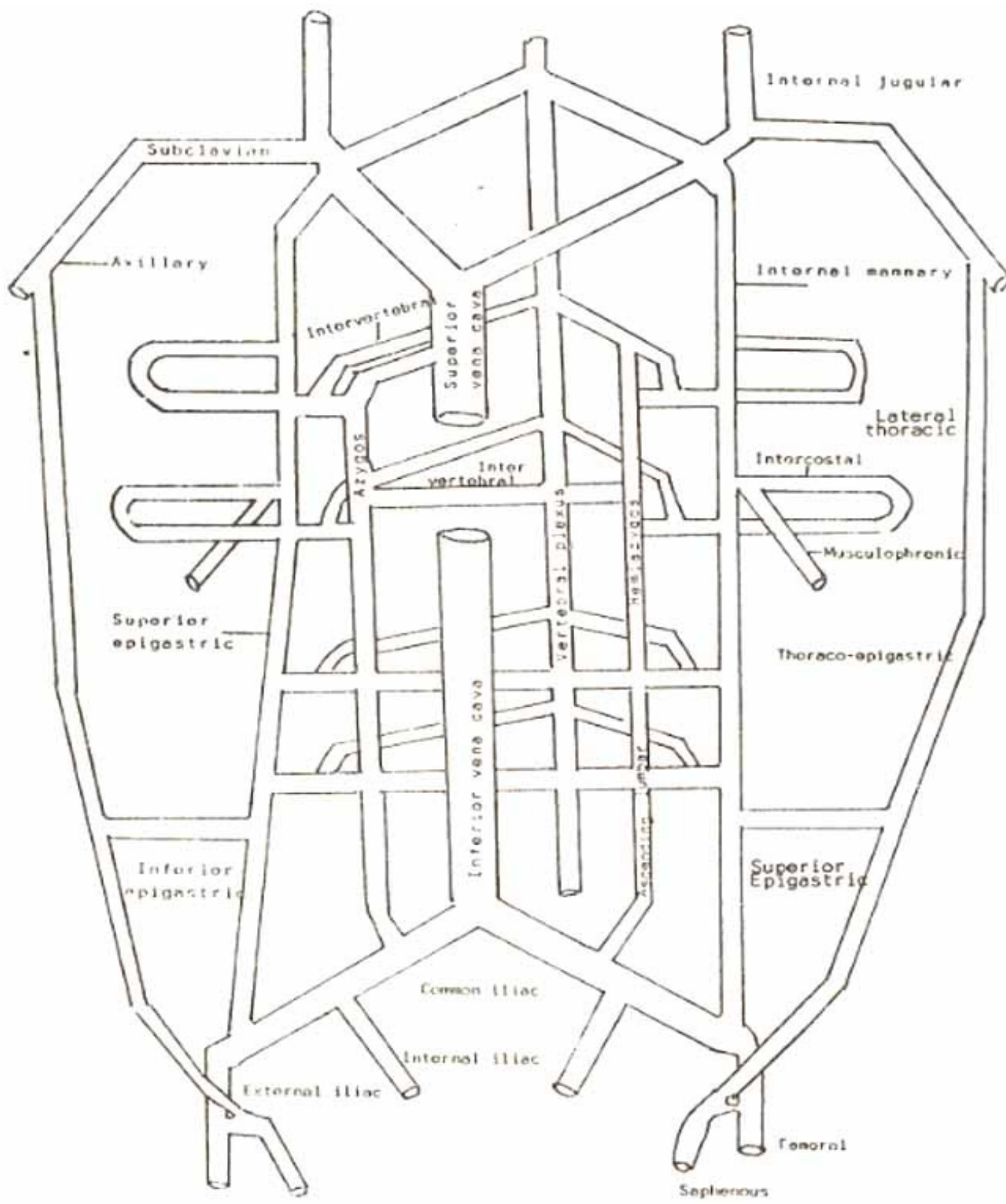
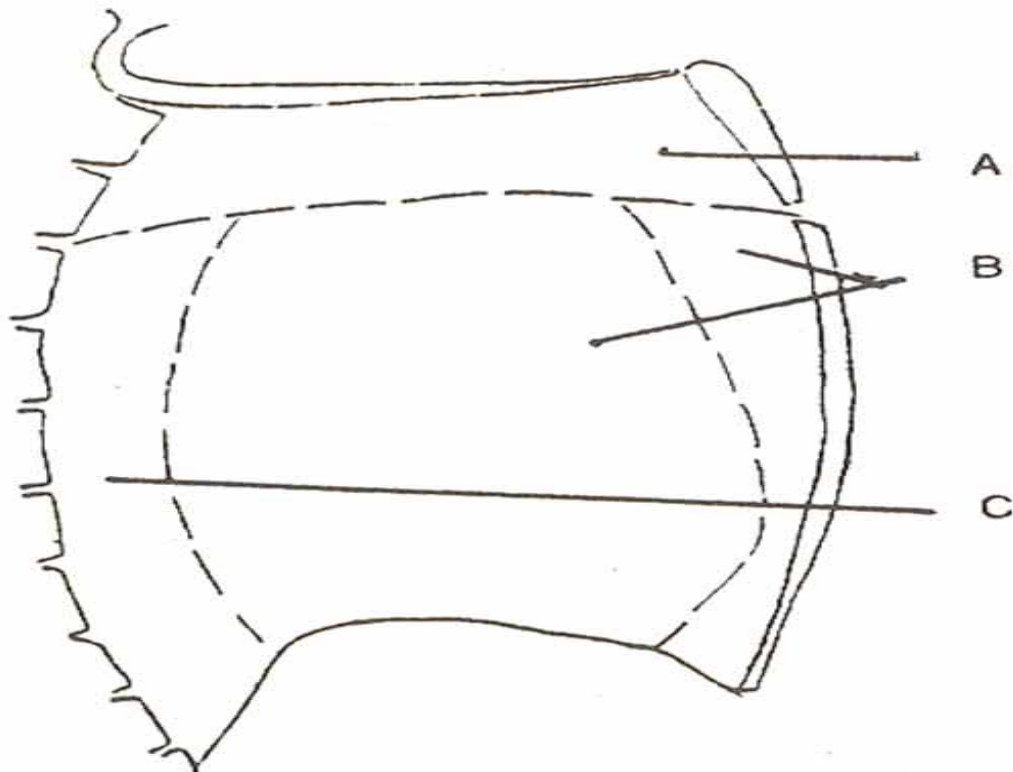


Figure 2

Pathology and clinical features of the superior vena caval syndrome
 The commonest mediastinal masses in adults are metastatic carcinomas (Most commonly bronchogenic carcinomas) and Lymphomas³.



KEY: (A) SUPERIOR MEDIASTINIUM
 Lymphoma. Thymoma
 Retrosternal Goitre
 Metastatic Carcinoma
 Parathyroid Tumours
 Zenker's Diverticulum
 Aortic Aneurysm

KEY: (B) ANTERIOR & MIDDLE MEDIASTINIUM
 Lymphoma
 Metastatic Carcinoma
 Teratodermoid
 Bronchogenic Cyst
 Aortic Aneurysm
 Pericardial Cyst.

KEY: (C) POSTERIOR MEDIASTINIUM
 Neurogenic Tumours
 Lymphoma
 Bochdalek's Hernia
 Aortic Aneurysm

Fig. 3 Mediastinal masses and their sites.

Figure 3 shows mediastinal masses and their sites.

A mass growing in the confined space of the mediastinum exerts pressure on existing structures, the veins being the most-susceptible to external pressure are readily compressed, when obstruction becomes sufficient to occlude venous flow the patient develops 'superior vena caval syndrome'. This

syndrome is characterized by plethora and oedema of the face and neck, conjunctival oedema, headache, dilatation of veins on the upper thorax and neck. Visual disturbances and alteration in the state of consciousness, dysphagia, wheeze and shortness of breath may also occur.

Investigation of the mediastinum and comparison of the various diagnostic procedures

Diagnostic procedures for the diseases of the mediastinum include chest radiography, computerized tomography, fluoroscopy, ultrasonography, contrast angiography, scintigraphy with ^{31}P and ^{67}Ga , oesophagoscopy, bronchoscopy, mediastinoscopy, thoracotomy and radionuclide angiography (mediastinal flow study). These are aimed at localizing the lesion, determining the site of origin and obtaining a tissue diagnosis⁴.

In superior vena caval syndrome invasive diagnostic procedures like bronchoscopy, oesophagoscopy and mediastinoscopy are contraindicated due to the risk of bleeding³. Contrast venography is also contra-indicated in cases of complete superior vena caval obstruction due to the risk of rupture of veins when injecting large quantities of contrast material, Iodine allergy and patient discomfort also limit the use of contrast venography for repeated studies⁵.

Superior vena caval obstruction due to neoplastic disease constitutes an oncological emergency⁶ and knowledge of the actual status of venous pathways is helpful in planning a course of treatment which avoids radiation injury to the patients collateral channels⁵. Radionuclide angiography gives the required information safely and with minimal patient discomfort. It also has a place in the investigation of innominate vein obstruction and incomplete obstruction of the superior vena cava, because patients with metastases are considered inoperable^{7,8}.

This centre has been performing radionuclide angiography of the mediastinal veins routinely.

The purpose of this paper is to discuss our experience of this study as a non-invasive or minimally invasive procedure giving unique clinical information about the disease.

MATERIAL AND METHOD

The period of study was from Sept. 1983 to May, 1985. There were 34 patients, 28 men and 6 women. Their ages ranged from 17 to 80 years, the mean age was 46 years.

All studies were performed on a large field Gamma Camera fitted with a low energy high resolution parallel hole collimator. Patients were imaged in the supine position. 3-5 mCi of mTc as eluate or 1 .52-2 mCi $^{99\text{m}}\text{Tc}$ tagged to Marco Aggregated Albumin (MAA) contained in less than 1 ml volume was injected simultaneously in both arms in 27 cases and in only one arm in 7 cases. In all cases, the injections were made in an antecubital vein. Imaging was started immediately and sequential pictures were obtained at 2.3 seconds intervals on an X-ray film using a multiformat imager. The passage of the (bolus of) activity was also visualized on a persistence scope at the time of the study. The images obtained were analyzed for continuity and contour of the activity column and abnormal circulation channels under the heading given in (Table 1). Normal variants reported in the literature⁹ were also noted.

RESULTS AND DISCUSSIONS

The findings are given in table 1.

Table - I
Location and Type of the Lesion (n=34).

Superior vena cava lesion	- 14
Innominate vein lesion	- 9
Combined lesion, in both superior vena cava and the innominate vein	- 4
Obstruction/skip lesion	- 10
Impression on activity column	- 4
Listing/kinking	- 7
Collaterals	- 9
Normal	- 15

Table - II
Etiological distribution of the Lesions.

Carcinoma lung	- 16
Superior vena cava syndrome (unknown etiology)	- 4
Retrosternal goitre	- 3
Mediastinal widening on X-ray chest	- 3
Generalized lymphadenopathy/lymphoma	- 3
Congenital heart disease	- 2
Pericardial effusion	- 1
Miscellaneous	- 5

Most of the cases were referred to us for the assessment of carcinoma lung (Table II). While conducting mediastinal flow one case of pericardial effusion was also seen. Among the variants described by Miyamae⁹, we have seen small activity hold ups in the subclavian vein due to venous valves, attenuation of the superior vena cava due to the 'pericardial pinch'⁷ and decreased activity in the left innominate vein. We have also noticed in six of our patients an unusual vein draining into the superior aspect of the main venous channel (Figure 4).

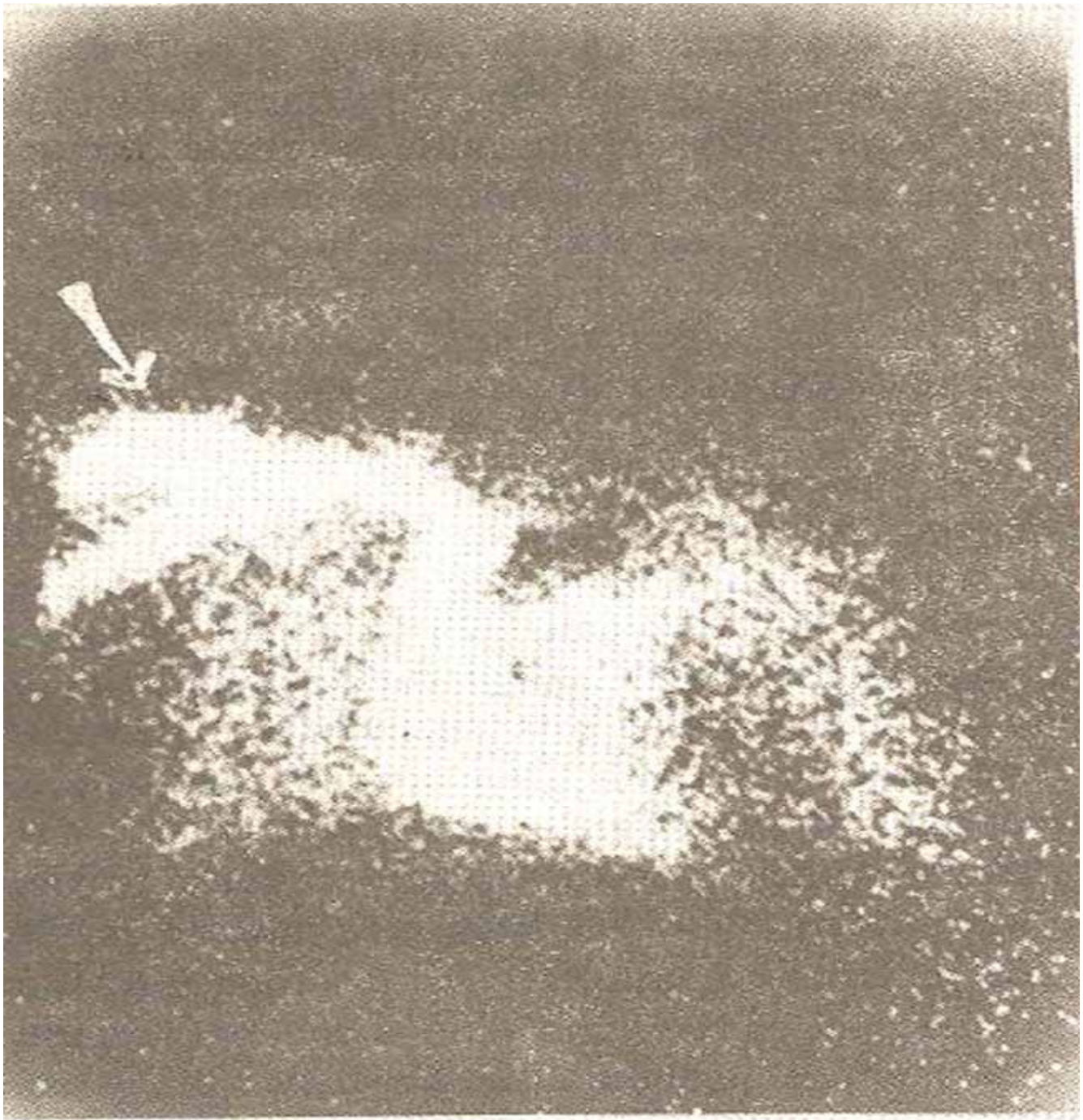


Fig. 4. Flow study with activity seen in the Subclavian vein, innominate vein, Superior vena cava, right heart and lungs, unusual vein draining into the main venous channel also seen, arrow.

The vein is probably the cephalic vein itself (Figure 5).

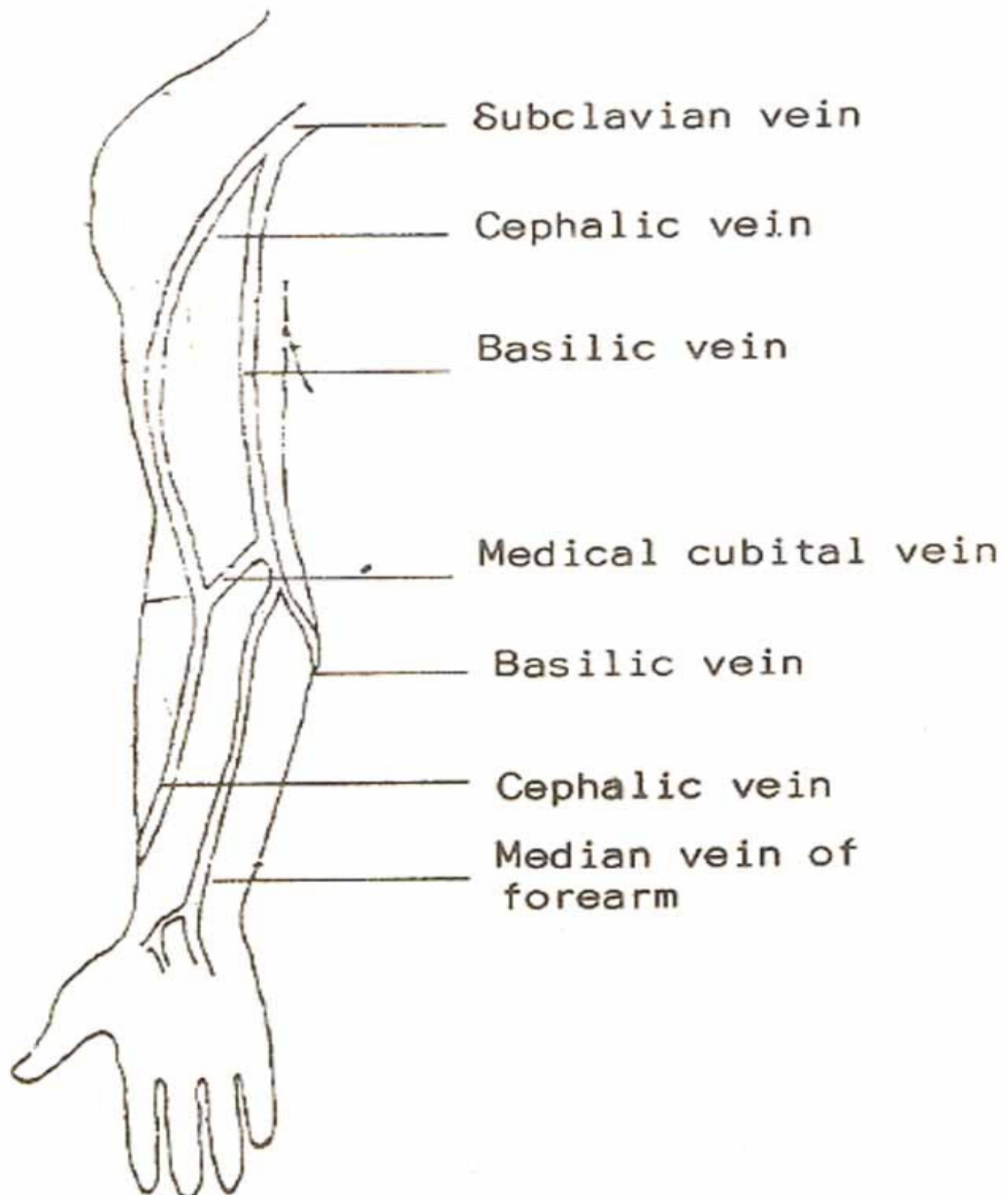


Fig. 5 The superficial veins of the upper limb.

The possibility of its being the branch of the cephalic vein which ascends in front of the clavicle, described as an occasional finding¹⁰ occurred to us initially, but as this was seen on the right side in 5 out of the 6 patients it seems unlikely and this phenomenon is probably due to preferential venous flow in the cephalic vein due to the position of the arm maintained during injection and the selection of the

vein in the antecubital region.

Two cases are described in detail:

Case 1

A 45 years old female gave history of shortness of breath for 6 months. On examination, she had a multinodular goitre which was extending behind the manubrium. She also had dilated veins over her neck and upper back and coarse tremors of her outstretched hands. On investigations, her I¹³¹ thyroid uptake values were 11% at one hour, 17% at three hours and 29% at 24 hours. Her thyroid scan showed low activity over the gland with slight extension behind the suprasternal notch. Activity over the mediastinum was unremarkable. Her flow study showed total obstruction of normal venous channels with extensive coilaterals. A very vascular annular mass was seen at the level of the base of the heart which seemed to be getting the coilaterals (Figure 6).

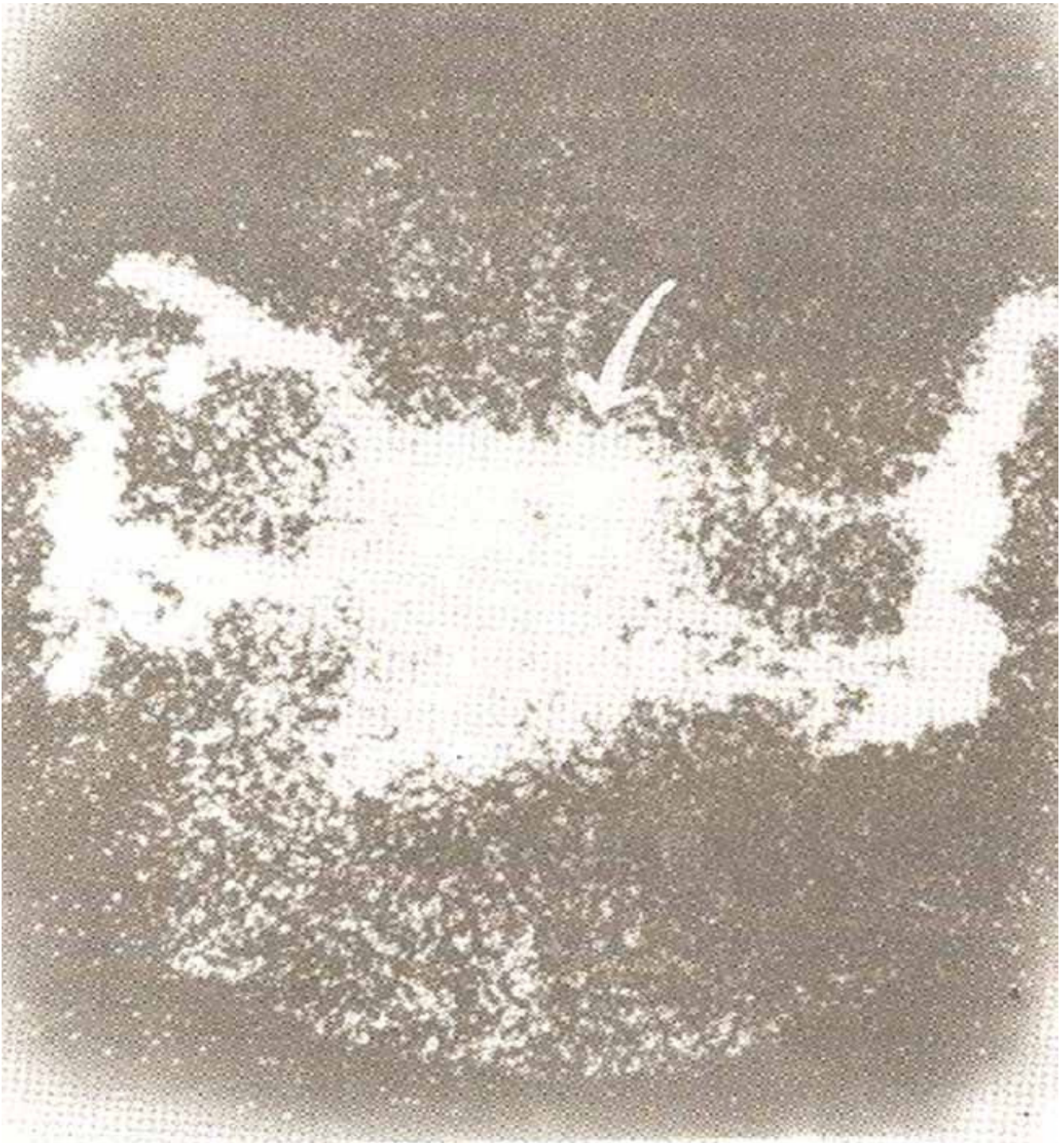


Fig. 6. Flow study in case 1, showing complete obliteration of the superior vena cava and multiple collaterals annular mass seen at the base of the heart, marked.

The continuity of the mass with thyroid tissue could not be definitely proved on nuclear studies. However, an ultrasound examination showed the mass to be continuous with the thyroid with a similar echo pattern (Figure 7).

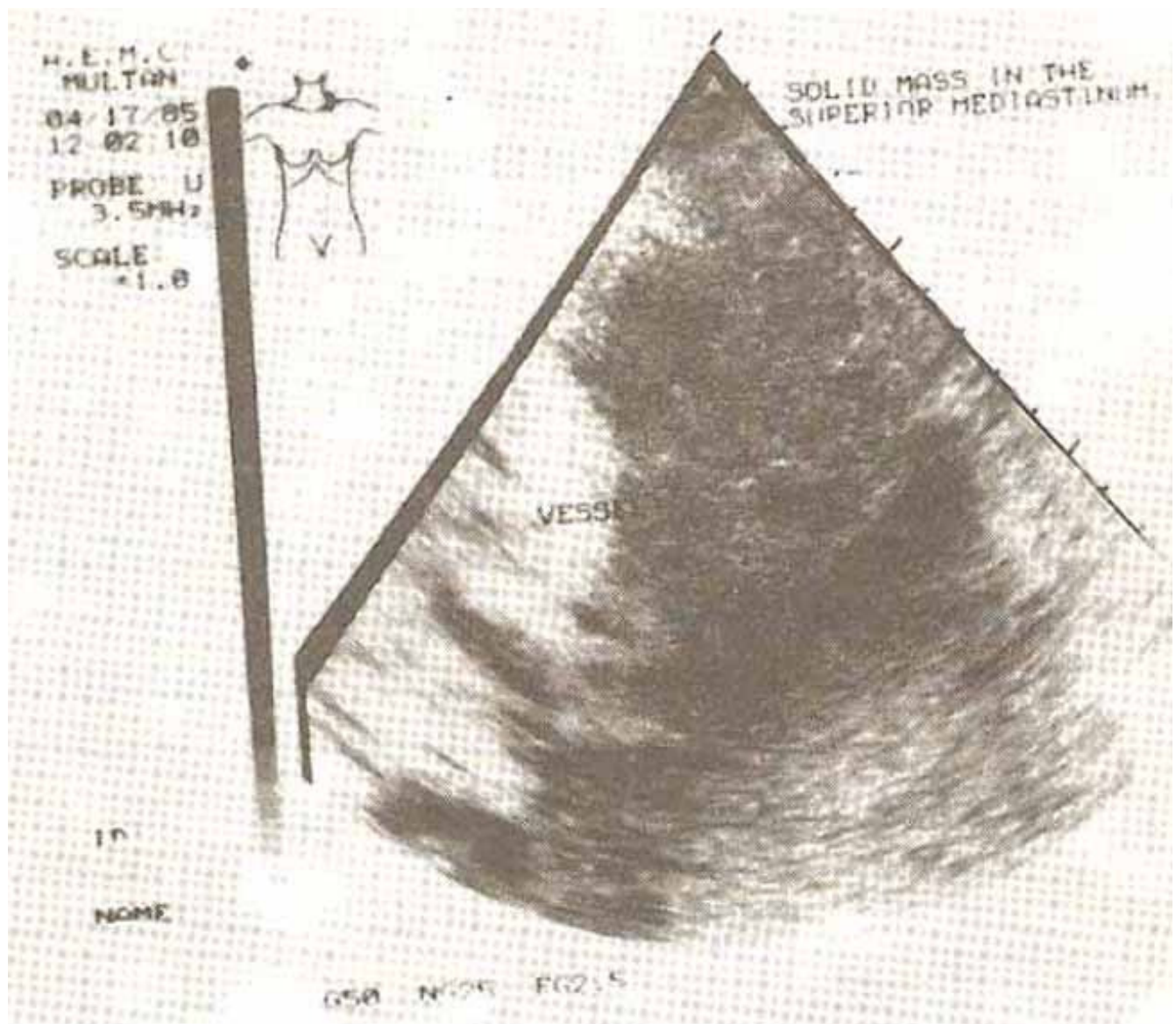


Fig. 7. Ultrasound study showing solid mass extending into the mediastinum, continuous with the thyroid echos and with a similar echo pattern, thyroid echos at the top of the picture.

At operation a large retrosternal goitre was removed and the patient had an uneventful recovery.

Case 2

A 60 years old male presented with a one month's history of swelling of the face and neck and shortness of breath. On examination, there were engorged veins on the neck but none on the chest or back. He had axillary lymphadenopathy. His blood picture was normal except for a raised ESR. On X-ray chest, a parahilar shadow was seen. Axillary lymph node biopsy was negative but sputum cytology was positive for malignant cells. A diagnosis of Carcinoma of the lung was made on the basis of the sputum cytology report, an attempt at cell type identification by an endoscopically taken biopsy was not made. The mediastinal flow study showed a totally obliterated superior vena cava with extensive collaterals. The patient was started on radiotherapy and a total of 3000 rads were given.

Subsequent flow studies showed a gradual reversion of blood flow through normal channels. At the end

of radiotherapy a course of chemotherapy was started by the end of which flow studies showed a normal superior vena cava and subclavian vein (Figure 8).

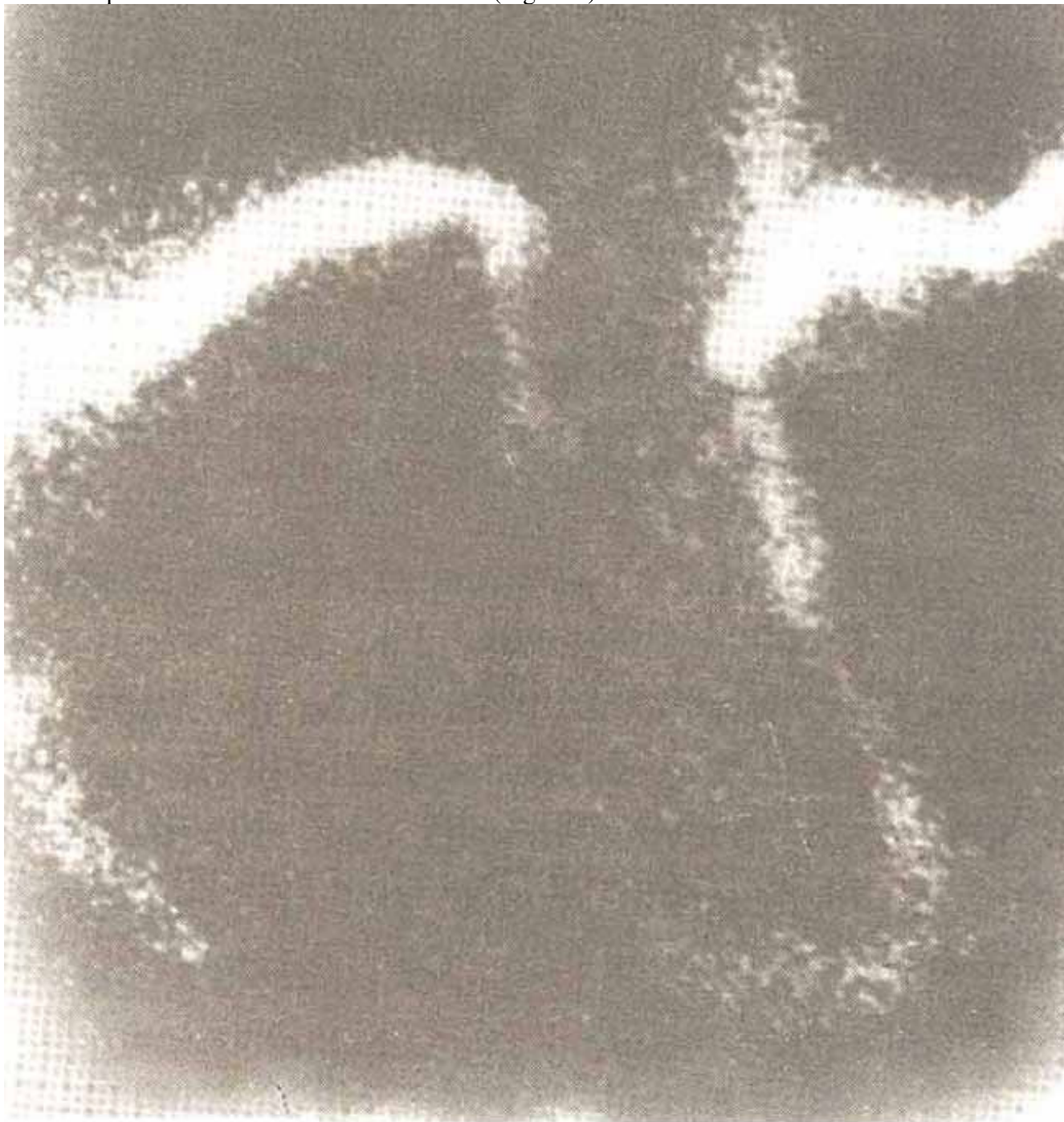


Fig. 8 (a)

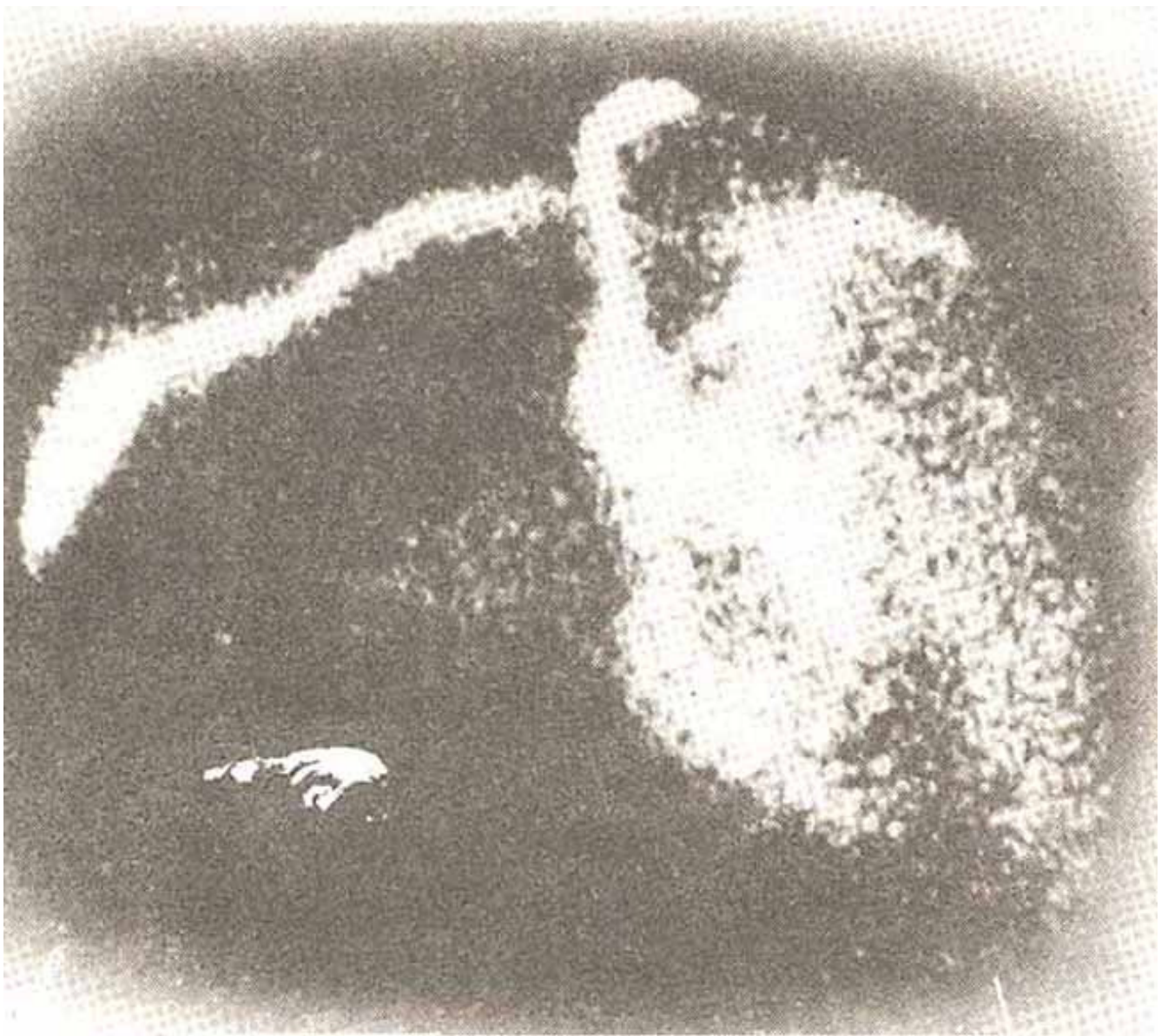


Fig. 8 (b)

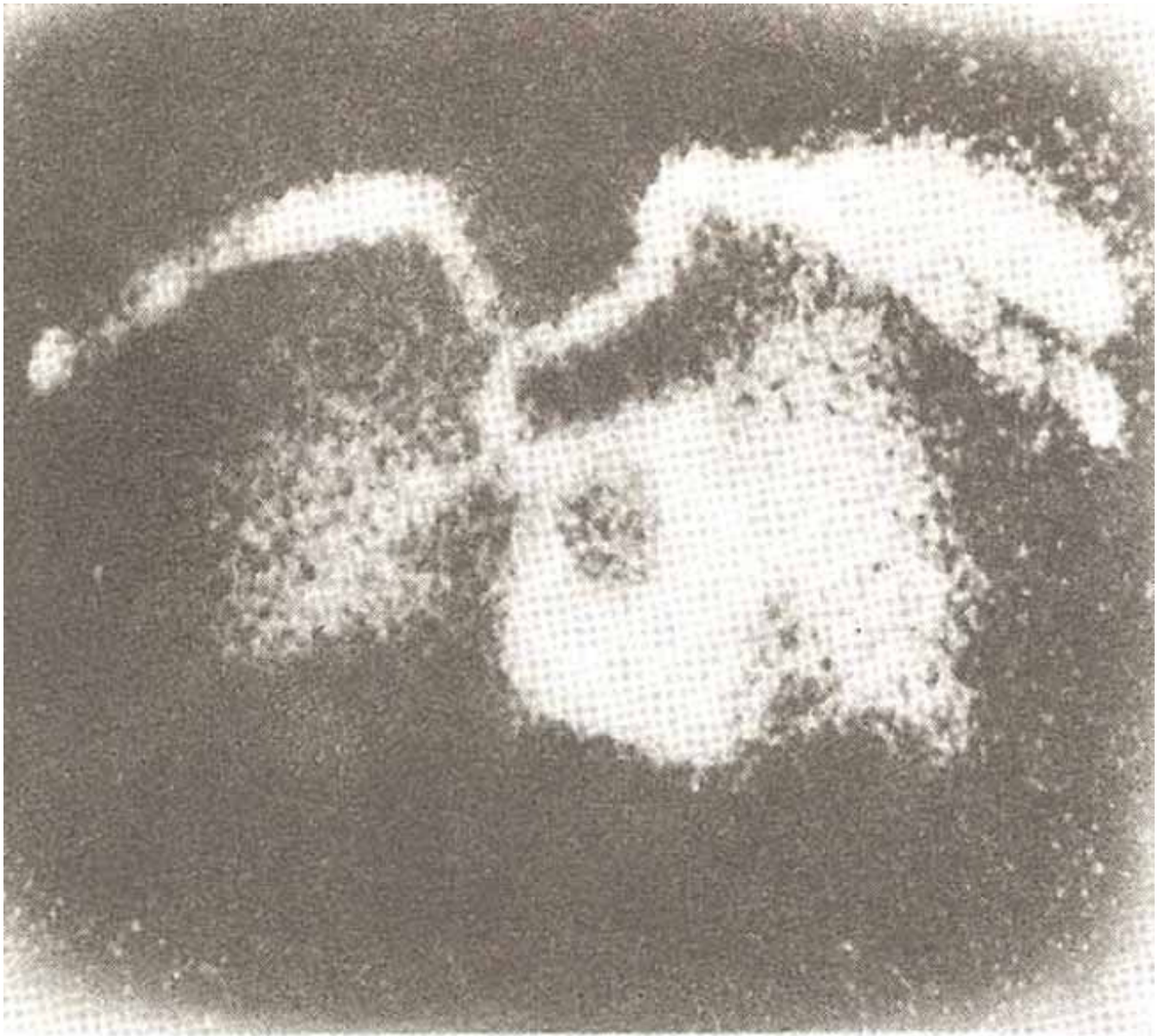


Fig. 8.(c) Representative images from serial flow studies done on case 2, showing gradual clearing of obstruction as therapy continued.

In the first patient the site, size and the degree of vascularity of the obstructing mass were defined but these were non-specific findings. However, when the information gained by nuclear studies was pooled with ultrasound findings a fairly confident diagnosis could be made which proved to be true on surgery. The second case demonstrates the strength of nuclear medical diagnosis. The non-invasiveness allowed repeated examinations to be made and made it possible to follow objectively the patient's response to therapy. In this case the degree of venous obstruction could not be accurately assessed by relying on the patient's clinical condition alone.

We experienced no difficulty with either finding adequate veins in the arm or any untoward effect of the injected radiopharmaceutical. This compares favourably with contrast venography which is the only other investigation which gives similar results but has many inherent drawbacks (vide supra).

In our opinion the easy availability of nuclear medical facilities in or near most large medical centres makes mediastinal flow a very attractive investigative procedure. We believe it should form a part of the diagnostic work up of all patients suspected of having lung malignancy or mediastinal obstruction.

ACKNOWLEDGEMENT

The authors acknowledge the help of Dr. Abdur Rauf Khan, MD, FACP., of the Department of Nuclear Medicine, Buffalo University, U.S.A. in the preparation of this paper.

REFERENCES

1. Hinshaw, H.C. and Rutledge, D.I. Lesions in the superior mediastinum which interfere with venous circulation. *J. Lab. Clin. Med.*, 1942; 27 : 908.
2. McIntire, F.T. and Sykes, E.M. Jr. Obstruction of the superior vena cava; A review of the literature and report of two personal cases. *Ann. Intern. Med.*, 1949; 30: 925.
3. Petersdorf, R.G., Adams, R.D., Braunwald, E., Isellbacher, K.J., Martin, J.B. and Wilson, J.D. ed. *Harrison's principles of internal medicine*. 10th ed. New York, McGraw Hill, 1983, p. 1584.
4. Stein, H.H. ed. *Internal Medicine*. Boston, Little, Brown 1983;p.384. Krishnamurty, G.T., Bland, W.H. and Winston, M.A. Superior vena caval syndrome; Scintiphotographic evaluation of response to radiation therapy. *AJR.*, 1973; 117:609.
6. Son, Y.H., Wetzel. R.A. and Wilson, W.J. 99mTC pertechnetate scintiphotography as diagnostic and follow-up aids in major vascular obstruction due to malignant neoplasm. *Radiology*, 1968; 91:349.
7. Shtasel, P. ed. *Speak Tome in nuclear medicine*, Hagerstown, Harper and Row, 1976; p.7.
8. Ackerman, L.V. and DeiRegato, J.A. and Spjut, H.J. ed. *Cancer diagnosis; treatment and prognosis*. 5th ed. St. Louis, 1977; p. 392.
9. Miyamae, T. Interpretation of mTC superior vena cavograms and results of studies in 92 patients. *Radiology*, 1973; 108:339.
10. Williams, P.L. and Warwick, R. *Gray's anatomy*. 36th ed. Edinburgh, Churchill Livingstone, 1980; p.753.