

# CONGENITAL ANOMALY OF THE LIVER AND GALL BLADDER

Pages with reference to book, From 202 To 204

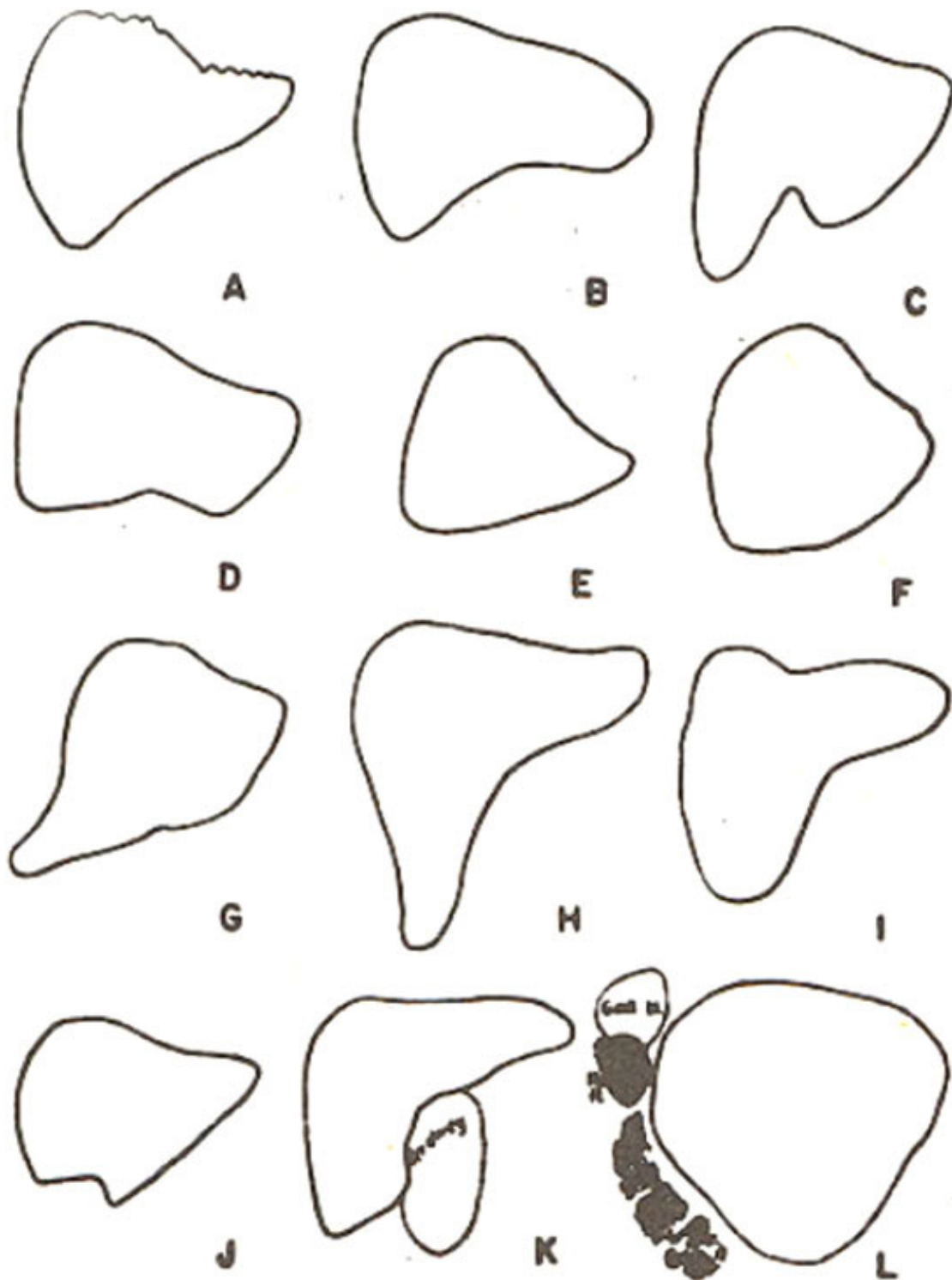
Shahnaz Taqi ( Department of Paediatrics, Liaquat National Hospital, Karachi. )

## **Abstract**

Congenital anomaly of the liver and gall bladder in a 9 years old male child is presented. (JPMA 37: 202,1987).

## **INTRODUCTION**

Liver is a malleable organ and its normal configuration is influenced by neighbouring structures. Variations in its configuration have been well illustrated by McAfee and Aulsebrook<sup>1</sup> (Figure 1).



**Figure 1. Various configurations of Liver.**

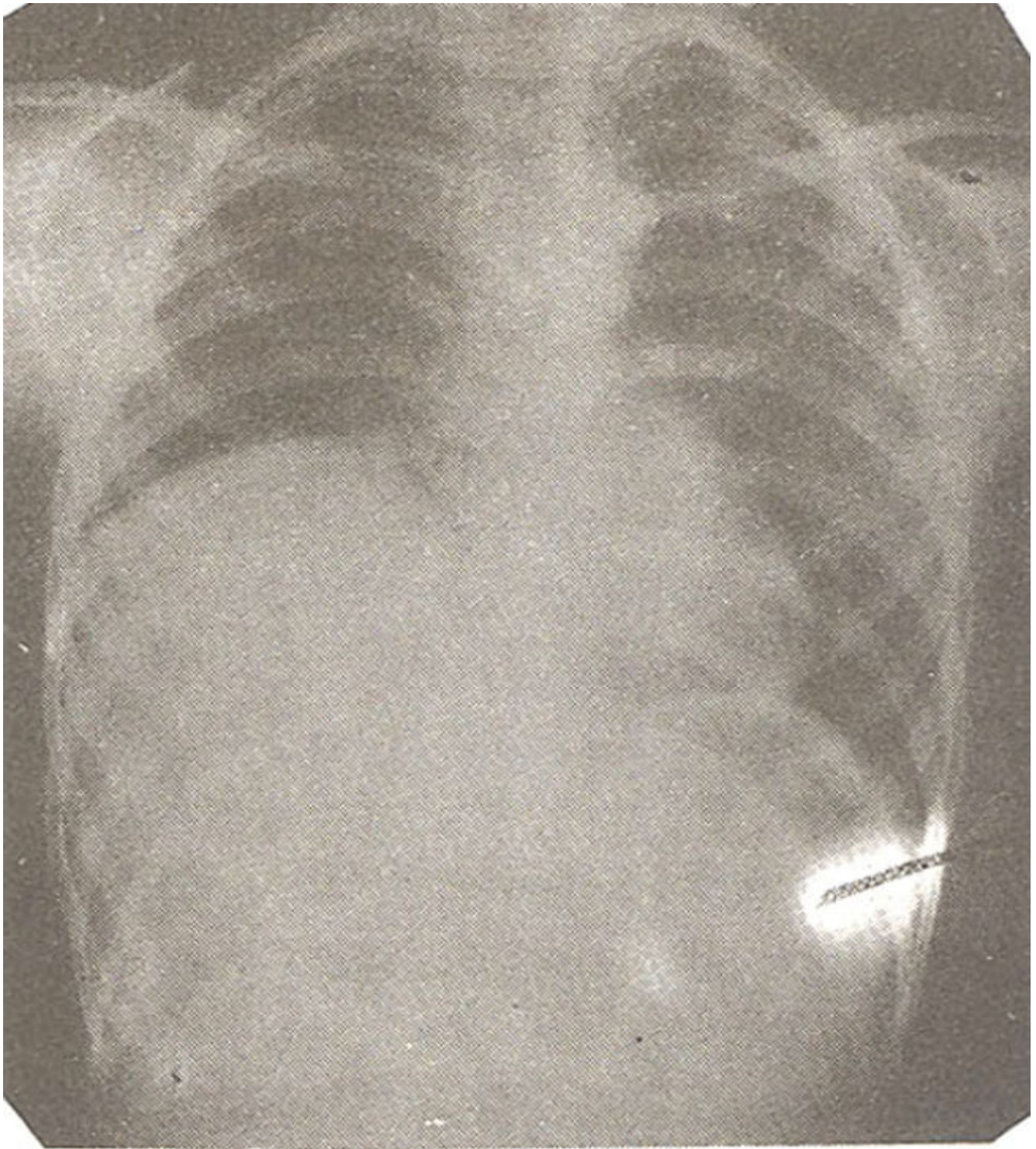
Organ and Hayes<sup>2</sup> have described supra diaphragmatic position of the right lobe of the liver and gall bladder. Atrophy of one or both lobes of the liver can occur as a result of vascular disease in intra-uterine life<sup>3</sup>. Sherlock<sup>4</sup> has mentioned the occurrence of multiobulated liver and symptomatic accessory lobes have also been described.<sup>5</sup>

## **CASE REPORT**

S, a 9 years old male child was admitted to the National Institute of Child Health (NICH), Karachi, with history of vague abdominal pain and anorexia since a month. These complaints were preceded by an attack of jaundice which was sudden in onset but lasted for two weeks. There was no history of fever, nausea or vomiting prior to the appearance of jaundice. He did, however, pass high coloured urine and clay coloured stools during the illness. There was no history of contact blood transfusion, vaccination or drug intake in the recent past. Previously he had suffered from two similar attacks of jaundice at the ages of one and four years.

On physical examination, the patient had a lean build and weighed 21.5 Kg. He was not jaundiced at that time but did show signs of anaemia. His liver was just palpable below the right subcostal margin. Examination of the chest revealed increased dullness and diminished breath sounds in the lower and mid zones of the right lung.

Complete blood picture, urinalysis and liver function tests were unremarkable. Chest X-ray revealed raised right dome of the diaphragm (Figure 2)



**Figure 2. X'ray chest showing raised right dome of the diaphragm.**

but on flouroscopy both domes of the diaphragm were moving freely. The Casoni's test was negative. Liver scan showed an enlarged liver with no cold areas. The two lobes of the liver were separated, the right lobe being much larger than the left, and pushing the right dome of the diaphragm upwards (Figure 3).

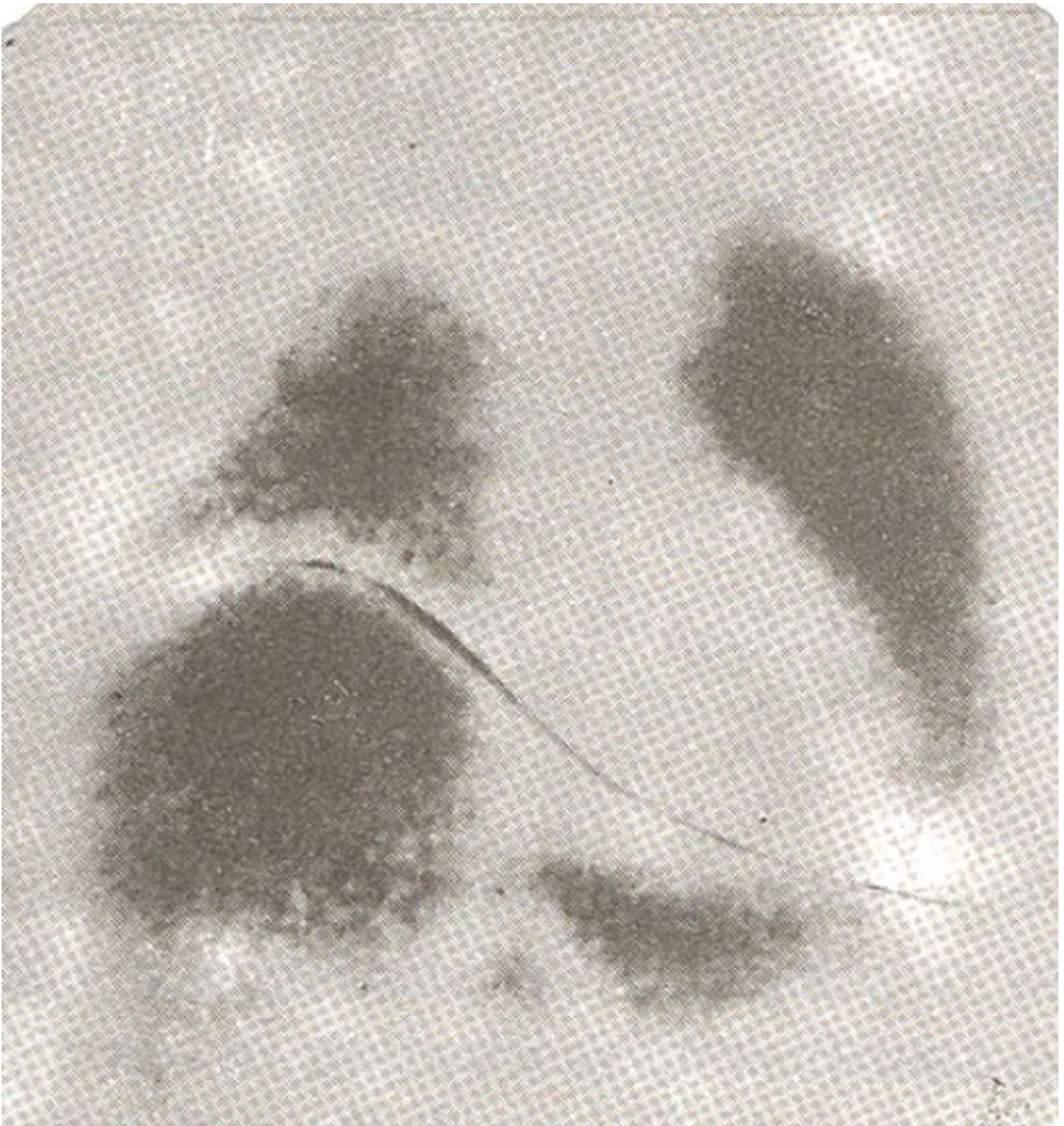
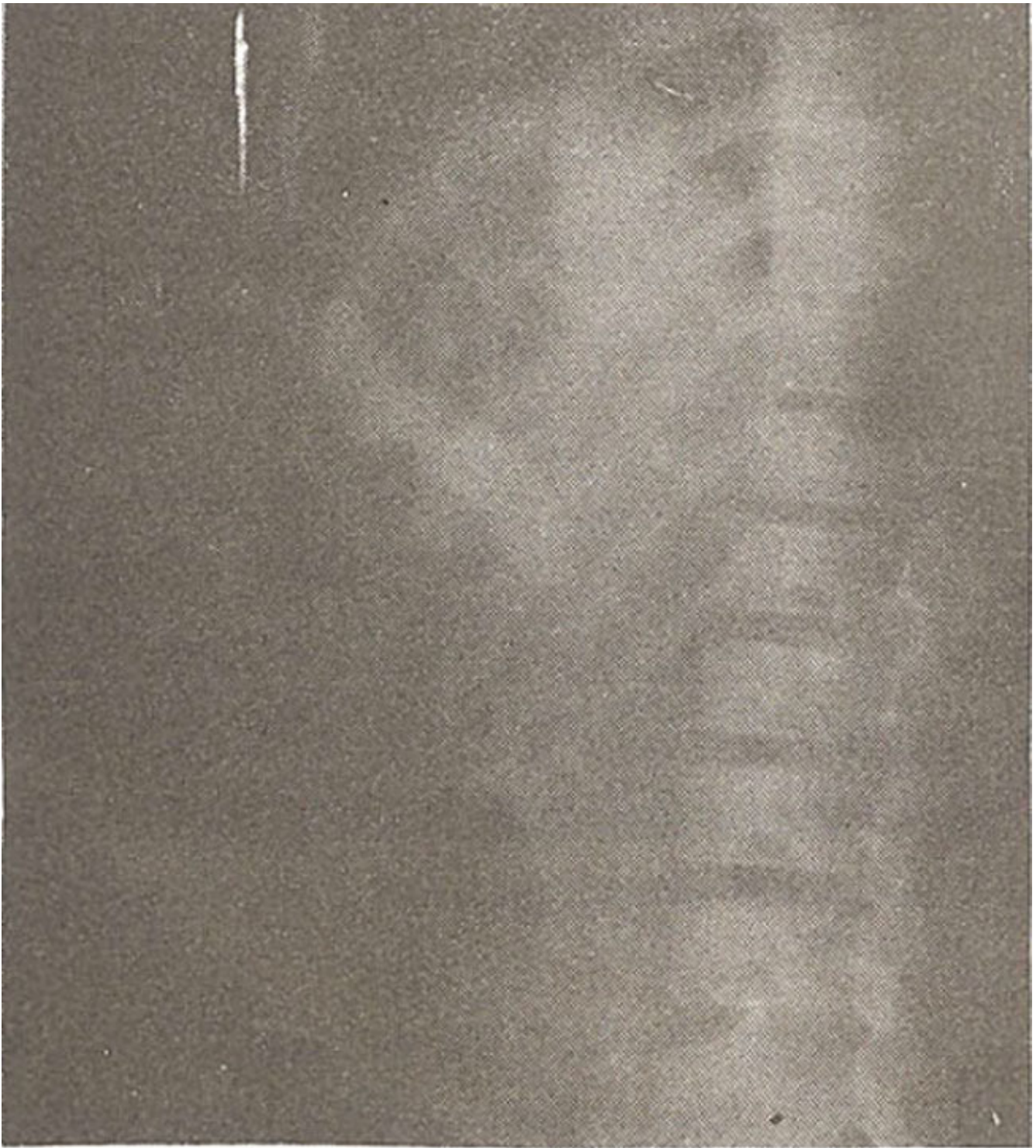


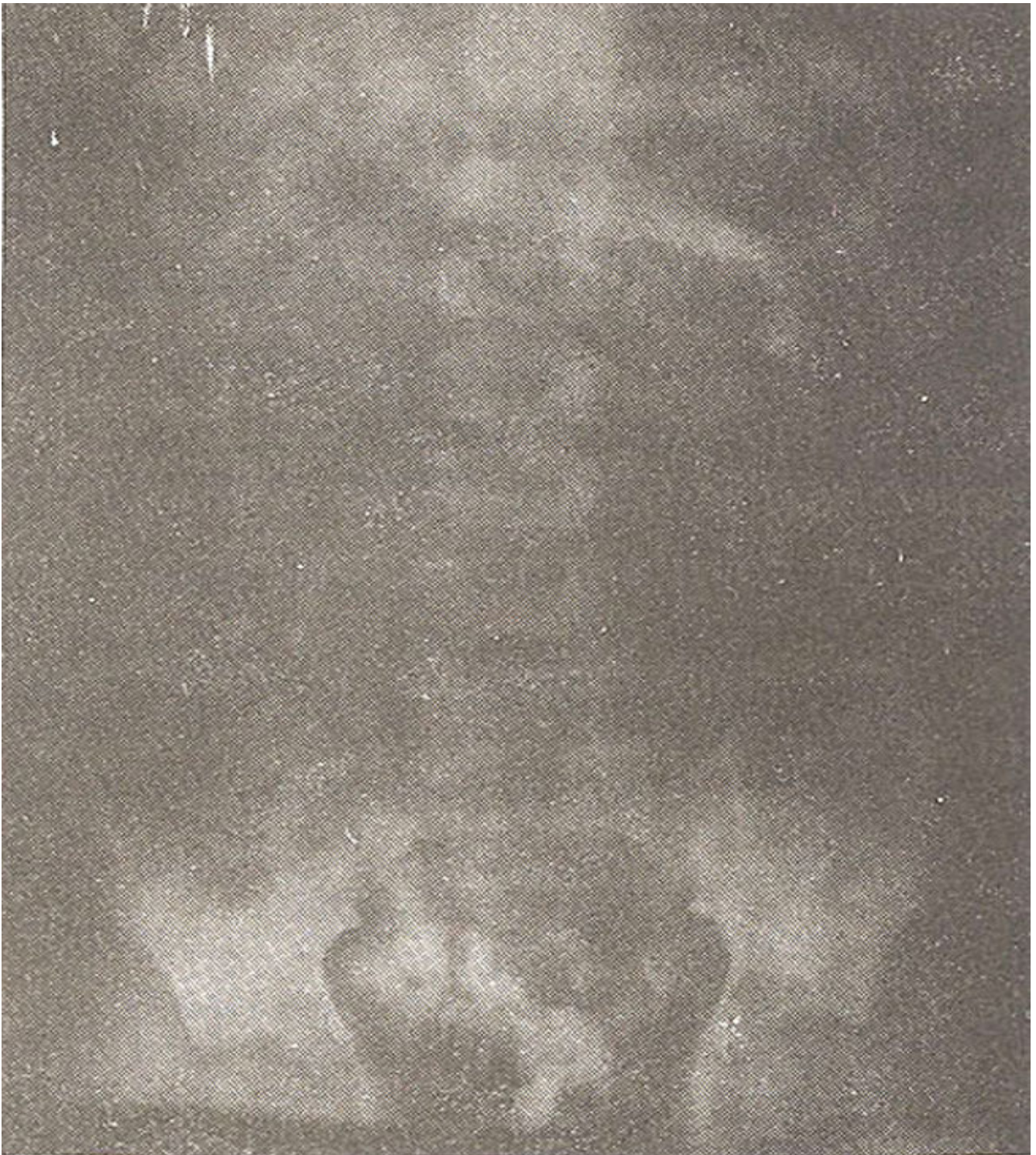Figure 3. Liver scan showing enlarged liver. Two lobes were separated. Right lobe was larger than left.

Intravenous cholangiogram showed an inverted gall bladder situated at a higher position than normal (Figure 4).



**Figure 4. Intravenous cholangiogram showing abnormal position of gall bladder.**

Barium enema examination revealed malpositioning of the transverse colon with its right half extending up and encroaching on the raised right dome of the diaphragm (Figure 5).



**Figure 5. Barium Enema showing malpositioning of transverse colon.**

A pneumo peritoneum was created to observe the anatomical relationship of the liver to the diaphragm. As the investigations were not conclusive an exploratory laparotomy was performed. The liver was lacking its normal wedge shape and its right and left lobes were strikingly separated. The larger right lobe was extending upwards and pushing up the right dome of the diaphragm. The transverse colon was

found to be interposed between the two lobes, extending upto the diaphragm. The gall bladder was malpositioned and was lying along the anterior surface of the right lobe of the liver in close proximity to the colon (Figure 6).

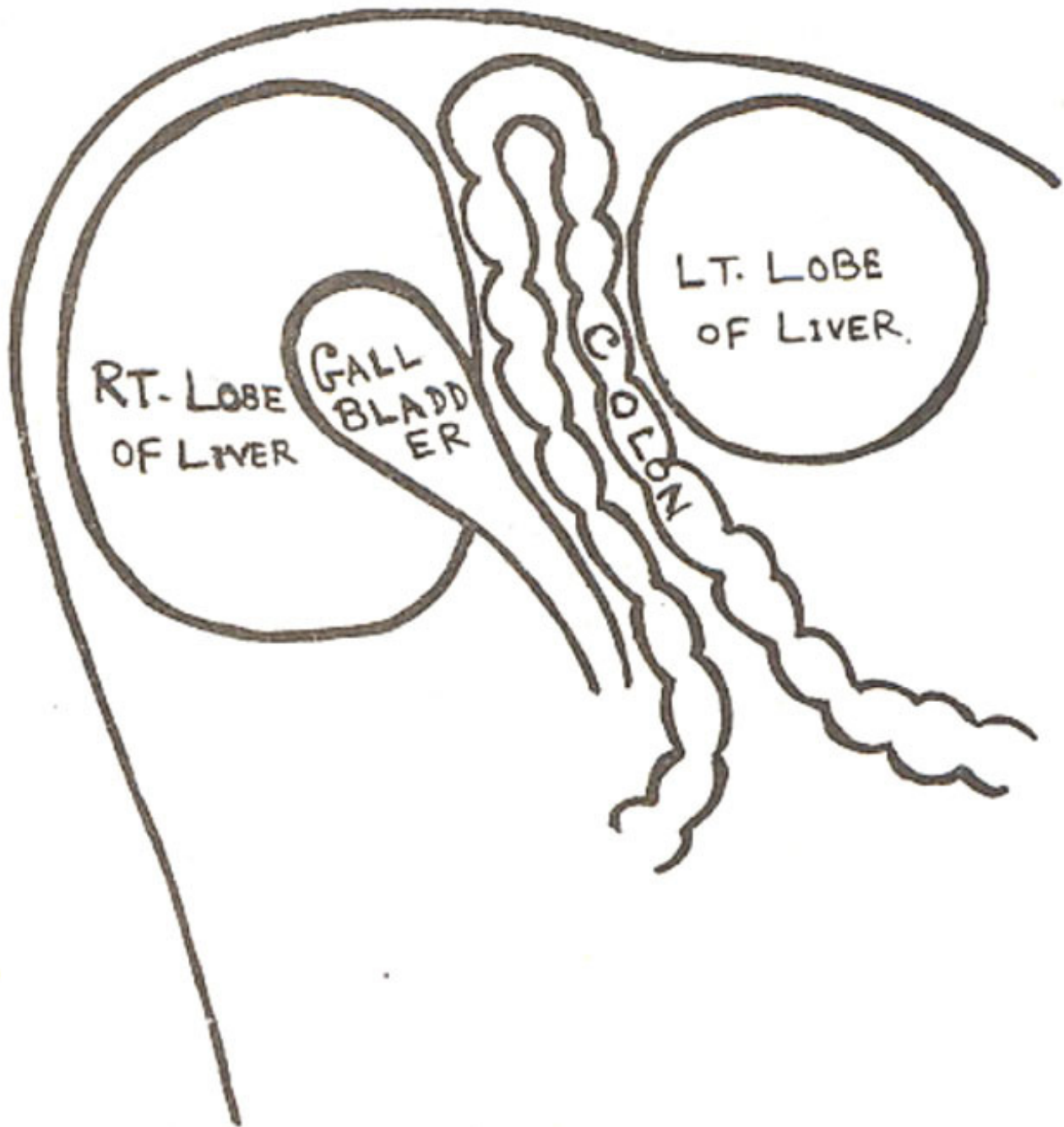


Figure 6. Showing findings on laparotomy.

The porta hepatis was abnormal but there was no evidence of a diaphragmatic hernia.

After identifying the various organs, the omentum was stitched to the diaphragm in order to reduce the space between the two lobes and the abdomen was closed.

The patient has remained under regular follow up since surgery and is progressing well with no further episodes of jaundice.



## **DISCUSSION**

It would appear from the operative findings that the interposition of the transverse colon between the two lobes of the liver, in close proximity to the gall bladder and the porta hepatis was probably responsible for the intermittent attacks of jaundice as a result of obstruction of the bile flow due to rising pressure in the transverse colon from time to time.

A similar anomaly of the liver was described by Ayer and Thangavelu<sup>6</sup> at postmortem examination, where the liver, was completely divided into separate lobes. The left lobe however was much larger than the right and the quadrate and caudate lobes were quite separate too. Such anomalies could be explained due to developmental defects as, during embryonic life, the liver is more lobulated and becomes less so in later stages of foetal development. Persistence of foetal pressures in adult human liver could be the reason for exaggerated lobulation. The right lateral fissure together with the porta hepatis and the fissure for the ligamentum venosum forms a continuous cleavage line and hence divides the liver into two separate segments. The separate lobes of the liver kept in position by the structures of the porta hepatis only have been described in old world monkeys and lower mammals<sup>4,6,7</sup>.

Our patient also had an abnormality of the porta hepatis along with the other anomalies which probably led to the formation of a space between the two lobes of the liver wherein the transverse colon had interposed.

## **ACKNOWLEDGEMENT**

Thanks are due to Prof. A.H. Haqqani for his guidance, Surgeon Nizamul Hasan and the Radio-isotope Centre, Jinnah Postgraduate Medical Centre, Karachi.

## **REFERENCES**

1. McAfee, J.G., Ause, L.G. and Wagner, H.N.Jr. Diagnostic value of scintillation scanning of the liver; follow-up of 1,000 studies. *Arch. Intern. Med.*, 1965; 116:95.
2. Organ, C.H. Jr. and Hayes, D.F. Supradiaphragmatic right liver lobe and gallbladder. *Arch. Surg.*, 1980; 115:989.
3. Spellberg, M.A. *Diseases of the liver*. New York, Grime and Stratton, 1954, p. 319.
4. Sherlock, S. *Diseases of the liver and biliary system*. 5th ed. Oxford, BlackWell, 1975, pA.
5. Pujari, D.B. and Deodhare, S.G. Symptomatic accessory lobe of liver with a review of the literature. *Postgrad. Med. J.*, 1976; 52:234.
6. Ayer, A.A. and Thangavelu, M. Congenital anomaly of the liver. *J. Indian Med. Assoc.*, 1948; 17:291.
7. Arey, L.B. *Developmental anatomy; a textbook and laboratory manual of embryology*. 7th ed. London, Saunders 1965, p. 259.