

# Endometrioid Carcinoma of the Ovary: An Unusual Tumour in Young Females

Pages with reference to book, From 267 To 268

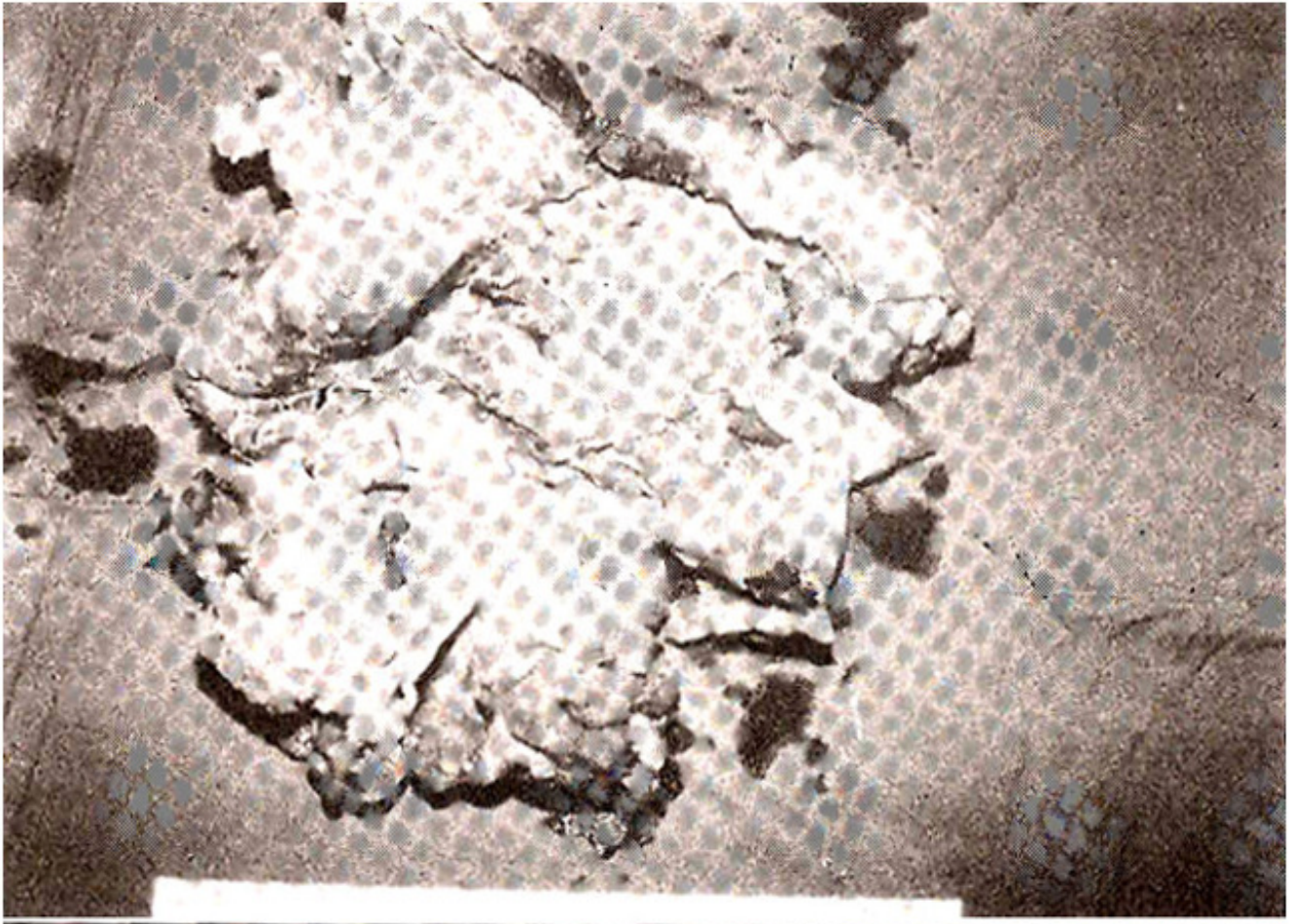
F. Demirci, U. Kuyumcuoglu, K. Sofuoglu, S. Eren, M.N. Delikara, R. Bilgic ( Zaynep Kamil Women and Children Hospital, Uskudar, Istanbul, Turkey. )

## Introduction

Endometrioid tumours of the ovary resemble common patterns of endometrial growth. Endometrioid epithelial neoplasms fall into four major categories: benign, proliferative, endometrioid tumours of low malignant potential and endometrioid carcinoma<sup>1</sup>. Endometrioid carcinoma is the third most common type of epithelial ovarian carcinomas<sup>2</sup> and comprising 16-30% of primary ovarian carcinomas<sup>3</sup>. The mean age is the fifth decade and it is rarely seen in young females.

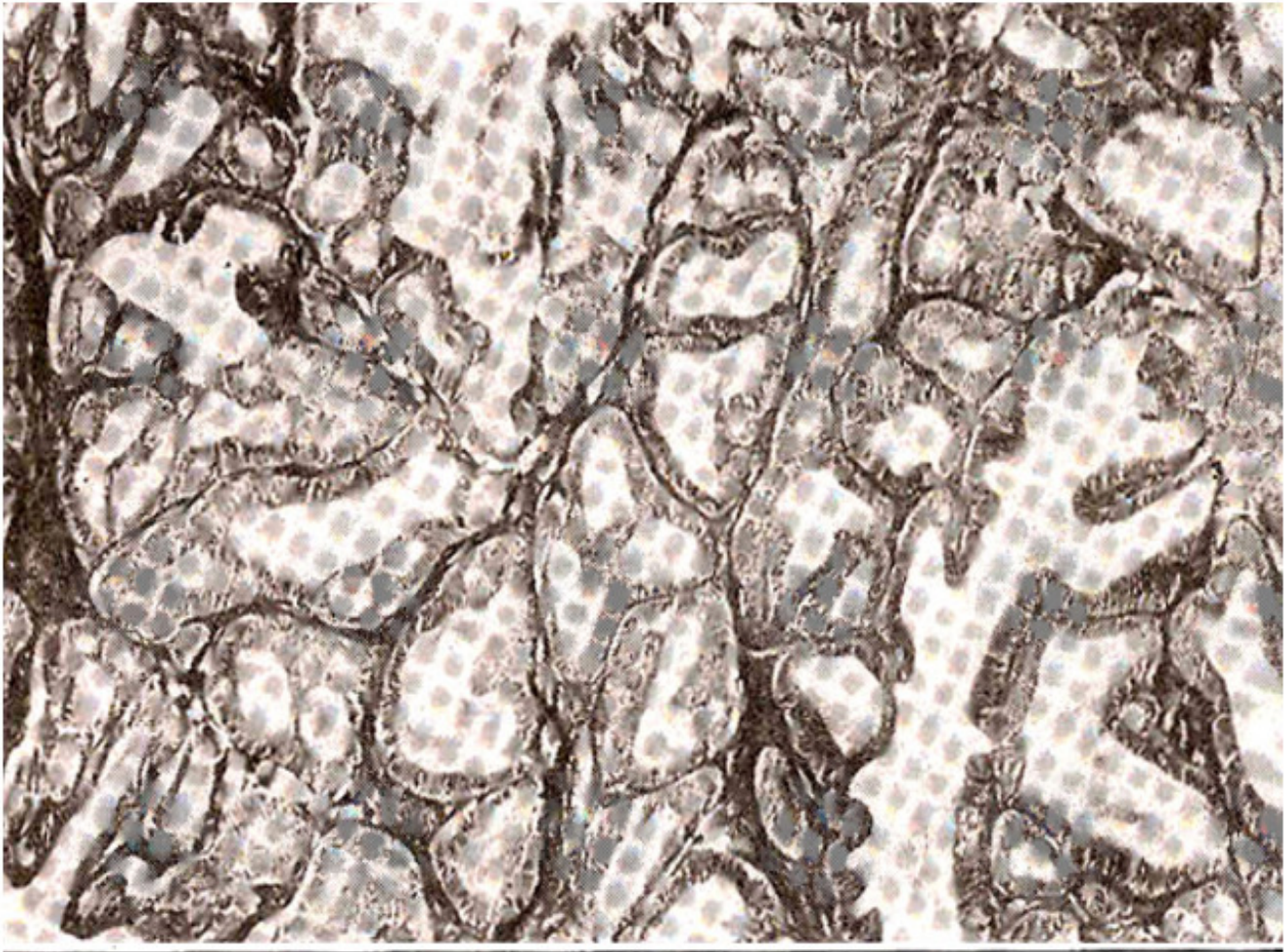
## Case Report

The 18 years old virgin patient was referred to our hospital by a general practitioner with complaints of lower abdominal pain and irregular menses of three months duration. There was no history of medical illness. On examination, a firm, mobile, smooth mass was found extending from pelvis to umbilicus, with normal sized uterus lying in front of the mass. Laboratory tests showed an erythrocyte sedimentation rate of 73 mm/h, serum CA was 125, CEA, BhCG, AFP, estradiol and testosterone were in normal ranges. Radiologic studies (CT, ultrasonography, IVP and barium enema) showed a 30x25x20 cm partly solid partly cystic smooth outer surfaced mass. The right ureter was not visible. The recto-sigmoid junction was externally depressed. On cystoscopic examination the right ureteral orifice was displaced to the midline and edema was present in bladder neck. D&C was performed and no pathologic finding was found. An exploratory laparotomy was performed through a midline supra and sub-umbilical incision. A left ovarian-originated tumour measuring 30x25x20 cm occupied the abdomen which contained yellow coloured fluid. There was some solid and necrotic areas but the capsule was smooth and there was no surface growth (Figure 1).



**Figure 1.**

There was no disease in the right adnexa and the uterus and other abdominal organs appeared normal. Peritoneal fluids were obtained from paracolic and subdiaphragmatic regions. Partial omentectomy, multiple peritoneal biopsies, appendectomy and left salpingoophorectomy was carried out. The specimen was sent for frozen section which was reported as borderline epithelial ovarian tumour with no tumour cells in peritoneal fluids. In view of these findings and regard for future reproductive function of the patient, the operation was ended. On paraffin sections, the tumour was reported as well differentiated endometrioid carcinoma and the patient was evaluated as stage Ia (Figure 2).



**Figure 2.**

## **Discussion**

The main cause of this presentation is that the tumour was found in a young female. As other epithelial ovarian tumours, ovarian endometrioid carcinoma is seen in elder patients<sup>4</sup>. Jensen and Norris reported malignant disease only in seven of 217 epithelial ovarian neoplasms aged between 15-19<sup>5</sup>.

Endometrioid carcinomas of the ovary tend to coexist with various forms of endometrial neoplasia<sup>6</sup>. The incidence of endometrioid carcinoma of the ovary coexisting with endometrial carcinoma of the uterus was reported between 5-29%<sup>2,7,8</sup>. Metastatic spread is more frequent in poorly differentiated tumours<sup>2</sup>. The prognosis of endometrioid carcinoma is better than those of other epithelial Ovarian tumours. The survival is partly better in the case of endometriosis in the same ovary<sup>9</sup>. The existence of squamous component may be a prognostic factor. The survival rate in ovarian carcinoma is influenced by stage, grade, residual tumour and also histologic type of the tumour<sup>10</sup>. The 5-year survival is reported as 95.5% in stage I, 28% in stage II, 4% in stage III and 0 in stage IV<sup>11</sup>. Another study reports the 10-year survival as 68-78%<sup>6</sup>. Radical operation was not considered because the patient is only 18 years old and not completed the reproductive function. The patient was taken under close follow-up.

## References

1. Norris, H.J. Proliferative endometrioid tumors and endometrioid tumors of low malignant potential of the ovary. *Int. J. Gynaecol. Pathol.*, 1993;12: 34-40.
2. Tidy, J. and Mason, W.P. Endometrioid carcinoma of the ovary: a retrospective study. *Br. J. Obst. Gynaecol.*, 1988;95:1165-69.
3. Hart, W. R. *Gynaecologic Oncology* Ed. Coppleson M. 2nd ed., Hong Kong, Churchill Livingstone, 1992;pp.876-78.
4. Smalley, H. and Sikora, IC. Age as a prognostic factor in epithelial ovarian carcinoma. *Br. J. Obst. Gynaecol.*, 1985;92:839-42.
5. Jensen, R. D. and Norris, H.J. Epithelial tumors of the ovary: Occurrence in children and adolescents less than 20 years of age. *Arch. Pathol.*, 1972;94:29-34.
6. Russel, R.S., Norris, H.J. and Tavassoli, F. Endometrioid proliferative and low malignant potential tumors of the ovary. *Am. J. Surg. Pathol.*, 1988; 12(9):661-71.
7. Hoffman, MS., Cavanagh, D., Walter, ST. et al. Adenocarcinoma of the endometrium and endometrioid carcinoma of the ovary associated with pregnancy. *Gynaecol. Oncol.*, 1989;32:82-85.
8. Klemi, P. S. and Gronroos, M. Endometrioid carcinoma of the ovary. A clinicopathologic, histochemical and electron microscopic study. *Obstet. Gynaecol.*, 1978;53:572-79.
9. Brescia, R.J., Dubin, N. and Demopoulos, RI. Endometrioid and clear cell carcinoma of the ovary. *Int. J. Gynaecol. Pathol.*, 1989;8:132-38.
10. Kline, R.J., Wharton, J.T. and Atkinson, E.N. Endometrioid carcinoma of the ovary. Retrospective review of 145 cases. *Gynaecol. Oncol.*, 1990;39:337-46.
11. King, PA., Li, D.FH. and Ma, H.K. Endometrioid carcinoma of the ovary an unusual cause of postpartum collapse. Case report. *Br. J. Obst. Gynaecol.*, 1989;96: 1000-1002.