

Piezogenic Papules - A Study of 100 Cases

Pages with reference to book, From 93 To 94

Z. Zaidi, N. Jafri, B. Noori (Department of Dermatology, Jinnah Postgraduate Medical Centre, Karachi.)

H. Thawerani (Department of Dermatology, Sind Laboratory, Karachi.)

Abstract

Hundred people were examined for piezogenic papules (cutaneous hernia). Of these 80 had pedal papules, 86 wrist papules and 74 both pedal and wrist papules. Most of these papules were bilateral and multiple.

All cases examined were painless. Biopsy showed fragmentation of dermal elastic tissue and herniation of subcutaneous fat into the dermis. Histology was similar for both pedal and wrist papules (JPMA 45: 93, 1995).

Introduction

Piezogenic papules are herniation of subcutaneous fat into the dermis. These present as soft skin coloured papules which appear on application of pressure and disappear on removal of force. They are therefore called piezogenic. (Piezo=pressure and gen= giving rise to)^{1,2}. Piezogenic pedal papules were first described by Shelley and Rowsley in 1968³ and piezogenic wrist papules by Valerie B. Liang et al in 1991⁴.

Patients and Methods

One hundred patients were examined for piezogenic papules from the outpatient clinic of the hospital. These included people from all walks of life, none had any history of collagen tissue defect, nor were they exposed to any vigorous physical activity. Piezogenic pedal papules were examined by making the patient stand and applying pressure on the heels. These papules appeared just above the heel. Piezogenic wrist papules were examined by placing the heels of both palms together and applying pressure. These were seen on the ventral aspect of the wrist. Both these papules appeared on pressure and disappeared on removal of force. As these papules were painless most of the people were unwilling for biopsy. We were able to biopsy a few cases, these included two wrist papules and one pedal papule (Figures 1 and 2).

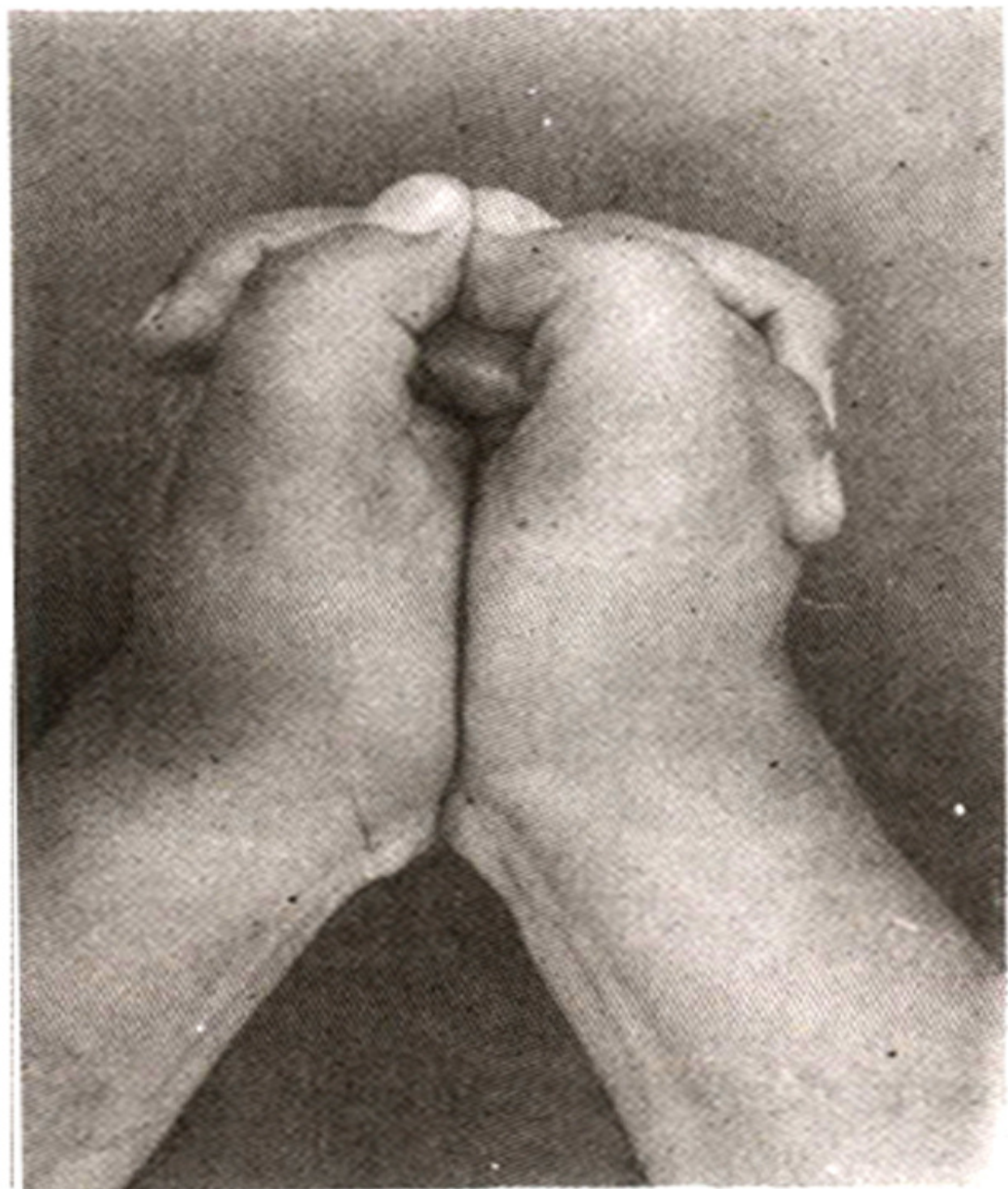


Figure 1. Piezogenic wrist papules.

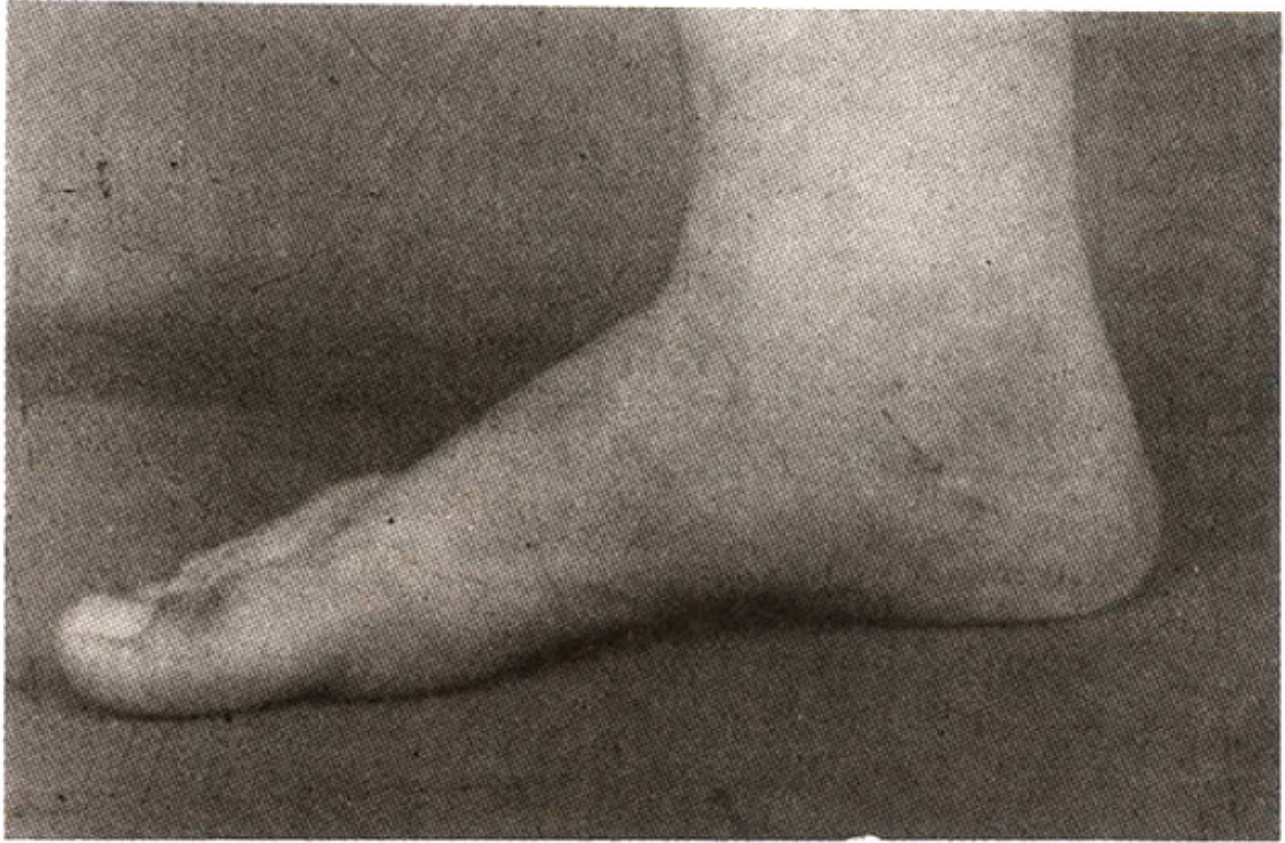


Figure 2. Piezogenic pedal papule.

Result

Of 100 cases examined, 80 had pedal, 86 wrist and 74 both pedal and wrist papules. All cases were multiple, bilateral and painless papules. Pedal papules were mainly on the medial side of the heel and the maximum number seen were eight papules. Age of these patients ranged from 11 to 60 years (Mean 28 years) with maximum number between 20-30 years, in both pedal and wrist papules. There were 56 males and 24 females in pedal and 58 males and 28 females in the wrist papules. Both pedal and wrist papules were biopsied during application of pressure. Histology was similar for both wrist and pedal papules. Hematoxylin and Eosin stained sections showed normal epidermis; with fragmentation of dermal elastic fibres which appeared bluish amongst eosinophilic collagen bundles of the dermis. A lobule of subcutaneous adipose tissue was seen herniating in the lower dermis. Sweat glands and ducts included in the biopsy were normal. Fragmentation of the elastic tissue fibres was confirmed by the Verhoeff-Van-Geison stain. Biopsy of the pedal papule also showed fragmentation of the elastic tissue fibres in the dermis (Figure 3).

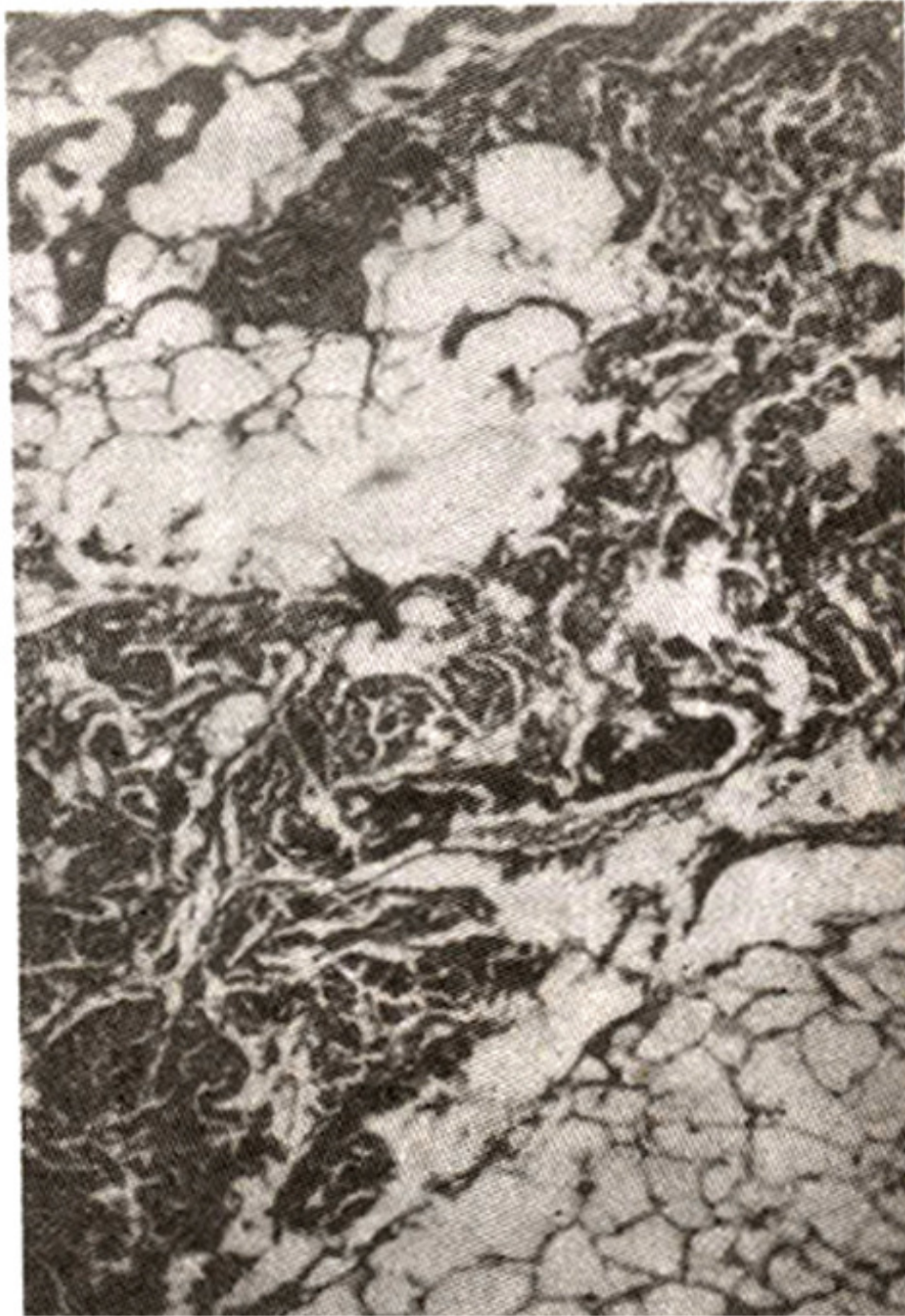


Figure 3. Herniation of sub-cutaneous fat into the dermis (higher magnification).

Discussion

Piezogenic papules were present in most of the people examined. Eighty percent had pedal papules, 86% wrist papules. Similar frequency is reported by Valerie B. Liang⁴. When examined bimanually in one study⁵ all 250 cases had pedal papules. However, in another study, only 10 cases of Piezogenic papules were present out of 250 cases examined. Otto Schlappner et al⁵ found 58 papules on the right

and 40 on left heel, while we saw a maximum of 8 papules in one individual. Maximum age frequency of 20-30 years is similar to other studies⁶. Painless papules represent the peripheral fat chambers of the normal heel⁵. Painful papules are larger and are formed by the fusion of small fat chambers as the separating trabeculae of subcutaneous fat degenerate and are destroyed^{5,7}. Pain is due to ischaemia which results from the extension of fat with its vessels and nerves^{3,5}. No evidence of fat necrosis, vascular change and inflammation was reported by Harman et al⁸. Elimination of pressure, heel supports, physiotherapy and in some cases simple surgical removal have been advised as treatment for painful pedal papules⁹. As painful papules are found in only a small number of cases, it could be due to a latent or inherent defect of connective tissue^{4,5,10}. Kabana et al found painful pedal papules in 10 out of 29 cases of Ehlers-Danlos Syndrome and suggested that these papules should be included as one of the clinical features of this syndrome¹⁰. Only a few cases of painless piezogenic papules have been biopsied. There was normal anatomical relationship of fat and fibrous tissue, which formed a well supported cushion between bone and skin⁵. The histology of painless wrist papule demonstrated normal epidermal, dermal and subcutaneous architecture⁴. We biopsied one pedal and two wrist papules and found common histological feature of fragmented elastic tissue fibres present amongst the collagen bundles in all biopsies. We believe that this creates an area of decreased resistance in the dermis, which allows the subcutaneous fat to herniate upwards. Wrist and ankle joints are exposed to repeated physical activity, which appears to be a significant contributory factor for the fragmentation of elastic tissue fibres in the dermis and formation of a Piezogenic papules. Painless piezogenic papules are a common finding, which go unrecognised as they are symptomless. Only a few of these papules become painful; these are the ones which come to medical attention.

References

1. Cohen, H. J., Gibbs, R. C., Minkin, W. et al. 'Painful piezogenic pedal papules Arch. Dermatol., 1970; 101:112-13.
2. Lebovits, P. E. and Kouskoukis, C. E. and Weidman, A. L. Piezogenic pedal papules Cutis, 1982;29:276-80.
3. Shelley, W. B. and Rawnsley, H. M. Painful feet due to herniation of fat JAMA.. 1968;205 :308-9.
4. Liang, V. L. and Fleischer, A.B 'Piezogenic wrist papules'. A common and symptomatic finding. 3. Am. Acad. Dermatol., 1991;24:415-17.
5. Schlappner, O. A., Wood, M. G., Gerstein, W. et al. Painful and Nonpainful Piezogenic papules Arch. Dermatol., 1972; 106:729-33.
6. Kohn, S. R. and Blasi, J. M. 'Piezogenic pedal papules'. (Letter to the Editor). Arch. Dermatol., 1972;106:597-98.
7. Douglas, S. and Grant, A. 'Piezogenic pedal papules'. Letter to the Editor. Arch. Dermatol., 1970;101 :619.
8. Harman, R. R. M. and Mathews, C. N. 'Painful piezogenic pedal papules' Br. J. Dermatol., 1974;90:573-74.
9. Jack, S. 'Painful piezogenic pedal papules'. A case history. J. Am. Podiatr. Med. Assoc., 1977;67: 120-21.
10. Kahana, M. Feinstein, A., Tabachnic, E. et al. 'Painful piezogenic pedal papules in patients with Ehlers-Danlos Syndrome'. J. Am. Acad. Dermatol.. 1987;17:205-209.