

Familial presence of early onset Fuchs' corneal endothelial dystrophy, a report of two rare cases

Tanveer Anjum Chaudhry, Amina Adil, Faraz Kazmi, Khabir Ahmad
 Section of Ophthalmology, Department of Surgery, Aga Khan University, Karachi.
 Corresponding Author: Tanveer Anjum Chaudhry. Email: tanveer.chaudhry@aku.edu

Abstract

A 15-year-old girl presented to our clinic with a history of gradual loss of vision and photosensitivity. She had bilateral corneal haze with stromal oedema. Her best-corrected visual acuity was 20/400 in the right eye and 20/200 in the left. She underwent penetrating keratoplasty in both eyes. Corneal histopathology revealed a pattern similar to Fuchs' endothelial dystrophy. The graft settled well and stayed clear while the vision kept improving. Her brother also presented with similar symptoms.

Keywords: Fuchs' corneal endothelial dystrophy, Penetrating keratoplasty, Familial.

Introduction

Fuchs' endothelial corneal dystrophy, first described by Austrian Ophthalmologist, Ernst Fuchs (1851-1930) in 1910, is a rare inherited and slowly progressing eye disease. It is characterized by degeneration of the epithelial layer of the cornea.¹ Patients often present with blurring of vision in the morning. On eye examination, the presence of guttae, corneal oedema and, later on, epithelial bullae indicates the presence of Fuchs' endothelial corneal dystrophy. Women are slightly more likely to have this disease. The disease usually affects both eyes, but rarely affects visual acuity until the age of 50 years. Smoking has been shown to increase the risk. However, the role of prevention of this disorder remains unclear. Where visual loss is substantial, corneal transplantation is indicated. In North America and Europe, this disorder is a common indication of penetrating keratoplasty.

Cases:

A 15-year-old girl from Karachi presented to the Ophthalmology outpatient services at the Aga Khan University Hospital, Karachi with a history of gradual reduction in her

vision and increased sensitivity to light. Few weeks later her brother aged 18 years also presented to our clinic with the same history. According to her mother, her daughter first complained of blurring of vision when she was 12 years of age followed by a gradual worsening of vision over the next 3 years. By contrast, her son first developed symptoms at the age of 15 with gradual worsening over the next 3 years but with less severity. Their two elder siblings, both boys, did not have similar symptoms but one of them had been diagnosed with red green color blindness at the age of 18. The parents of the two affected children are second cousins but neither of them as well as other family members had any worsening of vision at similar age. The children did not have any systemic illnesses.

The girl had her first visit to our clinic in February 2006 when her best-corrected visual acuity (BCVA) was 20/30 in both eyes. We noticed a rapid reduction in her vision in both eyes in the subsequent one and a half year. Her BCVA, as recorded in September 2007, was 20/400 in the right eye and

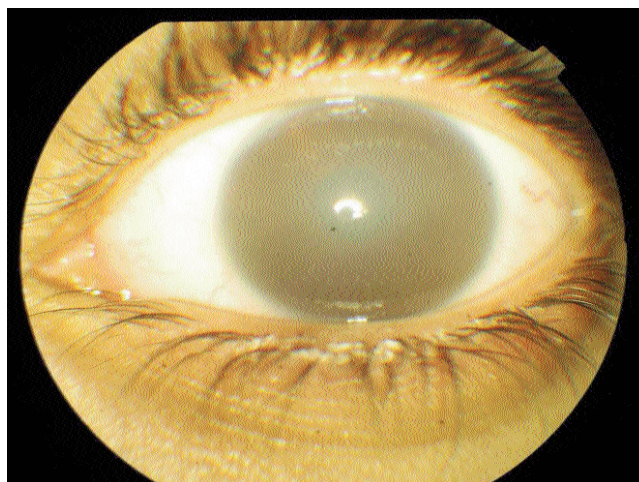


Figure-1: Corneal haze in one of the eyes.

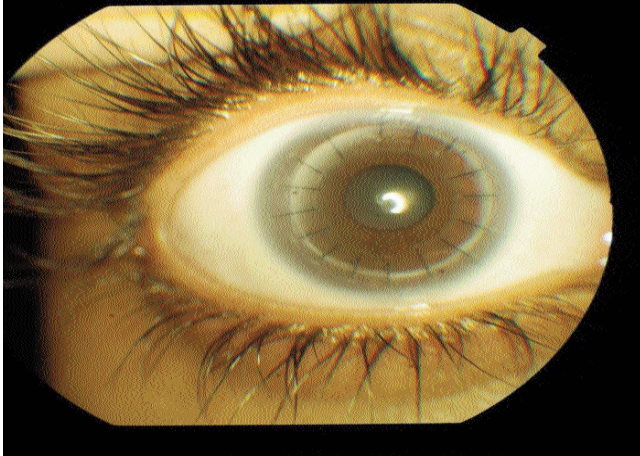


Figure-2: Post PKP appearance of the right eye.

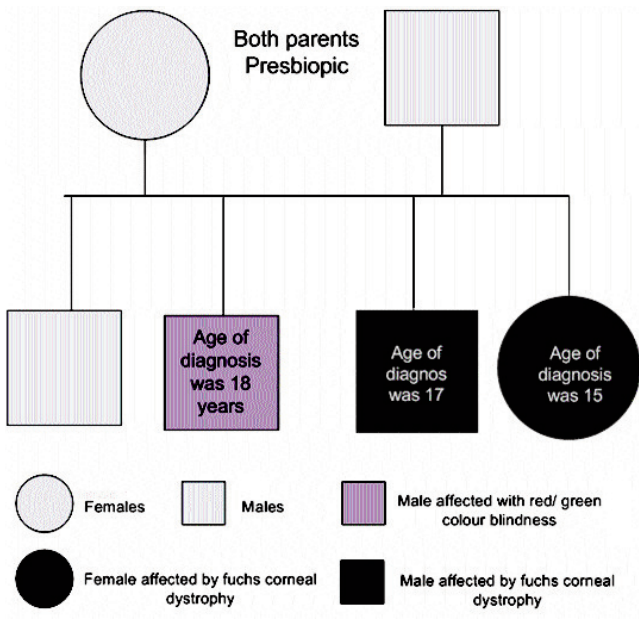


Figure-3: Family tree of the affected siblings.

20/200 in the left. Slit lamp examination of her eyes revealed bilateral diffuse corneal haze. Sub-stromal thickening and guttata were noticed and a provisional diagnosis of corneal endothelial dystrophy was made. Treatment option of penetrating keratoplasty (PKP) was discussed with the parents and on January 14, 2008, she underwent right PKP under general anaesthesia. Corneal histopathology revealed a pattern similar to Fuchs' endothelial dystrophy with intact epithelium and Bowman's membrane and focal thickening of Descemet's membrane with paucity of endothelial cells. The graft settled well and stayed clear while the vision kept improving. She was on standard regime of Moxifloxacin and Dexamethasone eyes drops. Subsequently, she developed diffuse corneal oedema, but

it settled with time with no permanent consequences for the graft. In November 2009, a mild form of anterior uveitis was also noticed in the same eye. However, the vision was stable at 20/30 and remains so to date. The left eye also showed gradual reduction in vision and by August 2008, vision had dropped to counting fingers at two feet. She received PKP in the left eye on June 14, 2009 under general anaesthesia. The graft settled well with significant improvement in the vision. To date, the left graft is also clear and the BCVA is 20/40.

Her brother presented with similar complaints of photophobia and bilateral reduction of vision over the course of two years. The last recorded vision shows BCVA of 20/40 in the right and 20/50 in the left eye. On examination, he had similar corneal findings, but of less severe nature.

Discussion

To the best of our knowledge, there have been no reported cases of early onset Fuchs' endothelial dystrophy that required a penetrating keratoplasty at an age as early as 16 years. Its onset is generally in the fifth through seventh decades of life. There have been only few reports in the published literature on early-onset Fuchs' endothelial dystrophy and perhaps none where reduction in the vision has been so rapid, requiring PKP at such an early age. For example, a report² describing a British family with 3 affected members showed that it generally took many years before the vision was reduced sufficiently to require PKP. In the British series, the youngest of the three family members had a corrected vision of 6/6 even till 18 years of age. Two more cases of Fuchs', one aged 9 years and the other 10 years, both girls and not related to each other, were reported from India.³ Both had corneal haze from birth and may represent congenital Fuchs' endothelial dystrophy, distinguishing them from the case we report.

Fuchs' endothelial dystrophy is currently a common reason for corneal transplantation in the United States and Europe.⁴ Pineros and colleagues⁵ assessed the results after penetrating keratoplasty for Fuchs' endothelial dystrophy. In their series, the mean age at the time of keratoplasty was 62.1 ± 8.5 years (range 43 to 79 years) which means that keratoplasty for early onset Fuchs' dystrophy is rare. The same series also revealed that prognosis of the grafts for late onset Fuchs' dystrophy was promising. In our case, the graft in both eyes remained clear and had good visual outcome. Long term prognosis needs to be assessed. Approximately half of the cases of Fuchs' endothelial dystrophy are familial,⁶ with a female preponderance.⁷ However we did not investigate the affected individuals or their family members for genetic mutations. We understand that pachymetry (measurement of corneal thickness) on each follow up could have added value to this case report, but we were limited by the non-availability of the needed equipment. Similarly, facilities for endothelial cell count were also not available. Although these could have better illustrated

the case, our focus was to report the early onset of this condition, rather than its management.

We conclude that the cases of Fuch's endothelial dystrophy reported, not only had early onset, but one of them also had an exceptionally rapid deterioration of vision.

References

1. Eghrari AO, Gottsch JD. Fuchs' corneal dystrophy. *Expert Rev Ophthalmol* 2010; 5: 147-59.
 2. Liskova P, Prescott Q, Bhattacharya SS, Tuft SJ. British family with early-onset Fuchs' endothelial corneal dystrophy associated with p.L450W mutation in the COL8A2 gene. *Br J Ophthalmol* 2007; 91: 1717-8.
 3. Dystrophy CF, Malik SR, Singh G. Congenital Fuchs dystrophy. *Indian J Ophthalmol* 1971; 19: 71-6.
 4. Doctor DW, Traynor EM. Penetrating keratoplasty, in Fuchs' corneal dystrophy. *Am J Ophthalmol* 1962; 54: 812-6.
 5. Pineres O, Cohen EJ, Rapuano CJ, Laibson PR. Long-term results after penetrating keratoplasty for Fuchs' endothelial dystrophy. *Arch Ophthalmol* 1996; 114: 15-8.
 6. Gottsch JD, Sundin OH, Liu SH, et al. Inheritance of a novel COL8A2 mutation defines a distinct early-onset subtype of fuchs corneal dystrophy. *Invest Ophthalmol Vis Sci* 2005; 46: 1934-9.
 7. Sundin OH, Jun AS, Broman KW, et al. Linkage of late-onset Fuchs corneal dystrophy to a novel locus at 13pTel-13q12.13. *Invest Ophthalmol Vis Sci* 2006; 47: 140-5.
-