

## Acute necrotizing encephalopathy associated with novel influenza A (H1N1) virus in Turkey

Mustafa Komur,<sup>1</sup> Cetin Okuyaz,<sup>2</sup> Ali Ertug Arslankoylu,<sup>3</sup> Engin Kara,<sup>4</sup> Aytug Atici<sup>5</sup>

Department of Pediatric Neurology,<sup>1,2</sup> Department of Pediatrics,<sup>3,5</sup> Department of Radiology,<sup>4</sup> Mersin University School of Medicine, Mersin, Turkey.

### Abstract

Influenza-associated acute necrotizing encephalopathy has been well recognized but not yet been reported with novel influenza A in Turkey. We report a 6-year-old boy infected with novel influenza A who displayed the typically characteristic clinical features and neuroimaging findings of acute necrotizing encephalopathy. Physicians who care for children should be aware of acute necrotizing encephalopathy in any child presenting with acute mental status changes during influenza infection. We would like to remind of this entity, because early diagnosis and treatment may reduce mortality and morbidity.

**Keywords:** Acute necrotizing encephalopathy, Gammaglobulin, Novel influenza A (H1N1).

### Introduction

The neurologic complications of influenza A virus include seizures, encephalitis, Reye syndrome and acute necrotizing encephalopathy (ANE). ANE is characterized by multifocal symmetric brain lesions in the thalamus, cerebellum, brainstem and periventricular white matter.<sup>1</sup> The clinical course of ANE is rapidly progressive, including symptoms of cough, fever, vomiting in combination with neurologic dysfunction such as rapid alteration of mental status and seizures. It has not been reported yet in association with novel influenza-A in Turkey, so we present a case to increase awareness about this complication.

### Case Report

A previously healthy 6-year-old boy was taken to the family doctor with the complaints of high fever, rhinorrhea, cough and vomiting in November 2009. He was diagnosed with acute tonsillitis and was given oral antibiotics and antipyretics. The next day, he was lethargic and had generalized tonic-clonic convulsions. He was admitted to another hospital and treated with midazolam and phenytoin infusion. His mental status fluctuated and then progressively declined. Brain magnetic resonance imaging (MRI) on hospital day 2 revealed symmetric high signal intensity lesions in the subcortical white matter of bilateral frontoparietal and thalamus (Figure-1). The patient was referred to our hospital two days later due to persistent

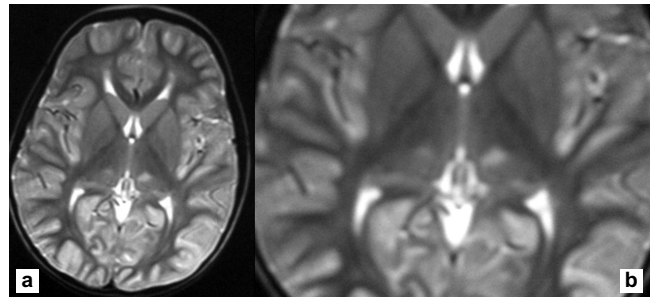


Figure-1: (a) Axial T2-weighted image shows symmetric increased signal intensity in the thalami. (b) The enlarged image of the same lesion.

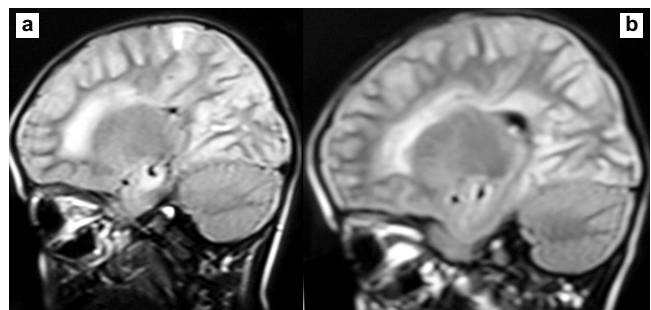


Figure-2: Sagittal FLAIR images (2a and 2b) show symmetric increased signal intensity in the cerebral periventricular and subcortical white matter.

impairment of consciousness. The medical history was negative for recent travel, exposure to other drugs including acetylsalicylic acid and family history of neurological disorders. The child was fully immunized but had not received H1N1 immunization. On arrival at our paediatric intensive care unit, he was comatose. His body temperature was 37.6°C. On neurological examination, Glasgow coma scale was 6/15, pupils were equally reactive, deep tendon reflexes were brisk, plantar responses were extensor and bilateral ankle clonus was noted. Brain stem reflexes were intact. Laboratory investigations showed normal values of electrolytes, urea, creatinine, creatine phosphokinase (CK), lactic dehydrogenase (LDH), aspartate aminotransferase (AST), alanine aminotransferase (ALT), lactate, ammonia and erythrocyte sedimentation rate. Blood glucose was 142 mg/dl and C-reactive protein was 20 mg/dl (normal limit <5). Complete blood count revealed a white blood cell count of

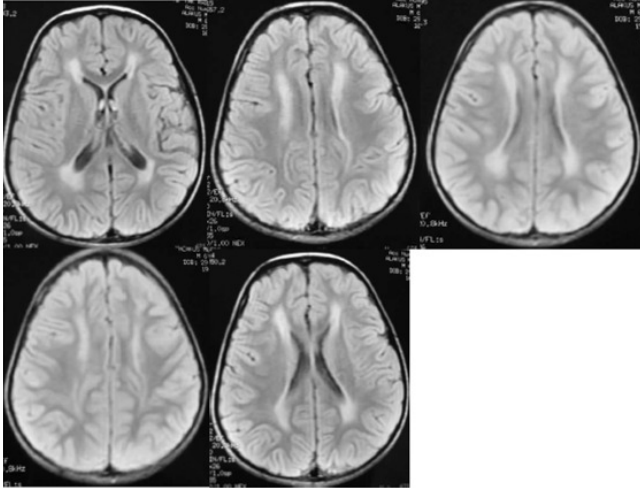


Figure-3: Axial FLAIR images show symmetric increased signal intensity in the cerebral white matter. (periventricular, subcortical and supratentorial localized).

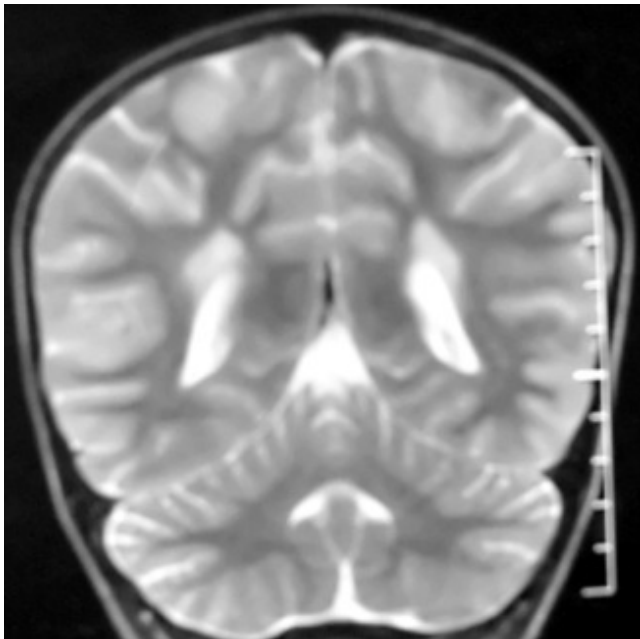


Figure-4: Coronal T2 weighted image shows symmetric increased signal intensity in periventricular white matter.

10200/ $\mu$ l and the platelet count of 153000/ $\mu$ l. Cerebrospinal fluid (CSF) analysis revealed no cells, glucose: 110 mg/dl, protein: 29 mg/dl (normal range 15-45 mg/dl). CSF opening pressure was not measured. Herpes simplex virus-1 IgM and measles IgM were negative in the CSF. His electroencephalography showed generalized 2-4 Hz delta-theta wave slowing.

The patient was treated with phenytoin and midazolam infusions for convulsions. Because of possible acute disseminated encephalomyelitis (ADEM), pulse steroid

treatment was started (30 mg/kg/day methylprednisolone) on the first day at our hospital, but on the second day steroid was switched to intravenous gammaglobulin (IVIg) 0.4 gr/kg/day for 5 days because acute viral encephalitis could not be ruled out. On day 5 in our hospital, his mental status improved and he did not experience further convulsions. Nasopharyngeal swab specimen was collected from patient on day 3 in our hospital and tested for H1N1 by real-time reverse transcription-polymerase chain reaction (RT-PCR) in Refik Saydam National Public Health Agency, Ankara, using the RT-PCR protocol and reagents supplied by the Centers for Disease Control and Prevention, Atlanta, USA (2) and the result was positive on the seventh day. Antiviral treatment for H1N1 was not administered, because his mental status showed good recovery and symptoms regressed.

The patient was discharged when he returned to his previous mental state after 12 days of hospitalization. Neurological examination was normal on follow-up visit at 3 weeks.

## Discussion

ANE, first described by Mizuguchi et al. in 1995, is characterized with alteration of mental status, seizures and coma during a viral upper respiratory infection.<sup>1</sup> Human herpes virus-6, human herpes virus-7, measles, parainfluenza, varicella, rubella, influenza-B and especially influenza-A viruses and mycoplasma have been associated with ANE. The proposed diagnostic criteria for ANE include: 1) rapid loss of consciousness, convulsions and coma ensuing within 24 hours; 2) neuroimaging showing multiple symmetrically distributed brain lesions, in the thalamus, brainstem, periventricular white matter and cerebellum; 3) absence of hyperammonaemia and hypoglycaemia; 4) no history of aspirin intake; 5) increased CSF protein without pleocytosis.<sup>3,4</sup> Our case presented these diagnostic criteria with the exception of normal CSF protein. The CSF protein level was not elevated in our case. According to Mizuguchi et al. 78 percent cases show elevated CSF protein level.<sup>1</sup> The virological diagnosis by RT-PCR allowed us to consider H1N1-associated ANE.

The differential diagnosis of ANE include viral and post-infectious encephalitis, ADEM, Reye's syndrome, mitochondrial disorders and exposure to toxins such as carbon monoxide, methanol and cyanide. We excluded these disorders by history and clinical course. ADEM was excluded with neuroimaging findings. Moreover, ADEM has a prolonged course, prominent focal signs asymmetric or atypical distribution of brain lesions incompatible with ANE.<sup>5</sup>

The prognosis of ANE is usually poor. Its mortality reaches 30% and less than 10% recover completely. The prognosis is better in children older than 4 years, in those who have normal ALT, AST, LDH and CK levels and those without

brainstem lesions on neuroimaging.<sup>3,4,6</sup> Our case carried all of these features and recovered completely within 3 weeks.

The pathogenesis of ANE is unclear. Ichiyama et al. found elevated serum cytokine levels in a patient with ANE.<sup>7</sup> Okumura et al. recently considered the role of hypercytokinemia in the pathogenesis and as mentioned above, Okumura et al. suggested early pulse steroid treatment may be effective in the treatment of ANE. According to our case's treatment, IVIg is also effective in treatment of ANE without brainstem lesions. IVIg may be treatment of choice in patients where pulse steroid treatment is contraindicated.<sup>8</sup> Our case received methylprednisolone 30 mg/kg/day for one day and then IVIg. His remarkable recovery may have been due to the absence of brainstem lesions and early steroid treatment. Moreover, we consider that IVIg may have a role in early recovery.

Recently H1N1 associated ANE have been described, reported from Italy and USA.<sup>9,10</sup> To our knowledge, our case is the first report of H1N1-associated ANE from Turkey. Although influenza is a relatively benign illness, physicians who care for children should be aware of ANE in any child presenting with acute mental status changes during influenza infection. Because early diagnosis and treatment may reduce mortality and morbidity.

## References

1. Mizuguchi M, Abe J, Mikkaichi K, Noma S, Yoshida K, Yamanaka T, et al. Acute necrotising encephalopathy of childhood: a new syndrome presenting with multifocal, symmetric brain lesions. *J Neurol Neurosurg Psychiatry* 1995; 58: 555-61.
2. Ciblak MA, Albayrak N, Odabas Y, Basak Altas A, Kanturvardar M, Hasoksuz M, et al. Cases of influenza A(H1N1)v reported in Turkey, May-July 2009. *Euro Surveill* 2009; 14: pii=19304.
3. Huang SM, Chen CC, Chiu PC, Cheng MF, Lai PH, Hsieh KS. Acute necrotizing encephalopathy of childhood associated with influenza type B virus infection in a 3-year-old girl. *J Child Neurol* 2004; 19: 64-7.
4. Yoshikawa H, Watanabe T, Tokinari A, Oda Y. Clinical diversity in acute necrotizing encephalopathy. *J Child Neurol* 1999; 14: 249-55.
5. Weitkamp JH, Spring MD, Brogan T, Moses H, Bloch KC, Wright PF. Influenza A virus-associated acute necrotizing encephalopathy in the United States. *Pediatr Infect Dis J* 2004; 23: 259-63.
6. Wong AM, Simon EM, Zimmerman RA, Wang HS, Toh CH, Ng SH. Acute necrotizing encephalopathy of childhood: correlation of MR findings and clinical outcome. *AJNR Am J Neuroradiol* 2006; 27: 1919-23.
7. Ichiyama T, Endo S, Kaneko M, Isumi H, Matsubara T, Furukawa S. Serum cytokine concentrations of influenza-associated acute necrotizing encephalopathy. *Pediatr Int* 2003; 45: 734-6.
8. Okumura A, Mizuguchi M, Kidokoro H, Tanaka M, Abe S, Hosoya M, et al. Outcome of acute necrotizing encephalopathy in relation to treatment with corticosteroids and gammaglobulin. *Brain Dev* 2009; 31: 221-7.
9. Lyon JB, Remigo C, Milligan T, Deline C. Acute necrotizing encephalopathy in a child with H1N1 influenza infection. *Pediatr Radiol* 2010; 40: 200-5.
10. Ormitti F, Ventura E, Summa A, Picetti E, Crisi G. Acute necrotizing encephalopathy in a child during the 2009 influenza A(H1N1) pandemic: MR imaging in diagnosis and follow-up. *AJNR Am J Neuroradiol* 2010; 31: 396-400.