

## Mucinous adenocarcinoma of the appendix

Rauf Shaikh, Khursheed A. Samo, Aun Ali, Summaya Saeed, Amjad Siraj Memon  
Surgical Unit-V, Dow University of Health Sciences, Civil Hospital, Karachi.

### Abstract

Mucinous neoplasm is a rare malignancy of the gastrointestinal tract, the most common site being the appendix. There are different types of mucin producing tumours that can occur in the appendix, which can be benign as well as malignant. Mucin produced by these tumours results in ascites that makes it palpable as jelly belly.

**Keywords:** Appendix, Mucinous adenocarcinoma, Hemicolectomy, Chemotherapy, Radiotherapy.

### Introduction

Mucinous Adenocarcinoma is the commonest cancer of the appendix. The tumour commonly invades soft tissues and organs but can grow faster and can metastasize to the lymph nodes. The treatment for Mucinous Adenocarcinoma when confined to the appendix is appendicectomy and right hemicolectomy.<sup>1</sup> The most common presentation is appendicitis and diagnosis is usually established in histopathology after appendicectomy.<sup>2</sup> An estimated 1% of

all the appendectomy specimens are neoplastic. The majority of appendiceal tumours are carcinoid while the remaining 20% are mucinous cystadenocarcinoma, adenocarcinoma, lymphosarcoma and paraganglioma.<sup>3</sup>

One of our patient developed peritonitis secondary to perforation in jejunum with multiple strictures for which exteriorization of jejunum was done. Later during her stoma reversal, fibrosed and thickened appendix was seen which was removed and sent for histopathology and biopsy which reported it to be a mucinous neoplasm of Appendix.

We report a case of mucinous adeno carcinoma of the appendix that was diagnosed in one of our patients while performing a stoma reversal.

### Case Report

A 32-year-old married female presented in shock with acute peritonitis. Her basic investigations were done and X-ray chest erect view confirmed the diagnosis of bowel perforation. She underwent exploratory laparotomy which revealed a perforation along with a stricture in the jejunum 3 feet from the duodenojejunal junction and multiple strictures in the ileum. Her perforation was exteriorized and she was started on Anti tuberculous therapy based on tissue diagnosis which was from one of the strictures. However, in emergency only a jejunostomy was performed and nothing was done for the multiple strictures because of the compromised clinical condition of the patient. She had also been diagnosed with pulmonary tuberculosis in the past for which she was treated for 4 months. She did well postoperatively and was discharged home on Anti tuberculous therapy with a plan of stoma reversal after 6 weeks. Before reversal, distal loopogram was done which was normal. Despite this fact stoma reversal was planned through laparotomy due to multiple strictures identified during previous surgery for which nothing was done earlier. At the time of stoma reversal, just distal to the jejunostomy three strictures were identified and that part of the bowel was resected. Margins of the stoma were refashioned and an end-to-end anastomosis was performed. However, her appendix looked fibrosed, unhealthy and thickened so appendectomy was carried out

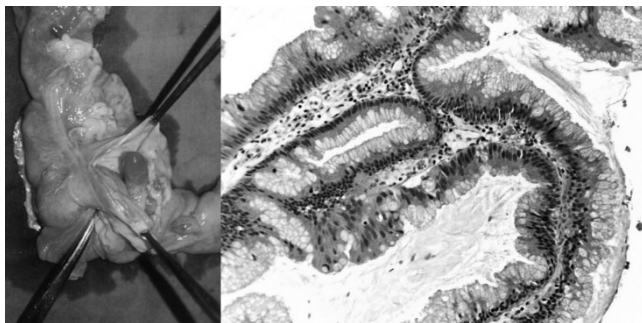


Figure: Intermediate grade mucinous tumour of the appendix.

and specimen sent for histopathology. The histopathology report revealed a low grade mucinous neoplasm. Appendiceal wall showed extracellular pools of mucin, which was also present on the serosal surface. As all slides showed neoplastic changes so the size of appendix was taken as the size of tumour. Computed tomography was done in order to find out the involvement of other structures, which were normal. With the plan of right hemicolectomy, a laparotomy was performed during which a mass was identified near distal jejunum and close to the ileum which was dissected and primary anastomosis was done. Multiple lesions resembling a tuberculoma were present in the mesentery of small bowel and multiple adhesions were identified for which adhesiolysis was done. Iliocolic and right branch of middle colic artery were identified and ligated, right hemicolectomy and ileotransverse anastomosis was done, and the abdomen was closed. The histopathology report of the mass in the jejunum was unremarkable, except for the evidence of a small stricture and the histopathology of the right hemicolectomy specimen showed dense acute and chronic inflammation. She did not receive any chemotherapy as advised by the oncology team and was continued on Antituberculous therapy. She is on regular follow up 4 months post-operatively.

### Discussion

Mucinous adenocarcinoma is the most common cancer of the appendix. It accounts for 37% of all appendix neoplasms.<sup>4</sup> This tumour may grow faster and can metastasize to the lymph nodes, liver and lungs. Survival in this type of tumour group is significantly worse than the other appendiceal carcinomas and it should be considered as a separate type of appendiceal malignancy because of its poor prognosis.<sup>4</sup> The term for extensive spread of these tumours in the abdomen is peritoneal mucinous carcinomatosis.<sup>5</sup> It can also lead to pseudomyxoma peritonei that is commonly used to refer to widespread mucinous disease in the abdomen caused by either mucinous adenoma or mucinous adenocarcinoma. The presentation can mimic acute appendicitis, right iliac fossa (RIF) mass and intestinal obstruction.<sup>6</sup> Mucinous neoplasm can also present with uncommon anatomical anomalies such as intestinal malrotation and situs inversus.<sup>7</sup> Right hemicolectomy is considered to be the treatment of choice for the lesion beyond the mucosa and appendectomy alone for a localized lesion. The role and safety of laparoscopic appendectomy for management of the incidentally discovered appendiceal tumours has not been established.<sup>8,9</sup> Adjuvant multimodal treatment prevents the disease progression. One of the related studies mentioned that three cycles of Capecitabine 1250/m<sup>2</sup> from day 1-14, oxaliplatin 130mg/m<sup>2</sup> on day 1, and (CAPOX) every 21 days, followed by a total dose of 50.4 GY external-beam radiation therapy improved the life

expectancy.<sup>10</sup> Appendiceal neoplasm as an incidental finding in a tuberculous abdomen is a rare entity and hence gave an entirely new dimension to the treatment for this patient.

### Conclusion

Appendiceal neoplasm are usually diagnosed when patients present with pain, mass in RIF or intestinal obstruction. This case reaffirms the fact that thorough examination of the abdominal viscera at the time of surgery can give an accurate diagnosis.

### References

1. Katsuno G, Kagawa S, Kokudo Y, Muraoko A, Tatemoto A, Sone Y, et al. Ureteral metastasis from appendiceal cancer: report of a case. *Surg Today* 2005; 35:168-71.
  2. Park IJ, Yu CS, Kim HC, Kim JC. Clinical features and prognostic factors in primary adenocarcinoma of the appendix. *Korean J Gastroenterol* 2004; 43: 29-34.
  3. Behera PK, Rath PK. Primary appendiceal Mucinous Adenocarcinoma. *Indian J Surg* 2009; 68: 12261-5.
  4. Zagrodnick DF 2nd, Rose DM. Mucinous cystadenoma of the appendix: diagnosis, surgical management, and follow-up. *Curr Surg* 2003; 60: 341-3.
  5. Sington JD, Warren BF, Manek S. Reduplication cyst of appendix with mucinous carcinoma and Müllerian metaplasia: a case report. *J Clin Pathol* 2002; 55: 551-3.
  6. Terada T. Non Invasive Adenocarcinoma of the Vermiform Appendix: Incidence and Report of Four Cases among 512 Appendectomies. *Gastroenterol Res* 2009; 2: 238-41.
  7. Petrou A, Papalambros A, Katsoulas N, Bramis K, Evagelou K, Felekouras E. Primary appendiceal mucinous adenocarcinoma alongside with situs inversus totalis: a unique clinical case. *World J Surg Oncol* 2010; 8: 49.
  8. Lee EY, Chung YD, Choi JS, Choi AN, Lee KW. A Case of Mucinous Adenocarcinoma of Appendix Metastasis to Ovary. *Korean J Obstet Gynaecol* 1997; 40: 1298-301.
  9. Topkan E, Polat Y, Karaoglu A. Primary mucinous adenocarcinoma of appendix treated with chemotherapy and radiotherapy: a case report. *Tumor* 2008; 94: 596-9.
  10. Sayles M, Courtney E, Younis F, O'Donovan M, Ibrahim A, Fearnhead NS. Appendiceal mucinous adenocarcinoma presenting as an enterocutaneous fistula in an incisional hernia. *BMJ Case Reports* 2010; doi:10.1136/bcr.11.2009.2472.
-