

## **Case Report**

### **Multiple major artery compression by an idiopathic aortic aneurysm: an unusual cause of hypertensive encephalopathy**

Shakeel Ahmed,<sup>1</sup> Syed Rehan Ali,<sup>2</sup> Husen Yousuf<sup>3</sup>

Department of Paediatrics and Child Health,<sup>1,2</sup> Department of Radiology,<sup>3</sup> The Aga Khan University Hospital, Karachi, Pakistan.

#### **Abstract**

Multiple major artery compression by an aortic aneurysm is extremely rare in the paediatric population. Most arterial aneurysms in children are secondary to infections mainly mycotic, connective tissue disorder, vasculitis, collagen vascular diseases, and other causes. True idiopathic aneurysms are the least common and a few reports in children have been published. We describe an 8 year old boy who presented with hypertensive encephalopathy and later was found to have an idiopathic, symptomatic suprarenal aortic aneurysm compressing multiple major arteries of the abdomen. The child was subsequently managed on multiple antihypertensive medication and later required engraftment of the renal and inferior mesenteric artery. The diagnostic workup, surgical treatment, and a review of the literature is described.

#### **Introduction**

Aortic aneurysm is an unusual clinical entity seen in children and Idiopathic Abdominal aortic aneurysm (AAA) has rarely been described.<sup>1</sup> Most of the few reported cases are mycotic, arising from septic complications following umbilical artery catheterization. Only few are idiopathic in origin.<sup>2</sup> Congenital aneurysms have been associated with the connective tissue disorders of Ehlers-Danlos and Marfan syndromes.<sup>3</sup>

We are reporting an 8 year old boy who presented with hypertensive encephalopathy and after extensive investigations was found to have suprarenal aortic aneurysm with the compression of the major abdominal vessels including the right renal artery.

#### **Case History**

An 8 year old boy presented to the emergency room

with generalized tonic clonic seizures of 5 minutes duration followed by drowsiness. There was a history of intermittent headache and vomiting for the last 6 weeks. There was no significant previous medical illness.

His initial examination revealed a drowsy child with Glasgow Coma Scale (GCS) of 9/15. The striking finding in his vitals was his blood pressure of 280/190 mmHg. (Above the 99th centile) He was immediately sedated, intubated and ventilated. Hydralazine and Labetolol infusions were started for the control of his blood pressures. His initial blood results including renal chemistry were normal. Urine microscopy did not reveal any proteinuria or RBC cast.

Ultrasound abdomen results showed normal kidneys with normal renal vasculature, with an incidental finding of abdominal aortic aneurysm originating from the suprarenal part.

The child subsequently improved and was extubated after 4 days. His blood pressure remained high in spite of multiple anti-hypertensive trials including nifedipine, doxazocin, clonidine, captopril and amlodipine. Further investigations including autoimmune profile, thyroid profile, urinary VMA and porphyrins were all within normal limits. Serum renin and aldosterone were high >19.90 ng/ml/hr (n=0.31-3.95 ng/ml/hr) and >120 ng/dl (n= 4-31 ng/dl) respectively. Doppler ultrasound abdomen revealed increased restrictive index on the right renal artery suggestive of stenosis. Abdominal CT scan with contrast revealed fusiform aneurysmal dilatation of proximal portion of the abdominal aorta 4.5x 2 cms, extending from the diaphragm to the renal hilum (Fig-1). Coronal and Sagittal reconstruction showed coeliac artery, superior mesenteric artery and both renal arteries arising from the aneurysmal portion (Fig-2A, 2B). MR angiogram was performed which confirmed the CT findings. (Fig-3).

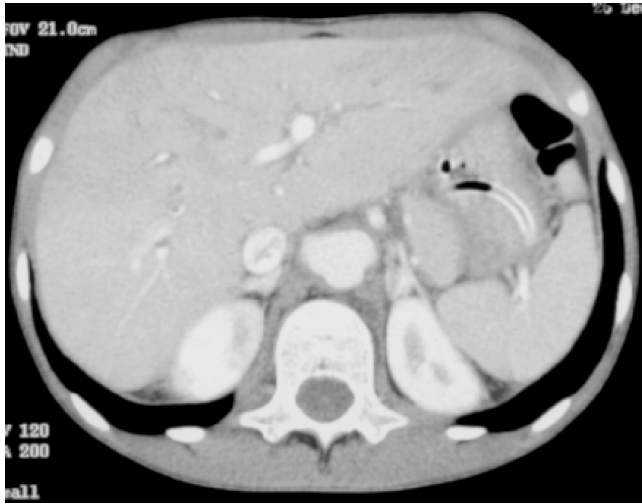


Fig-1: Contrast enhanced CT abdomen showing aneurysmal dilatation of aorta.

In consultation with interventional radiologist and cardiothoracic surgeons, endovascular intervention was performed for renal angiography/angioplasty. The

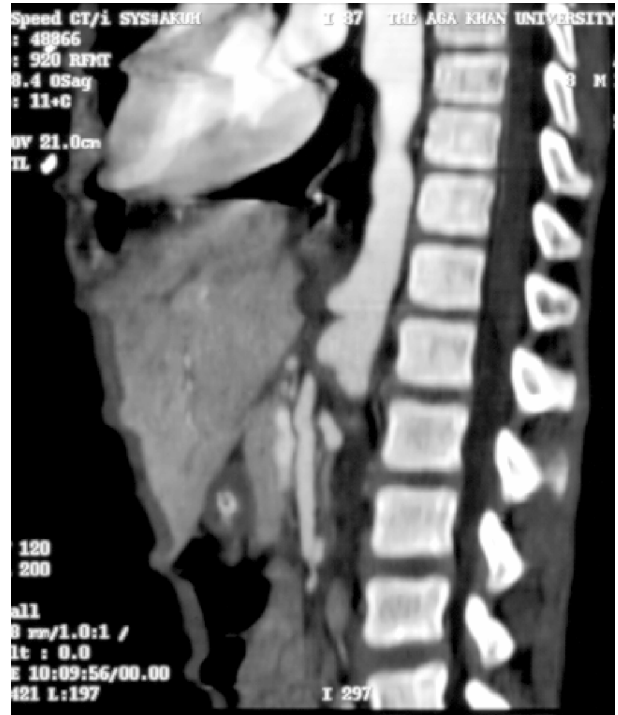

Fig-2B: Sagittal reconstruction view.

Reconstruction images above showing irregular aneurysmal dilatation of proximal part of abdominal aorta showing celiac artery, superior mesenteric artery and both renal arteries arising from the aneurysmal portion.

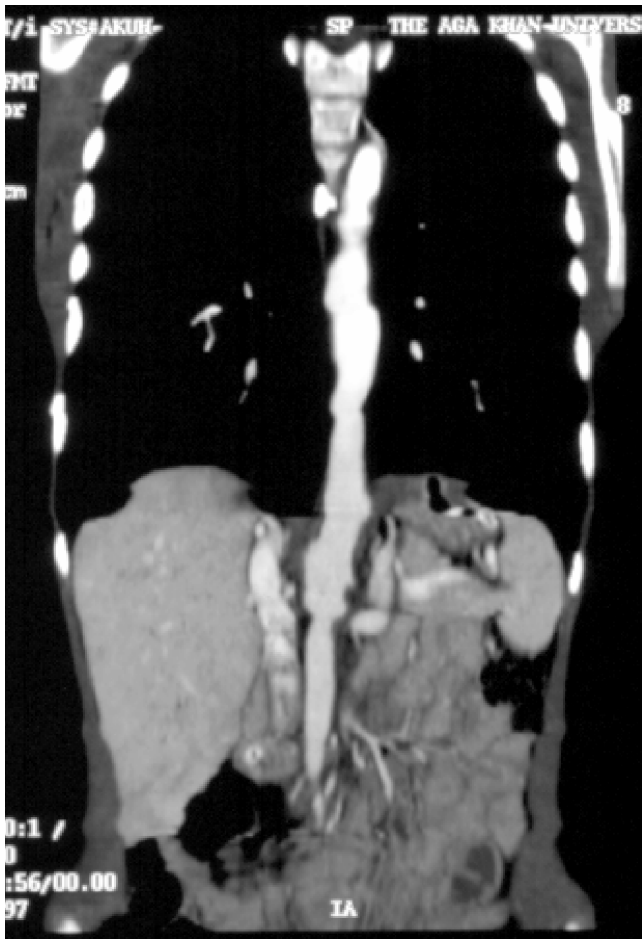

Fig-2A: Coronal reconstruction view.

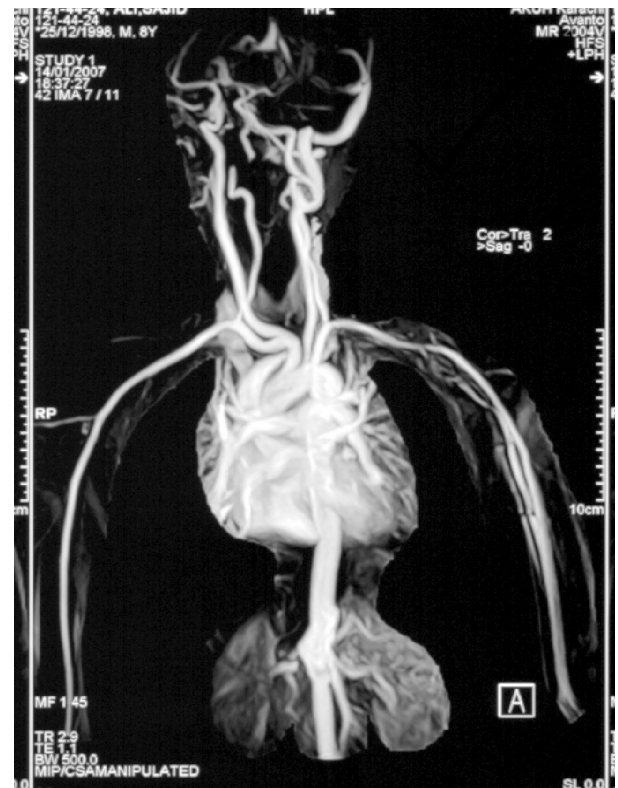


Fig-3: 3D MRA, showing aneurysm affecting origin of right renal artery with compression and displacement of celiac trunk and superior mesenteric artery.

compressed renal artery was found to be arising from the aneurysm. In view of a very high risk of aneurysmal leak, the procedure was abandoned.

Surgical and corrective intervention was performed at a later stage with engraftment of the renal artery and superior mesenteric artery taken from the inferior mesenteric artery as a bypass procedure.

The final outcome of the multiple major arteries compression and control of hypertension still rests on the successful reno-vascular engraftment.

### Discussion

Idiopathic Abdominal aortic aneurysm (AAA) is not commonly found in children.<sup>1</sup> In older age, aortic aneurysm might be secondary to atherosclerosis or syphilis. There are certain conditions that might externally compress the renal pedicle and lead to hypertension that include pheochromocytoma, para pelvic cyst, tumour or renal artery aneurysm.

Renal artery stenosis has been recognized as a potential cause of hypertension in any age group especially in the younger population. However, compression secondary to aortic aneurysm is very rare. Any lesion that compresses the renal artery and compromises the blood supply can produce hypertension. It is unlikely for an abdominal aortic aneurysm to extrinsically compress the main renal artery distal to its origin and produce renovascular hypertension.

To the best of our knowledge this the first case in the paediatric age group to present with hypertension of renovascular origin and have an aortic aneurysm with compression of the other major abdominal arteries. A case of a 53 years old woman with aneurysm of abdominal aorta compressing the right renal artery has been reported in 1982.<sup>4</sup>

Abdominal aortic aneurysms usually produce no symptoms, especially when the size of the aneurysm is small. As the aneurysm grows, there may be mild abdominal discomfort, back pain, or groin pain. Some

patients may feel a pulsatile (beating) mass in the abdomen. If the aneurysm ruptures, there is sudden, very severe abdominal or back pain. Immediate medical attention is critical for survival.<sup>5</sup>

Renal artery stenosis or compression due to an aneurysm can be asymptomatic until it is complicated with hypertension, as seen in our case. Imaging techniques including ultrasound, CT scan and angiography can diagnose an aneurysm. In our patient, an initial ultrasound detected the aortic aneurysm but compression of the renal and major abdominal arteries were obscured. This was later identified on magnetic resonance angiogram which demonstrated the large fusiform aneurysm.

Magnetic resonance angiography is the imaging modality that has replaced the traditional angiographic assessment of aneurysms. The study provides excellent anatomical definition and 3-dimensional assessment of the problem.

Diagnosis of AAA is largely made by Doppler US, CT angiography and /or MRA. Conventional angiography now mainly a therapeutic role.

Abdominal aortic aneurysms are typically repaired by operative intervention. New minimally invasive methodologies for the placement of endovascular stents being evaluated.<sup>6,7</sup>

### References

1. Khougeer G, al Garni S. Abdominal aortic aneurysm in an infant. *Ann Saudi Med* 1999; 19: 427-8.
2. Millar AJW, Gilbert RD, Brown R. Abdominal aortic aneurysms in children. *J Pediatr Surg* 1996; 31: 1624-8.
3. Verloes A, Sakalihan N, Koulischer L. Aneurysms of the abdominal aorta: familial and genetic aspects in three hundred thirteen pedigrees. *J Vasc Surg* 1995; 21: 646-55.
4. Lepke RA, John J, Pekani JJ. Renal artery compression by an aortic aneurysm, an unusual cause of hypertension. *Am J Roentgenol* 1982; 139: 812-3.
5. Bower TC, Cherry KJ Jr, Pairolo PC. Unusual manifestations of abdominal aortic aneurysms. *Surg Clin North Am* 1989; 69: 745-54.
6. Kiell CS, Ernst CB. Advances in management of abdominal aortic aneurysm. *Adv Surg* 1993; 26: 73-98.
7. Agroyannis B, Chatziioannou A, Mourikis D. Abdominal aortic aneurysm and renal artery stenosis: renal function and blood pressure before and after endovascular treatment. *J Human Hyperten* 2002; 16: 367-9.