

Premaxillary retraction in bilateral complete cleft lip and palate with custom made orthopaedic plate having anterior acrylic ring

Arsalah Raffat, Abida Ijaz

Orthodontic Department, The Children's Hospital & Institute of Child Health, Lahore.

Abstract

Objective: To determine retraction and alignment of protruded and rotated premaxillary segment and to measure increase in columellar length by using modified orthopaedic plate with anterior acrylic ring in newborn babies with non syndromic bilateral cleft lip and palate.

Methods: Pre surgical infant orthopaedic treatment of ten non syndromic bilateral cleft lip and palate new born babies was done. Modified orthopaedic plate with anterior acrylic ring was used. This was adjusted every week by adding increments of 1mm acrylic along the inner surface contacting labial surface of pre maxillary segment and trimming the same amount along the anterior margin of the plate.

Pre and post treatment dental cast and a 1:1 photocopy of dental cast was obtained to analyze the retraction, angulations and arch form. Data was compiled and analyzed in SPSS 10.

Results: A significant pre maxillary retraction, correction of rotation as well as increase of columellar length was achieved.

Conclusion: The appliance proved most successful being used immediately after birth, making use of plasticity of the neonate cartilage due to maternal estrogen levels. Moreover the appliance maintained arch form facilitated function and rendered initial lip repair easy and tension free (JPMA 59:376; 2009).

Introduction

Palatal closure begins on day 45 of intrauterine life in humans; growth of the palatal shelves causes their vertical extension on either side of the tongue. Guided by what appears to be both mechanical and morphogenetic forces, the palatal shelves elevate at a definite time and become horizontally positioned over the tongue. Continued directed growth causes the approximation of the horizontally occurring palatal shelves. Palatogenesis culminates when the shelves make contact, adhere and fuse along the midline, forming an epithelial seam that is later replaced by mesenchyme to form the definitive palate. The definitive palate fuses with the primary palate and the nasal septum in the anterior to middle regions and thus separates the oral and the nasal regions of the pharynx.¹

The cleft lip, cleft palate, or both is a congenital malformation with an overall prevalence rate of 2.0/1000 live births.² The birth prevalence of cleft lip and palate in Asian population was similar to published Caucasian rates. Seasonal variation would be observed consistent with possible environmental factors. Significant associations with maternal age, pregnancy age, and birth order warrant additional study of pregnancy history in Asian. Overall, Chinese and Japanese live birth prevalence rates for nonsyndromic cleft lip with or without cleft palate, based on the published reports of birth prevalence, were significantly lower than the oft-quoted rate of 2 per 1000 for Asians. The apparent reason for the discrepancy is that many published prevalence rates included all pregnancies (live births

plus pregnancy losses) and do not distinguish between syndromic and nonsyndromic clefts or between cleft palate alone and cleft lip with or without cleft palate.^{3,4}

Cleft lip and cleft palate are disfiguring and cause great psychological trauma to family and child.⁵ Patients face severe deformity and those with bilateral cleft have poor health as they suffer from repeated upper respiratory tract infection.⁶ For centuries, surgeons have recognized the challenges of the bilateral cleft deformity; the main obstacles to the lip repair being the protruding premaxilla and the deficient or absent columella making the nose tip flat.⁷ During the sixteenth, seventeenth and eighteenth centuries, the surgical treatment involved excision of the Pre maxilla followed by a surgical union of the prolabium to the lateral lip segments. At a later stage prosthetic replacement of the anterior dentition was recommended to improve facial appearance.⁸ Another surgical option for pre maxillary retraction included fracture of the vomer, resection of part of the vomer or nasal septum leading to long term clinical observation of growth arrest of adjacent bones, lingual inclination of incisors flat faces and nasal airway obstruction.⁹

In the 19th century, surgeons noted that excising the premaxilla deprived the lip of bony support, resulting in midface deficiency, maxillary constriction, dental malocclusion, and a relative mandibular prognathism. The focus turned to preservation and retraction of premaxilla to achieve optimal lip repair. Pre surgical nasal and alveolar molding includes as its objectives the active molding and repositioning of the nasal

cartilages and alveolar processes as well as lengthening of the deficient columella.¹⁰

The approach to pre surgical molding and retraction therapy took advantage of the plasticity of the cartilage in the newborn infant during the first 6 weeks after birth. In 1984 Matsuo¹¹ demonstrated that auricular cartilage could be molded with permanent results if treated within 6 weeks of life. During the perinatal period, maternal estrogen rises, this triggers an increase in hyaluronic acid. Hyaluronic acid reduces cartilage, ligament and connective tissue elasticity by breaking down the intercellular matrix. This function is critical for the safe passage of the foetus through the birth canal. After approximately 6 weeks, the levels of estrogen begin to fall off and the cartilage becomes less plastic. They later applied their findings to the cleft lip nasal deformity (1991)¹² and postulated that the high degree of plasticity and lack of elasticity in neonatal cartilage is due to high level of hyaluronic acid, a component of the proteoglycan intercellular matrix.

As the estrogen level increases the level of hyaluronic acid increases and the elasticity of the cartilage decreases with the neonatal levels of maternal estrogen highest immediately after birth, the period of plasticity is slowly lost during the first month of the postnatal life. It is during this first 2 to 3 months after birth when active soft tissue and cartilage molding plate therapy is most successful.¹³

Historically, there have been numerous attempts at nonsurgical reduction of the size of the alveolar cleft. The start of the era of modern presurgical orthopedic appliances is attributed to Mc Neil (1950). He utilized an intraoral acrylic appliance similar to an obturator to approximate the alveolar segments. McNeil was able to reduce both the size of the alveolar cleft gap and also the size of the hard palate cleft.¹⁴

Rosenstein and Jacobson (1967) described a technique using an acrylic obturator that engaged the undercut regions in the alveolar segments, which allowed passive molding of the segments as growth developed.¹⁵ Latham (1980)¹⁶ described a pin-retained appliance that could rapidly close a unilateral cleft while advancing the lesser alveolar segment. Latham developed a similar pin retained appliance that retracted the premaxilla in the bilateral cleft infant. Presurgical mechanical retraction of the protruding premaxilla using pinned palatal appliances was adopted. In conservatively treated cases, a head bonnet with external elastic was sometimes used before surgical lip closure to ventroflex the premaxilla thereby reducing tension at the surgical sites.¹⁷

(Papay 1994)¹⁸ made use of surgical placement of micro plate in tunneled preparation across premaxilla and used elastic chain to retract the micro plate while the prosthesis was retained with pin retained screw inserted in palatal shelves.

Figueroa 1996 used elastic chain with acrylic to retract the premaxilla.¹⁹

Ross and McNamara (1994)²⁰ described one possible benefit of presurgical infant orthopedics: if the maxillary segments are repositioned so that the lip segments are in closer apposition, then the lip surgery should be easier, enabling a more precise repair with less tension. If surgery is thereby improved, then there is a powerful incentive to adopt presurgical infant orthopedic procedures.

Multiple modifications by these authors and others have led to continued refinements with prepractical applications of these methods to provide a predictable result in premaxillary and palatal movements.¹⁰ With respect to the palatal transverse growth occurring mostly within the first 2 years, valid data indicates no adverse effect of early hard palatal closure on the maxillary width in patients with Bilateral Cleft Lip and Palate when performed prior to 1 year of age and orthopedic treatment is continued until the stage of soft palate closure. Therefore, speech rehabilitation and positive psychological effects should be the determinant in treating patients with cleft lip and palate.²¹ This article deals with custom made modified orthopedic plates designed by Ijaz A⁹ the device on insertion surrounded the protruded premaxilla and exerts retraction force utilizing muscle activity.

Patients and Methods

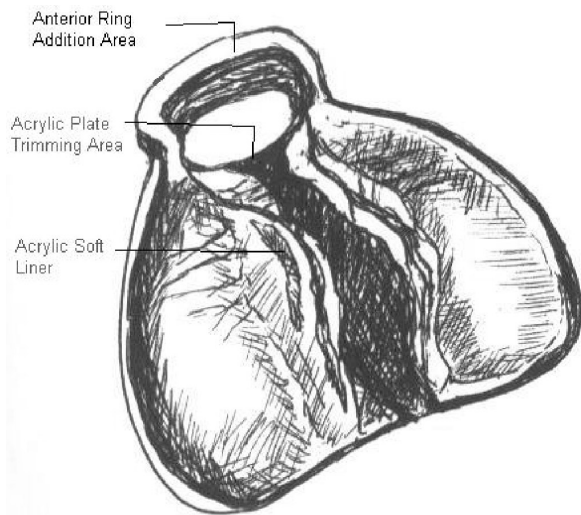
A Quasi experimental, intervention type of study was conducted at Orthodontic Department of Children Hospital and Institute of Child Health Lahore Pakistan. Only the Nonsyndromic babies with complete bilateral cleft lip and palate, one week of age were selected, through non-probability purposive sample.

Appliance Design:

Orthopaedic plate with anterior acrylic ring was fabricated for individual cases. Special tray was prepared from self-cure acrylic to record impression in rubber base material. Cast was poured in stone plaster. The defect part was boxed in wax and orthopedic plate was made from selfcure acrylic, using pressure pot. Acrylic ring around the pre maxillary alveolar segment was then fabricated and the plate was finished and polished for the next chair side procedure.

The appliance was tried in the baby's mouth for adaptation and the cleft part was then filled with soft acrylic for retention purpose also acting as an obturator. (Figure 1) The parents were demonstrated to use the appliance as full time wear in baby's mouth and instructions were given for thorough cleansing of the plate after every feed, followed by antifungal drops to be administered over the top surface. As the child is fed on milk, fungal infection is common in cleft babies.

A regular weekly follow up for adjustment of the anterior acrylic ring was scheduled. Adjustment was done by adding Imm of selfcure acrylic along the ventral surface of the anterior acrylic ring contacting the labial surface of the premaxillary



Pre Surgical Infant Orthopaedic Plate With Anterior Acrylic Ring

Figure 1: Orthopedic Plate.

segment and removing a little more along the anterior margin of the plate to accommodate distalizing premaxilla. Treatment duration with this appliance was about 3 months.

Data Collection:

The pre and post treatment cast records were photocopied at ratio (1:1) after identifying and marking the landmarks. (Fig: 2) To prevent human error, readings were repeated and mean difference was taken to prevent bias.

Linear and angular measurements were then taken on the photocopies.

1- Position of premaxilla in reference to inter canine line (I-CC').

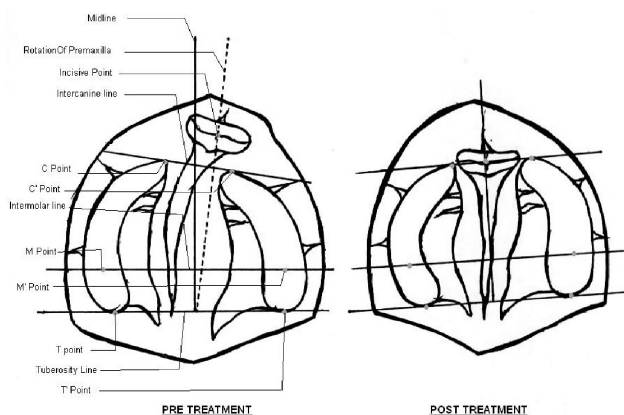


Figure 2: Photographic representation of landmarks of pre and post treatment model casts.

2- Derotation of the premaxillary segment in degrees with reference to mid Sagittal plane (<).

3- Inter canine width (C-C').

4- Intermolar width (M-M').

5- Anterior-posterior length of palate with reference to tuberosity plane (A-P).

6- For columellar length, measurements were performed with the help of soft vinyl scale on the baby's faces i.e. assessment of change in columellar length (Col) from tip of the nose to phylltrum (upper margin).

Results

Results concerning presurgical orthopaedics treatment technique were tabulated in SPSS v 10 and are presented in Table.

Table: Mean and Standard deviation of variables significance is considered as P< 0.005.

		Paired Differences					t	df	Sig (2-tailed)
		Mean	Std. Deviation	Std. Error Mean	95% Confidence Interval of the Difference				
					Lower	Upper			
Pair 1	inter canine distance pre - inter canine distance post	-.6390	.4075	.1289	-.9305	-.3475	-4.958	9	.001
Pair 2	inter molar distance pre - inter molar distance post	-.8580	.7528	.2380	-1.1944	-.1178	-2.758	9	.022
Pair 3	tuberosity to inter canine distance pre - tuberosity to inter canine distance post	-1.3830	.9663	.3056	-2.0742	-.6918	-4.526	9	.001
Pair 4	rotation of premaxilla pre - rotation of premaxilla post	5.7000	3.9172	1.2387	2.8978	8.5022	4.801	9	.001
Pair 5	retraction of premaxilla pre - retraction of premaxilla post	5.3030	2.2493	.7113	3.6939	6.9121	7.455	9	.000
Pair 6	columellar length pre - columellar length post	-4.6000	.6992	.2211	-5.1002	-4.0998	-20.804	9	.000

There was average 5.3 mm retraction of pre maxilla i.e. the distance of mid premaxillary point to intercanine line (I-CC'). The deviation of premaxilla to midsagittal plane reduced to 5.7 degrees on average. The mean for the transverse maxillary arch dimensions (C-C' and M-M') were -0.63 and -0.65 respectively where there is stability due to orthopaedic plate and that shows prevention of further collapse of arch form. The overall anteroposterior length of maxillary arch (intertuberosity line to anterior limit of maxilla in midline) showed a difference of -1.3 mm and average -4.6 mm increase in columellar length.

Discussion

The idea behind this appliance design with acrylic ring surrounding the pre maxillary segment was to provide active molding of the pre maxilla taking advantage of the plasticity of the neonatal cartilage which in turn was due to maternal estrogen levels. The most famously used methods comprise conventional orthopaedic plates like Latham,¹⁶ Papay¹⁸ and Grayson.¹⁰ Presurgical nasoalveolar molding therapy has shown significant advantages in the treatment of bilateral cleft lip and palate patients. It improves the nasal asymmetry and deficient nasal tip projection associated with bilateral cleft lip and palate. It also forces the protruded premaxillary segment into alignment with the dental alveolar segments, improving the shape of the maxillary arch. Various recent studies have given similar results.^{22,23} Continuous use of the orthopaedic plate up to the time of palatoplasty appeared to be effective for the postoperative articulatory function in children with complete cleft lip and palate. Inhibiting irregular movements of the tongue, the orthopaedic plate might assist in preventing "palatalized articulation."²⁴ Strategy behind this modification with acrylic ring was to get rid of extra oral attachments for retention or retraction purpose, in order to reduce the parental compliance (adhesive tape, face bow and head cap etc), moreover to prevent the new born's soft tissue from surgical interventions like placement of micro screws and retention pins. This appliance even maintained arch form during buccinator's activity, and prevented further collapse of lateral alveolar arches as described by the results of study. The change in the device is an acrylic ring, extending anteriorly from the plate around pre maxillary segment and makes it to be a true functional device as the child suckles; muscle forces from the tongue are transformed on to the appliance in the form of retraction force to pre maxilla. The cleft area of plate was given a bridge of soft acrylic that not only provided retention but also partially served the purpose of nasal stents (extending up in the nostrils) as used in Grayson's²⁵ appliance. As the pre maxilla distalized, columella moved down and showed an increase in length of 4.6mm on average. Increase in length of the columellar tissue has been facilitated by the soft acrylic holding the nasal structures thus prevented surgical lengthening of the columella

and therefore avoided scar at the base of the nose. The appliance was entirely independent of extra oral forces. When the pre surgical phase of treatment is coordinated with the primary surgical repair this device has contributed to esthetic outcome of labial repair and minimized extent of the complexity of subsequent revision surgeries by decreasing their number.

Conclusion

The modified pre surgical infant orthopaedic plate comprising of anterior acrylic ring was used in babies presenting with complete bilateral cleft of the lip and palate for a period of 3 months. Successful results were obtained with this device. On the basis of these results, following conclusions may be drawn.

The appliance being myo-functional in action was comfortable and easy to use. It produced significant retraction of the pre maxillary segment without the use of extra oral forces. It rendered initial lip repair easy, more precise and tension free. It caused columellar elongation without additional scarring. It facilitated feeding. The appliance being self-retentive maintained arch form and inter arch relationship. Maxillary growth was facilitated with the use of this appliance.

References

1. Brown NL, Knott L, Halligan E, Yarram SJ, Mansell JP, Sandy JR. Microarray analysis of murine palatogenesis: temporal expression of genes during normal palate development. *Dev Growth Differ* 2003; 45: 153-65.
2. Hagberg C, Larson O, Milerad J. Incidence of cleft lip and palate and risk of additional malformations. *Cleft Palate Craniofac J* 1998; 35: 40-5.
3. Cooper ME, Stone RA, Liu Y, Hu DN, Melnick M, Marazita ML. Descriptive epidemiology of nonsyndromic cleft lip with or without cleft palate in Shanghai, China, from 1980 to 1989. *Cleft Palate-Craniofac J* 2000; 37: 274-80.
4. Cooper ME, Ratay JS, Marazita ML. Asian oral-facial cleft birth prevalence. *Cleft Palate-Craniofac J* 2006; 43: 580-9.
5. Barden RC, Ford ME, Wilhelm WM, Rogers-Salyer M, Salyer KE. Emotional and behavioral reactions to facially deformed patients before and after craniofacial surgery. *Plast Reconstr Surg* 1988; 82: 409-18.
6. Abbasi A. An experience of congenital unilateral cleft lip repair. *Pak J Surg* 1998; 14: 86-8.
7. Millard DR. *Cleft Craft*. 2nd Vol. Boston: Little Brown; 1977.
8. Asher McDade C, Shaw WC. Current cleft lip and palate management in the United Kingdom. *Br J Plast Surg* 1990; 43:318-21.
9. Ijaz A. Management of complete bilateral cleft of the lip and palate with modified pre Surgical infant Orthodontic plate. *Pak Oral Dent J* 2003; 23:131-6.
10. Grayson BH, Cutting CB, Wood R. Preoperative columella lengthening in bilateral cleft lip and palate. *Plast Reconstr Surg* 1993; 92: 1422-3.
11. Matsuo K, Hirose T, Tomono T, Iwasawa M, Katohda S, Takahashi N, et al. Nonsurgical correction of congenital auricular deformities in the early neonate: a preliminary report. *Plast Reconstr Surg* 1984; 73:38-51.
12. Matsuo K, Hirose T. Preoperative nonsurgical over correction of cleft lip nasal deformity. *Br J Plast Surg* 1991; 44:5-11.
13. Hardingham TE, Muir H. The specific interaction of hyaluronic acid with cartilage proteoglycans. *Biochem Biophys Acta* 1972; 279: 401-5.
14. McNeil CK. Orthodontic procedures in the treatment of congenital cleft palate. *Dent Rec* 1950; 70:126-32.
15. Rosenstein SW, Jacobson BN. Early maxillary orthopedics: a sequence of events. *Cleft Palate J* 1967; 4: 197-204.
16. Latham RA. Orthodontic advancement of the cleft maxillary segment: a preliminary report. *Cleft Palate J* 1980; 17: 227-33.
17. Berkowitz S. A comparison of treatment results in complete bilateral cleft lip and

- palate using a conservative approach versus Millard-Latham PSOT procedure. *Semin Orthod* 1996; 2:169-84.
18. Papay FA, Morales LJr, Motoki DS, Yamashiro DK. Presurgical orthopedic premaxillary alignment in cleft lip and palate reconstruction. *Cleft Palate Craniofac J* 1994; 31:494-7.
 19. Figueroa AA, Reisberg DJ, Polley JW, Cohen M. Intraoral appliance modification to retract the premaxilla in patients with bilateral cleft lip. *Cleft palate Craniofac J* 1996; 33:497-500.
 20. Ross RB, McNamara MC. Effect of presurgical infant orthopedics on facial esthetics in complete bilateral cleft lip and palate. *Cleft Palate Craniofac J* 1994; 31: 68-73.
 21. Lehner B, Wiltfang J, Strobel Schwarthoff K, Benz M, Hirschfelder U, Neukam FW. Influence of early hard palate closure in unilateral and bilateral cleft lip and palate on maxillary transverse growth during the first four years of age. *Cleft Palate Craniofac J* 2003; 40:126-30.
 22. Spengler AL, Chavarria C, Teichgraeber JF, Gateno J, Xia JJ. Presurgical nasolabial molding therapy for the treatment of bilateral cleft lip and palate: A preliminary study *Cleft Palate Craniofac J* 2006; 43:321-8.
 23. Oosterkamp BC, van Oort RP, Dijkstra PU, Stellingsma K, Bierman MW, de Bont LG. Effect of an intraoral retrusion plate on maxillary arch dimensions in complete bilateral cleft lip and palate patients. *Cleft Palate Craniofac J* 2005; 42:239-44.
 24. Suzuki K, Yamazaki Y, Sezaki K, Nakakita N. The effect of preoperative use of an orthopedic plate on articulatory function in children with cleft lip and palate. *Cleft Palate Craniofac J* 2006; 43: 406-14.
 25. Grayson BH, Santiago PE. Presurgical orthopedics for cleft lip and palate. In: Aston SJ, Beasley RW, Thorne CHM, eds. *Grabb and Smith's Plastic Surgery*. 5th ed. Philadelphia: Lippincott-Raven 1997; pp 237-44.
-