

Doptaus — A simple criterion for improving Sonographic Diagnosis of Acute Appendicitis

Saba Sohail, Kausar Jehan Siddiqui

Radiology Department, Dow University of Health Sciences and Civil Hospital, Karachi.

Abstract

Objective: To determine the efficacy of 'Detection Of Pin-point Tenderness on the Appendix on abdominal UltraSound' (DOPTAUS) for improving sonographic diagnosis by junior and senior ultrasound operators.

Methods: An analytical study was done at the Radiology Department, Dow University of Health Sciences and Civil Hospital Karachi from March 2005 to December 2006. Adult patients of either gender with clinically suspected acute appendicitis referred to the department during regular working hours and later operated in the same hospital were included. Each patient was scanned by a junior and a senior ultrasound operator using the conventional criteria first and later focused ultrasound of the point of maximal tenderness (DOPTAUS). Diagnosis was compared against surgical findings for accuracy determination. Percentage agreement between the operator groups was evaluated by kappa (k) statistics.

Results: Out of the referred 100 patients (58 males, 42 females, mean age 32.6 ± 7.8 years), appendicitis was diagnosed using conventional criteria by juniors in 48 and by seniors in 74 patients ($k=0.4$, sensitivity=56.74%, specificity 53.3%). Using DOPTAUS acute appendicitis was diagnosed in 69 by juniors and 85 by seniors ($k=0.69$, sensitivity=90.4%, specificity=83.33%). On surgery, 94 cases were found to have acute appendicitis.

Conclusion: In this series, focused ultrasound after detecting maximal pin-point tenderness resulted in improved diagnosis of acute appendicitis in clinically suspected cases. Moreover, the percentage agreement between the operator groups increased from intermediate to good with improved accuracy. This shows that less experienced operators can improve their diagnostic accuracy of acute appendicitis using focal pin-point tenderness as the guide (JPMA 59:79; 2009).

Introduction

Acute appendicitis is a common surgical emergency but its pre-operative diagnosis often imposes difficulty due to its mimicking other inflammatory, vascular, calculous and obstetric conditions.¹ A number of preoperative diagnostic measures have been applied to improve the diagnostic accuracy and reduce the rate of negative appendicectomies. Clinical judgment remains the most important diagnostic tool.² However, it is the clinically ambiguous case that requires the use of other ancillary techniques. To improve accuracy, a 10-point scoring system (Alvarado score) was introduced based on clinical symptoms, sign and laboratory findings.³ Later studies found it beneficial for surgeons with limited experience only.⁴ It has also been considered a means for selecting patients who should undergo imaging.⁵

The imaging methods used to compliment the diagnosis of acute appendicitis include primarily the ultrasound, computerized tomography and MRI.⁶⁻⁹ Traditionally, barium enema is not very helpful. It requires bowel preparation, purgation and shows indirect signs only.¹⁰ CT scan has a reported accuracy of 87-99%.¹¹ MRI is also reported to have high diagnostic accuracy.¹² However these investigations incur additional cost and are not as freely available as ultrasound.¹³

Ultrasound in acute appendicitis has an accuracy of 94-

96%.⁵ The conventional criteria are identification of a non-compressible bowel loop in right iliac fossa with thickened walls that may show an intra-luminal calculus or peri-appendiceal fluid or collection¹⁴ (Figures I and II). Inexperienced operators can not fully elicit its potential.¹⁵ Combining a simple maneuver of clinical skill and ultrasound expertise, a new criterion was developed as 'Detection Of Pin point Tenderness on the Appendix under UltraSonography' and was given the acronym DOPTAUS.¹⁶ The main difference here

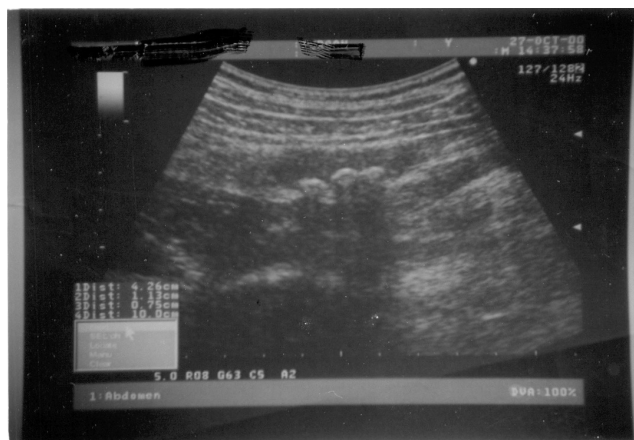

Figure I: An inflamed appendix showing multiple appendicoliths.

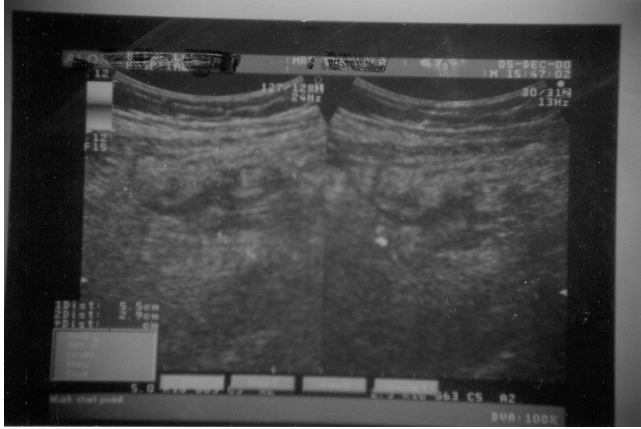


Figure II: Ultrasound appearance of an inflamed appendix.

is that the point of maximum tenderness is identified by the patient and a focused ultrasound of that particular spot is done instead of concentrating on the right iliac fossa or doing a whole abdomen scan.

Using this simple innovation, this study was planned to determine the improvement in the ultrasound diagnosis of acute appendicitis among senior as well as junior radiologists and residents at the radiology department of a public sector hospital.

Patients and Methods

The study was conducted at the department of radiology, Dow University of Health Sciences and Civil Hospital, Karachi from March 2005 to December 2006.

The inclusion criteria for the patients were adults of either gender referred to the department through emergency with suspected acute appendicitis for diagnostic ultrasound of abdomen or right iliac fossa. All of the cases were referred during regular working hours. Patients with palpable lump, chronic or repeated episodes of pain and those scanned in emergency after regular working hours and operated without or re-scan by seniors were excluded. Those patients whose follow up was not available, were also excluded.

All the included subjects were scanned on Toshiba Nemio with 3.5- 5 MHz probe first by a junior and then by senior operators. The former were defined for the purpose of study as third or fourth year radiology residents or medical officers with postgraduate qualification and experience of two years or less. The non-qualified medical officers not enrolled in a training program and the residents in first two years of training were not considered. Senior operators were defined as faculty members or medical officers with post-graduate qualification in radiology and post-qualification experience of more than two years. Ultrasound was performed first using conventional ultrasound criteria¹⁴ and then focused scan after the patient pin-pointed the site of maximum tenderness as reported by Soda et al.^{11,16} The findings were recorded by an independent observer.

Final report was issued based on the seniors' findings.

Patients were followed till their operation and surgical findings were taken as the gold standard for accuracy determination i.e. sensitivity, specificity and predictive values. Kappa (K) statistics were applied for comparison between the operator groups to determine agreement. K value of 0.8 was taken as excellent, 0.4-0.79 as intermediate to good, and less than 0.4-0 as poor to no agreement.

Results

A total of 100 patients were included in the study in compliance with the criteria. There were two senior and four junior operators. The mean post-qualification experience of the senior operators was 4.8 ± 2.1 years at the start of study. The junior operators had a mean experience of 1.6 ± 0.7 years.

Among the patients there were 42 females and 58 males with age ranging from 17 to 54 years, mean 32.6 ± 7.8 years. Acute appendicitis was diagnosed sonographically in 85 patients. All the 100 patients were operated due to clinical suspicion. Among those, 94 had acute appendicitis on surgery while appendix was normal in 06 patients giving a negative appendectomy rate of 6% for this cohort. The causes of missed ultrasound diagnosis in the 09 patients were retro-caecal location of appendix in 02 cases and surrounding bowel gases obscuring the right iliac fossa/point of maximum tenderness in seven patients.

The junior operators had correctly diagnosed without pin-pointing in 48 out of 85 and with pin-pointing in 69 cases. The seniors had diagnosed 74 out of 85 in the former and all 85 in the latter condition.

The percentage agreement between the groups was 48% ($k=0.48$) using conventional criteria and 69% ($k=0.69$) using DOPTAUS criteria. The over all accuracy values are stated in Table.

Table: Differences in appendicitis diagnosis using conventional and focused ultrasound with pin-point tenderness.

	Using conventional criteria	Using DOPTAUS (focused on pi-point tenderness)
Diagnosed by juniors	48	69
Diagnosed by seniors	74	85
Sensitivity	56.47%	90.4%
Specificity	53.3%	83.33%
Positive predictive value (PPV)	82.27%	98.8%
Negative predictive value (NPV)	17.77%	35.7%
Percentage agreement between observations	48%	69%
k-value	0.48	0.69

Discussion

Clinical diagnosis remains the mainstay of diagnosing

acute appendicitis. Imaging is required for atypical symptoms and signs, extremes of age (children and the elderly), and young females.¹⁷ Those with typical findings usually undergo immediate surgery without radiological evaluation.¹⁸

Accuracy of ultrasound is hailed as high but it is markedly affected by the operators' experience and expertise. The inexperienced may completely miss the signs particularly when the patient is obese or bowel gases are hindering visualization of what lies beneath. In the hands of the inexperienced, ultrasound loses its benefits and is used as stethoscope evaluation for abdominal viscera. This is particularly true with the unchecked short ultrasound training courses in the country and the surge in the number of 'sonologists' without an adequate, structured training and certification by an examining body.

To overcome this problem regarding the diagnosis of a common surgical emergency in the less experienced hands, a simple technique of DOPTAUS developed by Soda et al.¹⁶ was used in this study to determine the changes brought in diagnosis by combining clinical and conventional sonographic criteria.¹⁶ The over all sensitivity of ultrasound was 90% and the specificity was 83.3%. The western figures are 94-96%.¹⁴ The local figures are quoted as 88.8% sensitivity and 91.8% specificity by Qureshi et al¹⁹ and 86.2% sensitivity and 91.8% specificity by Khan et al.¹

The patient gender also affects the accuracy. Chen et al found the diagnostic accuracy as 78-92% in males and 58-85% in females.²⁰ On the other hand, a surgical audit by Bhopal et al²² reported that only 7.7% of their male patients required ultrasound for the diagnosis. The ultrasound diagnosis was correct in 81.2% and incorrect in the remaining subjects. In female patients, it was required in as many as 42.5% and out of those 30% who had an inflamed appendix was reported as normal on ultrasound.²¹ This effect was not observed in our study where the gender distribution was nearly even. However the patient's gender appears to be a confounding factor that may add to the fallacy of ultrasound diagnosis.

The practice of focused ultrasound under maximum pin-point tenderness improved the diagnosis of acute appendicitis from 74 to 85% for the seniors and from 48 to 69% for the junior operators. The improvement in juniors was more marked as proved by better observer agreement. Hence the technique turned out to be a simple innovation with greatly improved results. The developers of DOPTAUS technique had conducted a prospective study at a 100-bedded community hospital without a helical CT, MRI or a radiology specialist, circumstances much comparable to the local scenario in secondary or community level hospitals. They found a sensitivity of 86.7%, specificity of 89.7%, PPV of 94.5% and an over all accuracy of 87.6% using the DOPTAUS technique.¹⁶

Radiological evaluation has a potent role to perform in

the management of acute appendicitis. It reduces misdiagnoses and negative appendicectomies besides helping in treating peri-appendiceal abscess and post-operative complications.²² Utilizing ultrasound and helical CT for acute appendicitis diagnosis reduces hospital stay by reducing delay in diagnosis.²³ However, indeterminate and incorrect reports adversely affect patient management decisions. Hence the combination of clinical and ultrasound criteria in DOPTAUS have the potential to lead to shorter hospital stay, early diagnosis and surgery, and fewer unnecessary laparotomies.²⁴

Conclusion

Focused ultrasound after detecting maximal pin-point tenderness resulted in improved diagnosis of acute appendicitis in clinically suspected cases. Moreover, the percentage agreement between the operator groups increased from intermediate to good with improved accuracy. This shows that by using focal pin-point tenderness as the guide, less experienced operators can improve their diagnostic accuracy of acute appendicitis.

References

1. Khan JS, Hassan H, Khan JA. Investigations for Acute Appendicitis: Can we rely on them? *Pak J Surg* 2002; 18: 27-30.
2. Khalid K, Ahmad N, Farooq O, Anjum I, Sial GA. Acute appendicitis- laboratory dependence can be misleading: audit of 211 cases. *J Coll Physicians and Surg Pak* 2001; 11: 434-7.
3. Alvarado A. A practical score for the early diagnosis of acute appendicitis. *Ann Emerg Med* 1986; 15: 557-64.
4. Pruekprasert P, Maipang T, Geater A et al. Accuracy in diagnosis of acute appendicitis by comparing serum C-reactive protein measurements, Alvarado score and clinical impression of surgeons. *J Med Assoc Thai* 2004; 87: 296-303.
5. Stephens PL, Mazucco JJ. Comparison of ultrasound and the Alvarado score for the diagnosis of acute appendicitis. *Conn Med* 1999; 63: 137-40.
6. Teo EL, Tan KP, Lam SL, Ong CL, Wong CS. Ultrasonography and computed tomography in a clinical algorithm for the evaluation of suspected acute appendicitis in children. *Singapore Med J* 2000; 41: 387-92.
7. Frank C, Bohner H, Yang Q, Ohmann C, Roher HP. Ultrasonography for diagnosis of acute appendicitis: results of a prospective multicentre trial. *Acute Abdominal Pain Study Group. World J Surg* 1999; 23: 141-6.
8. Wise SW, Labuski MR, Kasales CJ, Blebea JS, Meilstrup JW, Hollay GP, et al. Comparative assessment of CT and sonographic techniques for appendiceal imaging. *Am J Roentgenol* 2001; 176: 933-41.
9. Hormann M, Paya K, Eibenberger K, Dorffner R, Lang S, Kreuzer S, et al. MR imaging in children with non-perforated acute appendicitis: value of unenhanced MR imaging in sonographically selected cases. *Am J Roentgenol* 1998; 171: 467-70.
10. Gelfand DW. What is the role of barium enema in the patient with suspected appendicitis? *Am J Roentgenol* 1995; 164: 762-3.
11. Garcia- Aguayo FJ, Gil P. Sonography in acute appendicitis: diagnostic utility and influence upon management and outcome. *Eur Radiol* 2000; 10: 1886-93.
12. Gwynn LK. The diagnosis of acute appendicitis: clinical assessment versus computed tomography evaluation. *J Emerg Med* 2001; 21: 119-23.
13. Ali Z, Hussain Z, Afzal Z. negative appendicectomy; its prevalence an experience. *The Professional* 2005; 12: 218-22.
14. Field S, Morrison I. The acute abdomen. In: *Textbook of radiology and imaging*. 7th ed. London: Churchill Livingstone; 2003; 683-4.
15. Zeilke A, Sitter H, Rampp T, Bohrer T, Rothmund M. Clinical decision-making, ultrasonography and scores for evaluation of suspected acute appendicitis. *World J Surg* 2001; 25: 578-84.
16. Soda K, Nemoto K, Yoshizawa S, Hibiki T, Shizuya K, Kanishi F. Detection of

pinpoint tenderness on the appendix under ultrasonography is useful to confirm acute appendicitis. *Arch Surg* 2001; 136: 1136-40.

17. Rosengren D, Brown AF, Chu K. Radiological imaging to improve the emergency department diagnosis of acute appendicitis. *Emerg Med Australas* 2004; 16: 410-6.
18. Abou-nukta F, Bakhos C, Arroyo K, Koo Y, Martin J, Reinhold R, et al. Effects of delaying appendectomy for acute appendicitis for 12 to 24 hours. *Arch Surg* 2006; 141: 504-6.
19. Qureshi IA, Tarin BA, Shafiq M. Role of Ultrasonography in clinically suspected cases of Acute Appendicitis. *Pak Armed Forces Med J* 2001; 51: 90-3.
20. Chen C, Botelho C, Cooper A. Current practice patterns in treatment of perforative

appendicitis in children. *J Am Coll Surg* 2003; 196: 212-21.

21. Bhopal FG, Khan JS, Iqbal M. Surgical audit of acute appendicitis. *J Coll Physicians and Surg Pak* 1999; 9: 223-6.
22. Chiba N. Motion-Screening and surveillance of Barrett's epithelium is practical and cost effective: arguments against the motion. *Can J Gastroenterol* 2002; 16: 541-5.
23. Todd J, Armon C, Griggs A, Porle S, Berman S. Increased rates of morbidity, mortality and charges for hospitalized children with public or no health insurance as compared with children with private insurance in Colorado and the United States. *Pediatrics* 2006; 118: 577-85.
24. Fa EM, Cronan JJ. Compression ultrasonography as an aid in the differential diagnosis of appendicitis. *Surg Gynecol Obstet* 1989; 169: 290-8.