Rare tumour of the thoracic wall: Elastofibroma

Filiz Eren[1], Tarik Candan[1], Bülent Eren[2], Ovgii Aydin[3], Nil Çomunoglu[4], Cem Çomunoglu[5]

Pathology and Cardiothoracic Surgery Department, Sevket Yilmaz Public Hospital, Bursa, Turkey[1], Uludag University Medical Faculty, Forensic Medicine Department, Council of Forensic Medicine of Turkey Bursa Morgue Department, 16059, Bursa, Turkey[2], Istanbul University Cerrahpasa Medical Faculty, Pathology Department, Cerrahpasa 34300, Istanbul, Turkey[3], Yeditepe University School of Medicine, Department of Pathology[4], Department of Pathology, Turk Cancer Institute, Istanbul, Turkey[5]

Abstract

Soft tissue tumours of the thoracic wall are a rare entity. Elastofibroma which occurs mainly in women, is commonly localized in the subscapular region, and is characterized by slow growth. We report the case of a 64-year-old woman who presented with a soft tissue tumour located in the right pectoral region, anterior chest wall. Magnetic resonance imaging showed a tumour on the right anterolateral thoracic wall that measured 5x4x5 cm with contrast enhancement. The findings were suggestive of partial infiltration of pectoral and intercostal muscles and were suspicious of a malignant tumour. The patient underwent complete resection of the tumour at a district hospital. The tumour was resected with clear surgical margins and minimum defect of the pectoral muscles. The specimen measured 4x4x3 cm and histopathology showed a lesion composed of fibrotic connective tissue of low cellularity with strongly eosinophilic, partially swollen, and plump fibers. Histology from the specimen was consistent with elastofibroma.

Introduction

Soft tissue tumours of the thoracic wall are a rare entity.[1] It is often difficult to identify the characteristics of soft-tissue tumours of the chest wall[2,3] Elastofibroma which occurs mainly in women, commonly in the subscapular region, and is characterized by slow growth is an important differential diagnosis for these tumours.[1,2] Abnormal degeneration of elastic fibers after repetitive local trauma as well as neoplastic mechanisms are being considered, but the pathogenesis still remains unclear.[1,4] We present a case of a 64-year-old woman who presented with a soft tissue tumour located in the right pectoral region, where histology from the specimen was consistent with elastofibroma.

Case Report

A 64-year-old woman presented with a 8-month history of swelling between right axilla and right breast, which had moderately increased in size during this period. There was no history of trauma or malignancy, and there was no significant past medical history, but patient complained of increasing pain and resistance to movement on lifting the right arm. On physical examination a nontender swelling was palpable located in the right pectoral region. All routine laboratory investigations were within normal range. The magnetic resonance image showed a homogeneous tumour of the thoracic wall with contrast enhancement located medially to the right anterior chest wall that measured 5x4x5 cm in size, also there were features of local infiltration suggestive of malignancy. In view of the magnetic resonance image findings, complete resection was performed. During the dissection, the tumour extended and was fixed to the thoracic wall and seemed to have infiltrated the surrounding soft tissue. The tumour was resected with clear surgical margins and minimum defect in

the pectoralis majus. muscles. The specimen measured 4x4x3 cm and histopathology (hematoxylin-eosin staining) showed a lesion composed of fibrotic connective tissue of low cellularity with strongly eosinophilic, partially swollen, and plump fibers intermingled with islets of mature fat tissue consistent with elastofibroma dorsi (Fig 1). Elastic stain (elastica van Giesson stain) showed deeply stained,

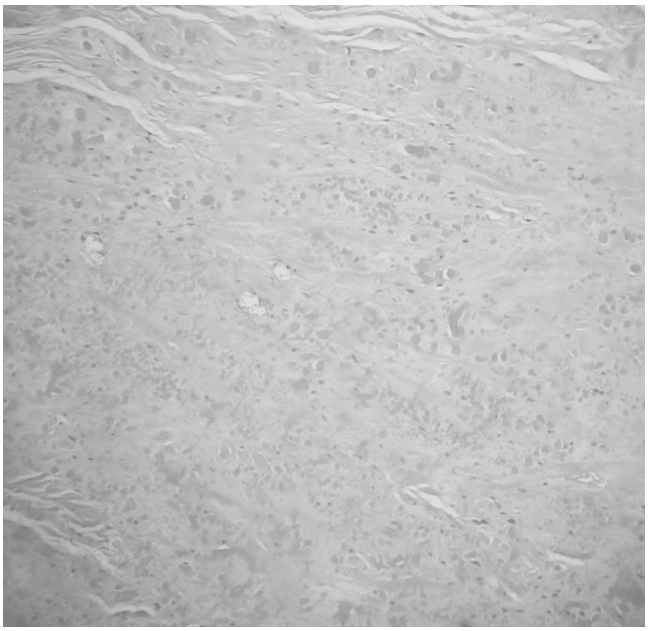

Fig 1: Hematoxylin and eosin staining image show fibrotic tissue with few cells and eosinophilic, and plump collagen fibers.(x 100)

branched-unbranched fibers with serrated and irregular margins (Fig 2). The lesion extended into surrounding muscle fibers; however, the resection margins were free of tumour and the postoperative course of the patient was uneventful.

Discussion

Elastofibroma is a benign soft tissue tumour occurring most often in the scapular region commonly located beneath the rhomboid major and latissimus dorsi muscles of elderly women.[1-5] It has been infrequently reported in other anatomic locations.[5] Different atypical location as thigh[2] and neck[6] are rarely encountered. The presented case was located in right pectoral region of the anterior chest wall. In the scapular region similar contralateral, bilateral lesion, when detected, virtually eliminates malignancy from the differential diagnosis and further supports the presumptive diagnosis of elastofibromas.[3,7] Elastofibromas are usually seen in patients of middle or old age, like in our case. An apparent peak in the female population beyond the sixth decade

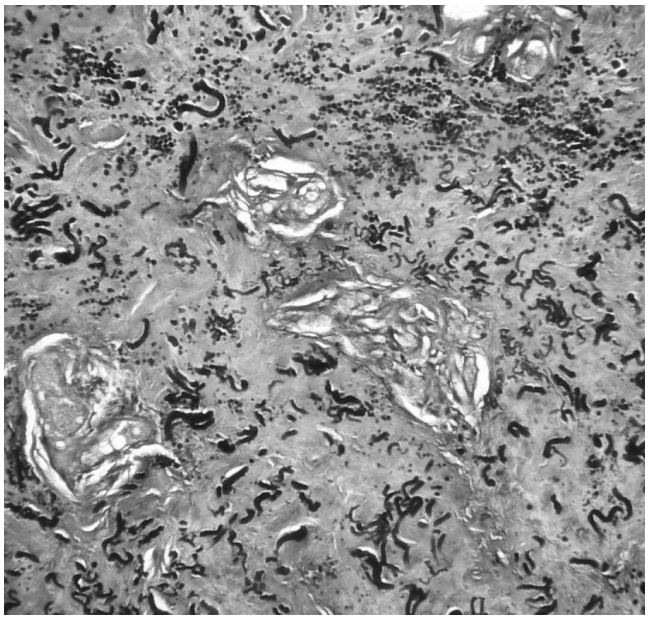

Fig 2: van Giesson staining show branched-unbranched fibers with serrated and irregular margins (x 100)

(mean age 65) was reported by Naylor et al[7] in a study on 12 patients. Some researches have stated that increased prevalence has been reported in manual workers which may imply that repetitive minor trauma plays a major role in the etiology.[1,4] Our patient was not a manual worker, and she had no history of hard or heavy labour during her lifetime. The pathogenesis of elastofibroma is still unclear. A multifactorial etiology may be more explanatory as none of the theories can entirely explain the whole spectrum of the cases.[4] Degeneration of elastic fibers after repetitive trauma or excessive scapulo-thoracic motion has been proposed as a causative factor.[1,4,8,9] Such findings support the hypothesis of a multistage pathogenic mechanism.

Radiographs, and computed tomography may not be helpful in differentiating elastofibroma from malignant tumours.[8] Magnetic resonance imaging was considered as the method of possible diagnosis, but occasionally enhancement of contrast agent, marked dominance of fat which is characteristic for malignant tumours may lead to a false result.[6,8] Zembsch et al[8] underlined that these features do not exclude the presence of elastofibroma. Histological findings are characteristic; and include adipocytes, fibroblasts, aggregates of petaloid globules within a collagenous matrix, and fern-like structures, revealing degenerative elastic fibers.[1,4,9] Elastofibroma dorsi is stained positively with vimentin as in our case, but not with smooth muscle actin (SMA), S-100, desmin, or p53 immunohistochemically[1]. Elastofibroma is a slow growing lesion, and surgical excision should be advised only for

symptomatic patients.[7-9] Biopsy is recommended even when the imaging presentation seems typical of elastofibroma. The pathologic findings are diagnostic. No treatment is necessary in the asymptomatic patient.[5,9] There have been no reported cases of malignant transformation.[9] Briccolli et al[3] at the last clinical evaluation of the operated patients observed that excised lesions had no evidence of local recurrence or joint disability, whereas a recurrence rate of 7% in another study has been related to incomplete surgery.[2] On the other hand Muramatsu et al.[10] reported that postoperative haematoma formation was an important complication of surgical treatment. Naylor et al[7] stated that increased awareness of the characteristic appearance and location of these benign, often asymptomatic lesions will increase radiologic diagnosis, decrease the need for biopsy, and decrease surgical removal of elastofibromas as presumed malignancies.

References

1. Kayaselcuk F, Demirhan B, Kayaselcuk U, Ozerdem OR,Tuncer I. Vimentin, smooth muscle actin, desmin, S-100 protein, p53, and estrogen receptor expression in elastofibroma and nodular fasciitis. Ann Diagn Pathos 2002;6:94 -9.
2. Kransdorf MJ, Meis JM, Montgomery E. Elastofibroma: MR and CT appearance with radiologic-pathologic correlation. AJR Am J Roentgenol 1992;159:575-9.
3. Briccoli A, Casadei R, Di Renzo M, Favale L, Bacchini P, Bertoni F. Elastofibroma dorsi. Surg Today 2000; 30:147-52.
4. Kara M, Dikmen E, Kara SA, Atasoy P. Bilateral elastofibroma dorsi: proper positioning for an accurate diagnosis. Eur J Cardiothorac Surg 2002;22:839-41.
5. Guha AR, Raja RC, Devadoss VG. Elastofibroma dorsi--a case report and review of literature. Int J Clin Pract 2004 ;58:218-20.
6. Maldjian C, Adam RJ, Maldjian JA, Rudelli R, Bonakdarpour A. Elastofibroma of the neck. Skeletal Radiol 2000; 29:109-11.
7. Naylor MF, Nascimento AG, Sherrick AD, McLeod RA. Elastofibroma dorsi: radiologic findings in 12 patients. AJR Am J Roentgenol 1996; 167:683-7.
8. Zembsch A, Schick S, Trattnig S, Walter J, Amann G, Ritschl P. Elastofibroma dorsi. Study of two cases and magnetic resonance imaging findings. Clin Orthop Relat Res 1999; 364:213-9.
9. Valls R, Melloni P, Darnell A, Sanchez-Flo R. Elastofibroma dorsi: a chest wall pseudotumor. Computed tomography and magnetic resonance imaging diagnosis. Acta Orthop Belg 1996; 62:103-6.
10. Muramatsu K, Ihara K, Hashimoto T, Seto S, Taguchi T. Elastofibroma dorsi: diagnosis and treatment. J Shoulder Elbow Surg 2007; 16:591-5.