

# Chronic Granulomatous Disease

Hamid Nawaz Tipu<sup>1</sup>, Tahir Aziz Ahmed<sup>2</sup>, Salman Ali<sup>3</sup>, Dawood Ahmed<sup>4</sup>, Muhammad Amin Waqar<sup>5</sup>

Armed Forces Institute of Pathology, Rawalpindi<sup>1,2,4,5</sup>, Military Hospital, Rawalpindi<sup>3</sup>

## Abstract

Chronic granulomatous disease (CGD) is an X-linked/autosomal recessive primary immunodeficiency disorder characterized by recurrent infections. The diagnosis is primarily based on simple Nitrobluetetrazolium dye reduction test. We describe here an unusual case of an 8 year old girl, as the disease is X-linked in most of the cases.

## Introduction

Chronic granulomatous disease (CGD) is an X-linked/autosomal recessive disorder characterized by recurrent infections with catalase positive bacteria and fungi, and granulomas in multiple organs.<sup>1</sup> The basic pathology is a defect in subunits of nicotinamide adenine dinucleotide phosphate (NADP) oxidase, whose normal functioning is essential for killing of phagocytosed bacteria by neutrophils. Affected patients succumb to recurrent infections, usually involving the skin, lymph nodes, lungs, liver and gastrointestinal tract, leading to death in first two decades of life.<sup>2,3</sup> Since its first description in the 1950s, notable advances have been made in the understanding of this disease. CGD is a rare but life threatening condition. It can be managed effectively after proper diagnosis. Screening test for this disease can be performed with

relative ease. Literature search has revealed only one publication from India in the subcontinent region.<sup>2</sup> It is felt that a greater physician awareness and availability of diagnostic facilities will improve the prognostic outlook for patients suffering from CGD. We describe here an unusual case of an 8 year old girl, as the disease is X-linked in most of the cases.

## Case Report

An 8 years old girl, born of a consanguineous marriage, was referred to us for investigations regarding immunodeficiency, in August 2007. She had the complaints of recurrent high grade fever, since the start of this year that was only transiently relieved by antipyretics and antibiotics. Each time fever recurred after the medicines were stopped. According to her parents, she started having high grade fever at the age of 2-3 months that was relieved with antibiotics but recurred after antibiotics were stopped. She had taken antituberculosis therapy at the age of 1 year but after 3-4 months of treatment, it was discontinued. At the age of around 2 years, she improved, albeit occasional mild respiratory tract infections, once or twice a year. At the age of 5 years, she developed an abscess on her right thigh that was surgically drained but she again developed high grade

fever following this procedure that persisted for a couple of months despite antibiotics.

She had a very strong family history, related to primary immunodeficiency. Her eldest brother died of meningitis at the age of 3 months. Then her eldest sister died of some respiratory tract infection at the age of 7 years. Another brother, 5th in siblings, died at the age of 18 months, who had developed oral ulcers according to the parents. Her remaining 4 sisters, aged 17, 14, 11 and 6 years were all well (fig 1). One of her maternal uncle died at the age of 2 months. Rest three maternal uncles are healthy.

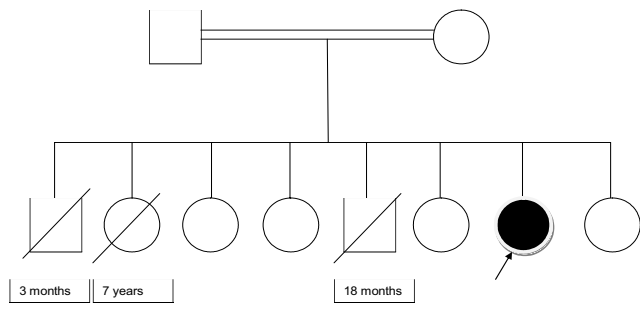


Fig 1: Family tree of the patient.

She had been vaccinated according to expanded program of immunization (EPI).

When she presented to us, she was a pale looking child with failure to thrive, hepatosplenomegaly and cervical lymphadenopathy. Both her height and weight were below 0.4th centile for her age. Earlier this year (2007), she had been investigated for the fever at Lahore. She had low haemoglobin (8.2 g/dl) with hypochromic microcytic picture and ESR 35 mm/1 hr. Her total leucocyte count was 15000/uL, with 64% neutrophils and 26% lymphocytes. Her serum total protein and globulin were raised (9.81 g/dl and 6.31 g/dl). Excision biopsy of cervical lymph nodes had revealed reactive hyperplasia. Trucut biopsy of right lung showed granulomatous inflammation with aspergillus hyphae. CT scan chest suggested malignant infiltrative process in right upper chest and left lung. We focused on immune status of the patient taking into consideration her clinical and laboratory data. Investigations at AFIP showed raised IgG levels (19 g/dl) with IgA, IgM and IgE levels within the age specific reference range. Anti candida and anti E coli antibody titer were normal (1:160 each). Lymphocyte subset analysis revealed a slight increase in her B cells and NK cells (706/uL and 412/uL respectively), for her age. But her nitrobluetetrazolium (NBT) dye reduction test characteristically revealed absolutely no reduction of dye by neutrophils, as shown in fig 2 (procedure attached as annex 'A'). The percentage of patient's neutrophils stimulated by candida and E coli that reduced the dye was



Fig 2: Patient negative NBT test (NBT dye, x40)

zero percent, as compared to control's 56% and 84% respectively. Based on her clinical presentation, family history and NBT test, the diagnosis of autosomal recessive form of chronic granulomatous disease was established. Her parents were counselled about the disease and the importance of prophylactic use of antibiotics and maintenance of an infection diary.

### Annex 'A'

#### Nitrobluetetrazolium Dye Reduction Test

1. Draw 3 ml of EDTA blood of the patient and a healthy person as a control.
2. Mark 6 test tubes as C1, C2 and C3 for control and T1, t2 and T3 for test.
3. Add 100 ul each of RPMI 1640 and NBT in each test tube.
4. Add 100 ul E coli endotoxin in tubes in C1 and T1 and 100 ul candida serum in tubes C2 and T2.
5. Add 100 ul of control's blood in C1, C2 and C3 and 100 ul of patient's blood in T1, T2 and T3.
6. Incubate at 37°C for 30 min and then at room temperature for another 30 min.
7. Add 300 ul neutral red in each tube.
8. Place a drop from each test tube on a glass slide and observe under microscope.

### Discussion

The presentation of the patient with history of respiratory tract infections, respiratory tract granulomas and aspergillus hyphae, hepatosplenomegaly, lymphadenopathy and a very strong family history pointed towards a possible primary immunodeficiency. The NBT test clinched the diagnosis of CGD. The NBT test depends on the capability of normal neutrophils to reduce the colourless NBT dye to

blue formazan, while in CGD this is not possible and hence diagnostic of CGD.<sup>4</sup> Leucocytosis, hypochromic microcytic anaemia, elevated ESR and increased serum immunoglobulin concentrations found in our patient merely reflect response to chronic infection.

CGD is a X-linked primary immunodeficiency disease in over two third of cases. In this group it is due to mutation in CYBB gene that encodes gp91 of NADPH oxidase enzyme. However, a significant proportion of cases are autosomal recessive due to mutations in NCF1 (p41), NCF2 (p67) and CYBA (p22) genes and hence can be found in girls.<sup>5</sup> CGD was infact the first inherited disease whose gene was identified by genetic mapping strategies.<sup>6</sup>

Although detailed statistics for primary immunodeficiency diseases in the sub-continent region could not be found despite extensive internet search, Rezaei et, al. have reported that chronic granulomatous disease is the second most common primary immunodeficiency disorder in Iran preceded only by CVID.<sup>7</sup>

In our experience autosomal recessive form of CGD presents with relatively mild manifestations. The first patient of CGD diagnosed in our department was a young girl about 7 years of age at the time of presentation. She improved on prophylactic antibiotics but was lost to follow-up 6 months after the diagnosis. The second patient was a newborn male. He presented with large pustules all over the body within the first week of birth. The patient was taken home against medical advice and unfortunately died within a week of diagnosis.

The diagnosis of this disease can be established with NBT screening test. The test is easy to perform and no special chemicals or equipment are needed. Only NBT and an ordinary microscope are sufficient. Chemiluminescence and bacteriocidal assays are the other tests used to diagnose CGD. Flowcytometric 2',7'-dichlorofluorescein (DCF) test can be used to identify

carriers. Specific forms of the disease can only be found by identifying genetic mutations.<sup>8</sup> Early diagnosis results in control of infection with appropriate use of antimicrobial agents.

The treatment is mainly directed towards treating and preventing infections although now gamma interferon is advocated as a new modality of prophylactic therapy.<sup>9</sup> Bone marrow transplantation may be considered and gene therapy may have a role in future.

## Conclusion

In the absence of any specific therapy, it is very important to identify carriers, especially in families in which a known case is already present. Genetic counselling of such families may help in reducing the incidence of the disease, especially the autosomal recessive form.

## References

1. Mackay IR, Rosen FS. Immunodeficiency Diseases Caused by Defects in Phagocytes. *NEJM* 2000; 343:1703-12.
2. Nair PS, Moorthy PK, Suprakashan S, Jayapalan S, Preethi K. Case Report: Chronic Granulomatous disease. *Indian J Dermatol* 2005; 71: 199-201.
3. Horwitz ME, Barrett J, Brwon MR, Carter CS, Childs R, Gallin JI et al. Treatment of Chronic Granulomatous Disease with Non-myeloablative Conditioning and a T-cell Depleted Hematopoietic Allograft. *NEJM* 2001; 344: 881-8.
4. Lowell C. Clinical Laboratory Methods for Detection of Cellular Immunity. In: Parslow TG, Stites DP, Terr AI, Imboden JB. *Medical Immunology*. 10th ed. United States: Lange Medical Books/McGraw-Hill Medical Publishing Division 2003; pp 234-49.
5. Wolfe LC, Curran KJ. Chronic Granulomatous Disease [Serial Online] 2003 [www.emedicine.com/ped/topic1590.htm](http://www.emedicine.com/ped/topic1590.htm)-108k [cited 14 August, 2007]
6. DNA: 50 years in the Open [online] 2003 [cited 2007 August 14]. Available from: <http://news.bbc.co.uk/2/hi/science/nature/2925217.stm>
7. Rezaei N, Aghamohammadi A, Moin M, Pourpak Z, Movahedi M, Gharagozlu M, et al. Frequency and Clinical Manifestations of Patients with Primary Immunodeficiency Disorders in Iran. Update from the Iranian Primary Immunodeficiency Registry. *J Clin Immunol*, 2006; 26:519-32
8. Illoh OC. Current Applications of Flow Cytometry in the Diagnosis of Primary Immunodeficiency Diseases. *Archives of Pathology and Laboratory Medicine* 2004; 128: 23-31.
9. Gallin JI, Alling DW, Malich HL, Wesley R, Koziol D, Marciano B et al. Itraconazole to Prevent Fungal Infection in Chronic Granulomatous Disease. *NEJM* 2003; 348: 2416-22.