

Pituitary Height on Magnetic Resonance Imaging Observation of Age and Sex Related Changes

Muhammad Faisal Ikram¹, Zafar Sajjad², Ishrat Shokh³, Amir Omair⁴

Department of Anatomy^{1,3}, Department of Community Health Sciences⁴, Ziauddin University, Karachi, Department of Radiology², Aga Khan University Hospital, Karachi.

Abstract

Objective: To establish measurements of selected pituitary parameters in cases with normal pituitary gland in ≤ 30 year old selected samples from Karachi.

Methods: A total of 220 subjects of ≤ 30 years of age with normal pituitary morphology were evaluated by using T2 weighted Magnetic Resonance (MR) Imaging. Pituitary height (PH) and shape of the superior surface of the gland was observed on midsagittal sections. Data was stratified into six groups on the basis of age and sex to observe the differences.

Results: After the second month of life, the pituitary height increased gradually to achieve its peak in the second decade of life in the females (6.3 ± 1.4 mm, $n = 43$) and the third decade of life in the males (5.9 ± 1 mm, $n = 41$). PH decreased gradually there after. Significant difference was observed in PH in different age groups in both genders. Gland was significantly higher in females than males in the second decade. Higher frequencies of convex superior surface followed the same pattern.

Conclusion: This study provided the reference values for the Pituitary height and the shape of the superior surface of the pituitary gland, which may contribute to establish credible reference values (JPMA 58:261;2008).

Introduction

With the recent advancement, Magnetic Resonance (MR) Imaging has become the modality of choice for visualizing the intracranial structures like sellar and the parasellar region.^{1,2} While visualizing intracranial structures on MR in different age groups, dynamic changes have been reported in the size, shape and signal intensity of the pituitary, which reflects the changes in the complex hormonal environment of this gland. These changes were more significant in females.³⁻⁴ Some authors have reported the maximum height of pituitary gland during the third decade of life^{4,5}, which follows a high frequency of convex upper border of the gland in the second decade of life. This can be explained by rapid hormonal changes at puberty specially gonadotropin.⁶ While some studies differ and have reported the maximum height in the second decade of life.⁷⁻⁸ No definite explanation is available to describe this difference.

The midsagittal height of the pituitary gland reflects the variations in the pituitary morphology more accurately.^{3,9,10} This may be understood by the anatomy of the rigid encasement of the gland with a soft superior limit, formed by the diaphragm sellae, which allows the upward growth of the gland. This may also be explained by the centrally placed gonadotrophs, which are mainly responsible for major morphological changes at puberty.

Age related changes in the shape of upper border have also been documented.^{11,12} A higher frequency of convex upper margin in females and in the second decade of life has also been observed, which is then followed by an increase in pituitary height in the third decade.^{3,4} T2 weighted sequences have been prioritized on T1 because of their dramatically reduced susceptibility for artifacts.¹³ Measurements of pituitary gland for various age ranges with different thickness of slices have been published. These studies have concluded the requirement of further studies to clarify the morphology.⁵ The Growth Hormone Research Society in their summary statement in 2000 identified the requirement of more normative data on PH and pituitary volume (PV) for the improvement of the quality of diagnosis.² This study was designed to analyze the age and sex related changes in pituitary morphology in a selected sample from Karachi. To the best of our knowledge the normative data for pituitary is not available for the population of south Asia. The purpose of this study was to establish measurements of selected pituitary parameters in cases with normal pituitary gland in the ≤ 30 year old selected population of Karachi.

Patients and Methods

This cross-sectional study was conducted at the

Department of Radiology, Ziauddin University Hospital, North Nazimabad Campus, Karachi.

All ≤ 30 year old patients who were referred for full cranial MR study during July 14, 2004 to July 13, 2005 and consented for the study were included in this study. All suspected or diagnosed cases of hormonal imbalance and epilepsy, patients with hydrocephalous, females with pregnancy or a postpartum period of ≤ 6 months, patients using hormonal preparations or drugs possibly affecting pituitary morphology e.g. gonadotrophins, phenothiazine, reserpine etc. were excluded. Patients with past history of intracranial surgery or currently having any intracranial mass-occupying lesion compressing sella or producing midline shift were also excluded from the study.

All patients were examined on 1.0 T scanner of Siemens Harmony Magnetom. MR Console was loaded with Syngo MR 2002A software. T2 weighted sagittal spin echo sequences with (3850-5240 / 95-116) (repetition time / echo time) were applied to obtain images. All images were taken on 4mm thick slice then were constructed on a 512 x 256 matrix.

Sagittal sections with visible cerebral aqueduct were taken for the measurement of Pituitary Height (PH). Shape of the Superior Surface of Pituitary (SS) was recorded as flat (F), concave (C), and convex (X). Height of the gland (PH) was measured as greatest distance between the upper and the lower border of the gland by using calipers provided with the software "Syngo MR 2002A", already installed on MR console. Values were measured in millimeters (mm).

Data analysis was done on computer package SPSS (Statistical Package for Social Sciences) version 10.0. The categorical variable, shape of the superior surface (SS) was reported as frequencies and percentages, while the numerical variable Pituitary Height PH was reported as mean \pm standard deviation (sd). Test of proportions / Chi-Square were used to compare categorical variables, while Student t-test / ANOVA were used to compare the means of the numerical variables. A p-value of < 0.05 was considered to be statistically significant.

Results

A total of 264 cases were recruited for this study. Of these 44 were excluded on the basis of exclusion criteria. In the 220 included cases, 129 (57%) were male and 91 (43%) were female. The data was stratified into six groups on the basis of age and gender.

The mean value of PH in the first decade of female was 4.1 ± 1 mm and 3.7 ± 1 mm in the first decade of male (Table 1). Independent t test showed no significant difference between two means ($p = 0.07$). In the second decade of life, mean PH was significantly ($p = 0.005$) higher

Table 1. Mean Pituitary Height in different age groups.

	Male n = 129	Female n = 91	p Value* Student's t test
≤ 10 years, n = 75	4.1 ± 1, 48	3.7 ± 1, 27	0.07
11 - 20 years n = 83	5.4 ± 1.3, 40	6.3 ± 1.4, 43	0.005
21 - 30 years n = 62	6.1 ± 1.3, 41	5.9 ± 1, 21	0.55
p Value** ANOVA	< 0.001	< 0.001	

* Comparison of PH in two genders within age group

** Comparison of PH in different age groups within gender

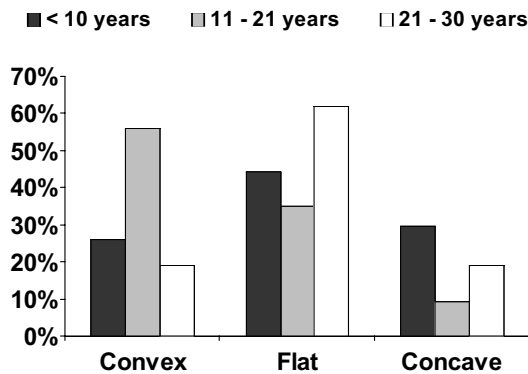


Figure 1. Shape of the superior surface of the pituitary gland in Females.

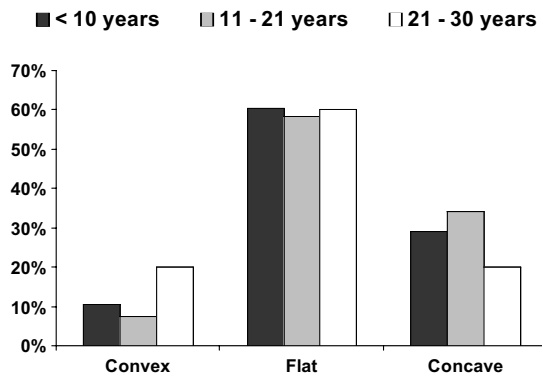


Figure 2. Shape of the superior surface of the pituitary gland in Males.

in female (6.3 ± 1.4 mm) as compared to males (5.4 ± 1.3 mm). In the third decade of life mean PH in the female was 6.1 ± 1.3 mm as compared to male's 5.9 ± 1 mm ($p = 0.55$).

The peak height of the gland in the female was observed in the second decade (6.3 ± 1.4 mm), while it was achieved in the third decade in males (5.9 ± 1 mm). When the data was further stratified into groups of five years, PH was found to be peaking in 16 - 20 year old age group of

females (6.8 ± 1 mm, $n = 21$) and in 21 - 25 year old age in the male group (6.3 ± 0.9 mm, $n = 20$).

The shape of the superior surface of the gland (SS) was observed in all 220 cases. Convex upper border was more common in females in ≤ 20 years cases (Figure z1 and 2). In males, frequency of flat upper surface was more common. We found a higher frequency of convex upper border in female (38%) than in male (12%). This difference was much higher in 11-20 year age group (male = 7%, female = 56%). In females, frequency of convex upper margin peaked in 16-20 years age group (71%) and in males, it was found in 20-25 year age group (30%). There was no gender difference in the shape of the upper border in 21 - 30 year age group, though the frequency of flat upper margin was higher in this age group.

Discussion

Midsagittal height of the pituitary gland reflects the variations in the pituitary morphology more accurately.^{3,9-10} Statistically significant differences in the mean height of the gland for various age groups in both sexes have been observed.¹⁴⁻¹⁶ In general, the means of pituitary height (PH) for various age groups in this study were in agreement with the published studies. Study from Turkey has reported relatively higher values of pituitary height among various age groups.⁷

Some of the authors have described the normal appearance of the pituitary gland in the first two years of life.^{2,9,17} The height of the pituitary gland decreases in the first two months of life and then gradually increases till adolescence. A rapid decrease in the secretion of growth hormone (GH) and Prolactin (PRL) is thought to be responsible for this phenomenon. GH and PRL secreting cells contribute more than 50% of pituitary cell population.¹⁸ Serum levels of Insulin like growth factor-1 (IGF-1) increases between two and nine months of age¹⁹⁻²¹, which in turn gives a negative feedback to the pituitary to decrease the secretions of GH.²² Similarly, levels of PRL are also reported to be decreased significantly by 2-4 weeks postnatally.²² This study found a constant PH in the first two years of life, though, no statistically significant conclusion was possible because of a low number of cases in this age group. There is a strong need to evaluate the morphology of the pituitary gland in this age group with a larger sample size.

The mean pituitary height among ≤ 10 year old boys was found 3.7 ± 1 mm. This is in agreement with the values provided by Elster and Suzuki,^{14,23} though, Denk and Kato have reported significantly higher values for this age group.^{4,7} Mean PH for female of same age was 4.1 ± 1 mm in this study, which is significantly higher than the mean PH of

the boys. Other authors have reported a significantly higher gland size in ≤ 10 year old boys as compared to females^{4,7,14} or have found no significant gender difference.¹¹

After the first decade of life, all authors have reported a significantly higher gland size in females which is in agreement with the findings of this study. We found that after the second month of life, the height of the pituitary gland increases gradually to achieve its maximum at puberty.

Hayakawa et al., while working on a cohort of Japanese population reported a peak in the height of the gland in 10-15 years old age group.⁹ This initial finding was followed by a detailed study by Elester et al. who reported it in 10-20 years old age group.⁸ On the contrary, Tsunoda et al and Kato et al reported the maximum height of the gland in the third decade of life.^{4,5} But none of the author has reported any gender difference in achieving peak height of the gland.

This study found the maximum height of the gland in the second decade of life in females and third decade of life in males. This finding is partially in agreement with the published data. In this stratified study where the groups were further divided into groups of five year each, it was found that in females, the maximum height was achieved in the 16-20 year old age group as compared to the males who achieved it in the 21-25 year old age group. This reflects a marginal variation which might not have been reflected in the previous studies who have reported it in a single decade of life for both the sexes. Increased secretion of LH and FSH is the main cause of increased height of the gland at puberty. Levels of both hormones are high in this age group. Peak height velocity (PHV), which is an important determinant of pubertal development, is achieved five year earlier in females as compared to males. This fact may explain early achievement of the maximum height of the gland in the females as compared to males. Other than these speculations, we do not know other reasons for early achievement of peak pituitary height in females, and more data is required before a conclusion can be reached.

Frequency of convex upper border of the pituitary gland is reported to be higher in young adults. It is important to differentiate the normal convex upper border of the pituitary from an abnormal convex upper border due to microadenoma, lymphocytic adenohypophysitis and pituitary cyst etc. For this reason, chronological changes in the shape of the pituitary upper border in young adults, was done in this study.

We found a higher frequency of convex upper border in females which was significantly higher in the 11-20 year age group ($p < 0.001$), which is consistent with the published data. In females, the frequency of convex upper

margin peaked in the 16-20 year age group (71%) and in males, it was found in the 20-25 years age group (30%). This finding coincided with the timing of peak PH in the same age groups. On the contrary, Kato et al have reported that the height of pituitary gland was highest in the 20-24 years age group (6.6 ± 1.2 mm), while the convex upper border was most frequent in the 10-14 years age group. They concluded that the pituitary gland in pubescent males and females appears to enlarge to form a convex upper border at first, followed by an increase in height ten years later.

Conclusion

This data provided reference values for the pituitary height and the shape of the superior surface of the pituitary gland, which are important diagnostic parameters for the evaluation of pituitary pathologies. As the differences between published normative data from different population are evident, values provided by this study are in agreement with some of the studies.

References

1. Bozzola M, Adamsbaum C, Biscaldi I, Zecca M, Cisternino M, Genovese E, et al. Role of magnetic resonance imaging in the diagnosis and prognosis of growth hormone deficiency. *Clin Endocrinol (Oxf)* 1996;45:21-6.
2. Growth Hormone Research Society. Consensus guidelines for the diagnosis and treatment of growth hormone (GH) deficiency in childhood and adolescence: summary statement of the GH Research Society. *GH Research Society. J Clin Endocrinol Metab* 2000;85:3990-3.
3. Doraiswamy PM, Potts JM, Axelson DA, Husain MM, Lurie SN, Na C et al. MR assessment of pituitary gland morphology in healthy volunteers: age- and gender-related differences. *AJNR. Am J Neuroradiol* 1992;13: 1295-9.
4. Kato K, Saeki N, Yamaura A. Morphological changes on MR imaging of the normal pituitary gland related to age and sex: main emphasis on pubescent females. *J Clin Neurosci* 2002;9:53-6.
5. Tsunoda A, Okuda O, Sato K. MR height of the pituitary gland as a function of age and sex: especially physiological hypertrophy in adolescence and in climacterium. *AJNR Am J Neuroradiol* 1997;18:551-4.
6. Argyropoulou MI, Kiortsis DN, Metafratzi Z, Efremidis SC. Magnetisation transfer imaging of the normal adenohypophysis: the effect of sex and age. *Neuroradiology* 2001;43:305-8.
7. Denk CC, Onderoglu S, Ilgi S, Gurcan F. Height of normal pituitary gland on MRI: differences between age groups and sexes. *Okajimas Folia Anat Jpn* 1999;76:81-7.
8. Elster AD, Chen MY, Williams DW 3rd, Key LL. Pituitary gland: MR imaging of physiologic hypertrophy in adolescence. *Radiology* 1990;174:681-5.
9. Hayakawa K, Konishi Y, Matsuda T, Kuriyama M, Konishi K, Yamashita K, et al. Development and aging of brain midline structures: assessment with MR imaging. *Radiology* 1989;172:171-7.
10. Lurie SN, Doraiswamy PM, Husain MM, Boyko OB, Ellinwood EH Jr, Figiel GS, et al. In vivo assessment of pituitary gland volume with magnetic resonance imaging: the effect of age. *J Clin Endocrinol Metab* 1990;71:505-8.
11. Dietrich RB, Lis LE, Greensite FS, Pitt D. Normal MR appearance of the pituitary gland in the first 2 years of life. *AJNR Am J Neuroradiol* 1995;16:1413-9.
12. Tien R D, Kucharczyk J, Bessette J, Middleton M. MR imaging of the pituitary gland in infants and children: changes in size, shape, and MR signal with growth and development. *AJR Am J Roentgenol* 1992;158:1151-4.
13. Pinker K, Ba-Ssalamah A, Wolfsberger S, Mlynarik V, Knosp E, Trattnig S. The value of high-field MRI (3T) in the assessment of sellar lesions. *Eur J Radiol* 2005;54:327-34.
14. Suzuki M, Takashima T, Kadoya M, Konishi H, Kameyama T, Yoshikawa J,

- et al. Height of normal pituitary gland on MR imaging: age and sex differentiation. *J Comput Assist Tomogr* 1990;14:36-9.
15. Argyropoulou M, Perignon F, Brunelle F, Brauner R, Rappaport R. Height of normal pituitary gland as a function of age evaluated by magnetic resonance imaging in children. *Pediatr Radiol* 1991;21:247-9.
 16. Sharafuddin MJ, Luisiri A, Garibaldi LR, Fulk DL, Klein JB, Gillespie KN, et al. MR imaging diagnosis of central precocious puberty: importance of changes in the shape and size of the pituitary gland. *AJR Am J Roentgenol* 1994;162:1167-73.
 17. Kiortsis D, Xydis V, Drougia AG, Argyropoulou PI, Andronikou S, Efremidis SC, et al. The height of the pituitary in preterm infants during the first 2 years of life: an MRI study. *Neuroradiology* 2004;46:224-6.
 18. Pelletier G, Robert F, Hardy J. Identification of human anterior pituitary cells by immunoelectron microscopy. *J Clin Endocrinol Metab* 1978;46:534-42.
 19. Miller JD, Wright NM, Esparza A, Jansons R, Yang HC, Hahn H, et al. Spontaneous pulsatile growth hormone release in male and female premature infants. *J Clin Endocrinol Metab* 1992;75:1508-13.
 20. Rajaram S, Carlson SE, Koo WW, Rangachari A, Kelly DP. Insulin-like growth factor (IGF)-I and IGF-binding protein 3 during the first year in term and preterm infants. *Pediatr Res* 1995;37:581-5.
 21. Wright NM, Northington FJ, Miller JD, Veldhuis JD, Rogol AD. Elevated growth hormone secretory rate in premature infants: deconvolution analysis of pulsatile growth hormone secretion in the neonate. *Pediatr Res* 1992;32:286-90.
 22. Perlman M, Schenker J, Glassman M, Ben-david M. Prolonged hyperprolactinemia in preterm infants. *J Clin Endocrinol Metab* 1978;47:894-7.
 23. Elster AD, Sanders TG, Vines FS, Chen MY. Size and shape of the pituitary gland during pregnancy and post partum: measurement with MR imaging. *Radiology* 1991;181:531-5.
-