

Stereotactic Radiosurgery for pituitary adenomas: A review of literature

Kaynat Siddiqui¹, Saqib Kamran Bakhshi², Muhammad Shahzad Shamim³

Abstract

Stereotactic radiosurgery (SRS) is a choice of treatment for pituitary adenomas (PA), particularly for residual or recurrent disease, apart from surgery. It has a progression free survival and endocrine remission rate comparable to surgery, with fewer side effects, making it an ideal tool for dealing with PA. In this review, we have discussed the role of SRS for primary as well as post-operative residual/recurrent PA, and have assessed its safety and outcomes.

Keywords: Pituitary adenoma, Stereotactic Radiosurgery, SRS, Gamma Knife Radiosurgery.

DOI: <https://doi.org/10.47391/JPMA.22-005>

Introduction

Trans-sphenoidal resection has been the mainstay in treatment of pituitary adenomas (PA). Managing residual or recurrent tumours, however, has been a dilemma for most surgeons. Treatment options include watchful observation for small non-growing tumours, and re-operation or radiotherapy for growing lesions.¹ The alteration in bony anatomy after the first surgery, local fibrosis/scarring, higher risk of CSF leaks and the chance of incomplete resection make second attempt at approaching these tumours via trans-sphenoidal route challenging.² Factors influencing choice of treatment include secretory nature of tumour, cavernous sinus invasion and extent of compression on optic chiasm.²

Non-surgical treatment modalities for managing non-functioning pituitary adenoma include conventional fractionated external beam radiotherapy (EBRT) and stereotactic radiosurgery (SRS).³ Progressive development and improvement in SRS during the last decade, have made it one of the ideal choices for managing patients medically unfit for surgery, for tumours left behind after incomplete resection, and to restrict the growth of residual tumours showing disease progression.³ SRS works by disintegrating DNA strands directly as a result of radiation, as well as by causing the release of free radicals, and by progressively obliterating vascular supply to the tumour.⁴ With a dose of 12-18 Gy, growth restriction can be achieved in up to 90% cases according to some studies, with

¹Intern, Department of Surgery, Jinnah Postgraduate Medical Centre, Karachi;

^{2,3}Section of Neurosurgery, Department of Surgery, Aga Khan University Hospital, Karachi, Pakistan.

Correspondence: Muhammad Shahzad Shamim. e-mail: shahzad.shamim@aku.edu

significantly lower morbidity as compared to surgery.¹ Due to relatively small risk of complications such as

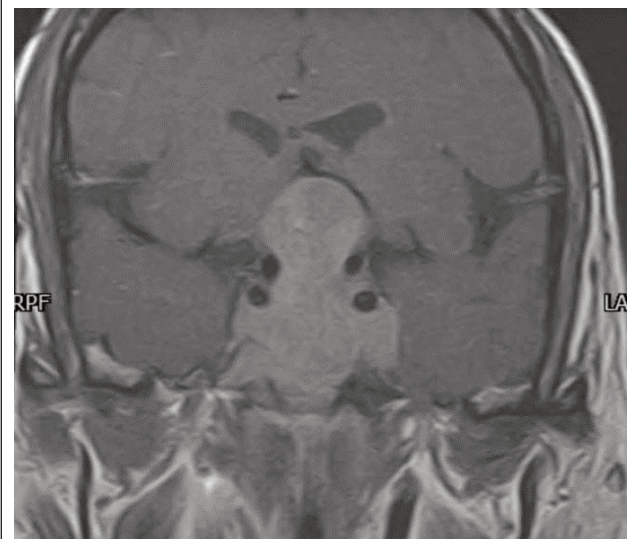


Figure-1: MRI brain, coronal section, delayed image T1 post-contrast sequence, of a 58 years old male, showing a giant contrast enhancing sellar and suprasellar lesion, which is displacing the floor of the 3rd ventricle, and is partially encasing both the internal carotid arteries.

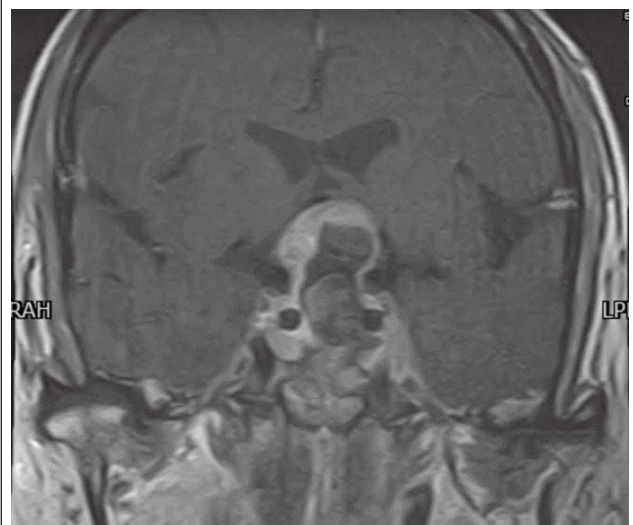


Figure-2: MRI brain, coronal section, delayed image T1 post-contrast sequence, of the same patient after trans-sphenoidal resection. The previously seen bulk of the tumour has been maximally resected with small residual tumour, and the mass effect has been reduced. Histopathology was reported as pituitary adenoma. The patient was advised stereotactic radiosurgery for the residual disease.

deterioration of vision, hypopituitarism and injury to hypothalamus, and extensively published literature supporting its utility, SRS is slowly gaining popularity in treating pituitary adenomas.⁵ In this study, we have conducted an extensive literature search to identify studies on the role of SRS for pituitary adenomas, and summarise the findings. SRS in this review will include gamma knife radiosurgery as well as cyberknife radiosurgery.

Review of evidence

In one of the earliest comprehensive retrospective studies conducted by Castinetti et al., it was concluded that SRS is effective in causing remission of secretory pituitary adenomas in more than 40% cases after a mean follow-up of 8 years (96 months) from surgery.⁶ They reviewed 76 patients who had received gamma knife radiosurgery as a primary treatment or as an adjunct to surgery, and reported the risk of developing hypopituitarism to be the main adverse effect of SRS, among all patients in their cohort.⁶ Park et al., conducted the first large scale study on the outcomes of SRS in 125 patients with non-functioning pituitary adenomas, over a 22-year period.⁷ One hundred and ten patients (88%) had residual disease after 1 or more surgeries. The median radiation dose was 13 Gy, and median target volume was 3.5 cm³.⁷ They reported a reduction in tumour size in 66 (53%) patients, no change in size in 46 (37%) patients and tumour progression in 13 (10.4%) patients.⁷ At 1-, 5- and 10-year follow-up after SRS, the tumour control rates were 99%, 94% and 76% respectively.⁷ In a similar study published a year later, 140 patients who had gamma knife surgery were retrospectively reviewed for long-term outcomes by Starke et al.⁸ Thirteen of these patients had received radiosurgery as a primary treatment, while 123 had undergone at least 1 surgery before SRS.⁸ The mean tumour volume was 5.6 cm³ and the mean marginal dose was 18 Gy.⁸ They reported a better 10-year progression-free survival at 87% as compared to Part et al., and a higher radiation dose might have been the reason.^{7,8} The most common complication was delayed hypopituitarism, seen in 30.3% patients.⁸

The role of SRS without surgery in treating pituitary adenomas was studied in 41 patients who could not be operated due to comorbidities or patients' choice, by Lee et al.⁹ They reported a 10-year tumour control rate of 85% at a median tumour margin dose of 12 Gy, and concluded that SRS can be employed as the primary treatment modality for treating non-functioning pituitary adenomas with good tumour controls, and minimal risks.⁹ Hasegawa et al., published a retrospective case series of 16 patients with non-functioning pituitary adenomas, who had undergone gamma knife radiosurgery alone, without

surgery.¹⁰ The median tumour size was 2.0 cm³ and the median radiation dose was 15 Gy. Fifteen patients had shown tumour regression and one had a stable disease, at a median follow-up of 98 months.¹⁰ Only 1 patient in their series had hypopituitarism due to pituitary apoplexy prior to SRS, requiring hormone replacement therapy. They had concluded SRS to be a safe treatment option for non-functioning pituitary adenomas, though because of smaller sample size, they had cautioned against the possibility of long-term hypopituitarism, radiation-induced neoplasm and visual deterioration due to optic neuropathy.¹⁰

Wu et al., conducted a case control study on 75 patients with acromegaly, and compared the endocrine and surgical outcomes of primary gamma-knife surgery with SRS after partial tumour resection.¹¹ They concluded no significant difference between the two groups in terms of local disease control, endocrine remission and tumour recurrence, and recommended SRS for all patients with residual or recurrent growth-hormone secreting adenomas, as well as a primary treatment option for patients who are high-risk for surgery.¹¹ Kotecha et al., conducted a systematic review and meta-analysis on the outcomes and adverse effects of SRS for non-functioning pituitary adenomas.¹² They included 35 studies (2671 patients) in their review. They recommended SRS as a safe treatment option, but also proposed that more data will be needed to put forward definitive guidelines, as all the available evidence comprised of retrospective studies.¹² In another recent systematic review and meta-analysis regarding residual or recurrent pituitary adenomas, 26 articles (2315 patients) were analyzed.¹ The review proved efficacy of SRS in residual and recurrent pituitary adenomas, irrespective of the secretory nature, with fewer side effects.¹ However, the absence of any randomized control trial was an important limitation of this review as well.¹

Conclusion

The available evidence supports the effectiveness of SRS in managing residual/recurrent, functional and non-functional pituitary adenomas alike, with progression-free survival of more than 80% at 10-years. Due to absence of any randomized control trials, application of SRS as a first-line treatment/replacement of surgery in pituitary adenomas is still debatable, and requires more data.

References

1. Heringer LC, de Lima MM, Rotta JM, Botelho RV. Effect of stereotactic radiosurgery on residual or relapsed pituitary adenoma: A systematic review and meta-analysis. *World Neurosurg.* 2020;136:374-81.
2. Heringer LC, de Oliveira MF, Rotta JM, Botelho RV. Effect of repeated transsphenoidal surgery in recurrent or residual pituitary adenomas: A systematic review and meta-analysis. *Surg. Neurol. Int.* 2016;7: 14.
3. Kotecha R, Sahgal A, Rubens M, De Salles A, Fariselli L, Pollock BE, Levivier M, Ma L, Paddick I, Regis J, Sheehan J. Stereotactic

- radiosurgery for non-functioning pituitary adenomas: meta-analysis and International Stereotactic Radiosurgery Society practice opinion. *Neuro Oncol.* 2020;22:318-32.
4. Jagannathan J, Yen CP, Pouratian N, Laws ER, Sheehan JP. Stereotactic radiosurgery for pituitary adenomas: a comprehensive review of indications, techniques and long-term results using the Gamma Knife. *J Neuro-Oncol.* 2009;92:345-56.
 5. Sheehan JP, Pouratian N, Steiner L, Laws ER, Vance ML. Gamma Knife surgery for pituitary adenomas: factors related to radiological and endocrine outcomes. *J Neurosurg.* 2011;114:303-9.
 6. Castinetti F, Nagai M, Morange I, Dufour H, Caron P, Chanson P, Cortet-Rudelli C, Kuhn JM, Conte-Devolx B, Regis J, Brue T. Long-term results of stereotactic radiosurgery in secretory pituitary adenomas. *J Clin Endocrin Metab.* 2009;94:3400-7.
 7. Park KJ, Kano H, Parry PV, Niranjana A, Flickinger JC, Lunsford LD, Kondziolka D. Long-term outcomes after gamma knife stereotactic radiosurgery for non-functional pituitary adenomas. *Neurosurg.* 2011;69:1188-99.
 8. Starke RM, Williams BJ, Jane JA, Sheehan JP. Gamma Knife surgery for patients with non-functioning pituitary macroadenomas: predictors of tumor control, neurological deficits, and hypopituitarism. *J Neurosurg.* 2012;117:129-35.
 9. Lee CC, Kano H, Yang HC, Xu Z, Yen CP, Chung WY, Pan DH, Lunsford LD, Sheehan JP. Initial Gamma Knife radiosurgery for non-functioning pituitary adenomas. *J Neurosurg.* 2014;120:647-54.
 10. Hasegawa T, Shintai K, Kato T, Iizuka H. Stereotactic radiosurgery as the initial treatment for patients with non-functioning pituitary adenomas. *World Neurosurg.* 2015;83:1173-9.
 11. Wu Y, Wang M, Xu Y, Wen R, Liu X, Gao Y, Shi Y, Pan W, Deng H, Wang W. Comparing primary gamma knife radiosurgery and postoperative gamma knife radiosurgery for acromegaly: A monocenter retrospective study. *Clin Neurol Neurosurg.* 2021;200:106385.
 12. Kotecha R, Sahgal A, Rubens M, De Salles A, Fariselli L, Pollock BE, Levivier M, Ma L, Paddick I, Regis J, Sheehan J. Stereotactic radiosurgery for non-functioning pituitary adenomas: meta-analysis and International Stereotactic Radiosurgery Society practice opinion. *Neuro-Oncol.* 2020;22:318-32.
-