

## Ruptured splenic abscess: A rare case entity

Ayra Suleman<sup>1</sup>, Muhammad Zeeshan Sarwar<sup>2</sup>, Yasin Rafi<sup>3</sup>, Syed Asghar Naqi<sup>4</sup>

### Abstract

Ruptured splenic abscess has been reported as a rare clinical entity in literature. We present the case of a middle aged female with peritonitis due to a ruptured splenic abscess. Emergency splenectomy was done and broad spectrum antibiotic was given postoperatively. However, the patient could not survive and died on the 4th postoperative day. We propose that a ruptured splenic abscess should always be considered in the differential diagnosis of peritonitis, especially in an immunocompromised individual.

**Keywords:** splenic abscess, immunocompromised, splenectomy.

**DOI:** <https://doi.org/10.47391/JPMA.11-2381>

### Introduction

Splenic abscess is a relatively rare disease usually occurring in immunocompromised conditions such as neoplasia, immunodeficiency diseases or diabetes.<sup>1</sup> The incidence of this grave disease ranges from 0.05-0.7% in autopsy studies<sup>2</sup> and its mortality rate is 100% in the absence of treatment.<sup>3</sup> It often presents as a triad of fever, tenderness in left upper quadrant of abdomen and leukocytosis.<sup>4</sup> Diagnosis can be confirmed by ultrasound or CT scan.<sup>5</sup> To date, only a few cases of ruptured splenic abscess have been reported in literature.<sup>6</sup> We report a case of a middle aged woman with diabetes presenting as peritonitis due to ruptured splenic abscess. Informed consent was taken from the patient on admission regarding treatment and publication of data related to her disease.

### Case Report

We report a case presenting in the emergency department of East surgical ward, Mayo Hospital, Lahore on 10th of July, 2020. A 60 year old woman presented with history of high grade fever for 10 days and generalized abdominal pain and relative constipation for 1 day. She was prescribed antibiotics by the local doctor but her fever was not relieved. She had been suffering from diabetes mellitus for 20 years and was on oral hypoglycaemic agents, however, her Blood Glucose was poorly controlled. There was no history of gallstones, acid peptic disease, cardiac disease,

<sup>1,2,4</sup>Department of Surgery, Mayo Hospital, Lahore, Pakistan; <sup>3</sup>Department of Surgery, Services Hospital, Lahore, Pakistan.

**Correspondence:** Ayra Suleman. e-mail: [ayrasuleman@gmail.com](mailto:ayrasuleman@gmail.com)

or pelvic inflammatory disease.

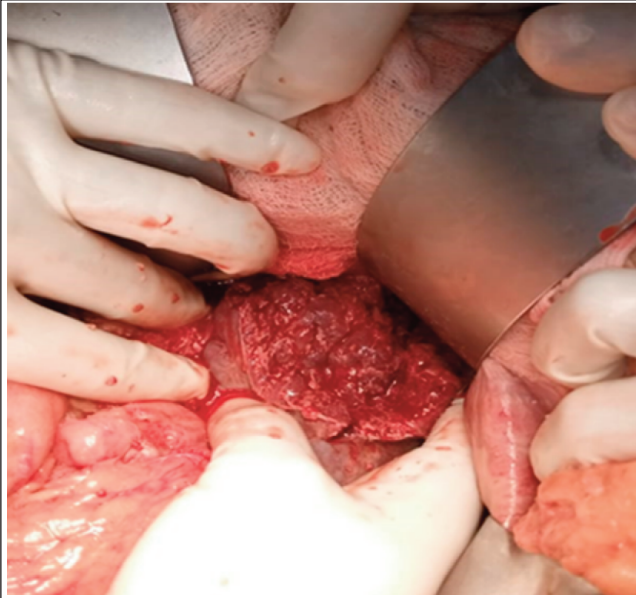
At presentation, pulse was 126/min, blood pressure was 80/60, respiratory rate was 28/min, and temperature was 102°F. There was generalized abdominal tenderness and guarding, more in the upper abdomen. Bowel sounds were sluggish. The digital rectal examination was unremarkable. On chest auscultation, there was decreased air entry in the lower zones with oxygen saturation of 90% at room air. She was oliguric, with a urine output of only 10 ml in the first hour.

**Investigations:** Hb=9.9g/dl, WBC count =22 x 10<sup>3</sup>/ul with granulocytosis, blood urea=128 mg/dl and serum creatinine=2.6 mg/dl. ABGs showed type 1 respiratory failure and partially compensated metabolic acidosis. Liver enzymes, serum amylase, serum electrolytes, and urinary ketones were within normal limits. ECG and chest X-ray were normal. An ultrasound of the abdomen showed free fluid in the peritoneal cavity.

Since the patient was in shock, CVP line was passed, and central venous pressure was estimated to be 4cmH<sub>2</sub>O. Her parameters improved upon giving 4L/min oxygen and 6 litres of normal saline. She was planned for exploration with provisional diagnosis of enteric perforation. On exploration, 1 liter of pus was evacuated from the abdominal cavity with a ruptured splenic abscess. There were dense adhesions of the spleen, with the stomach, diaphragm and 50% of splenic parenchyma damaged. The stomach, small and large bowel, appendix, liver, ovaries, and fallopian tubes were normal. Splenectomy and abdominal lavage were done. Figure shows the intraoperative ruptured splenic abscess.

Postoperatively, the patient was ventilated and broad spectrum antibiotics were given. On the second postoperative day, the patient suffered from atrial fibrillation with shock. She was cardioverted, and intravenous amiodarone was given, which led to resumption of normal rhythm. There was no previous history of cardiac disease. Her Trop-I level was within normal limits. On the 4th postoperative day, she suddenly collapsed haemodynamically, and could not be revived despite all attempts.

The culture and sensitivity of pus showed the growth of *Escherichia coli*. The splenectomy specimen measured



**Figure:** Intraoperative picture of ruptured splenic abscess.

13x9x2 cm having acute on chronic inflammation and necrotic debris on histopathology. There was no evidence of granuloma formation or malignancy.

## Discussion

Splenic abscess is a rare entity, while its rupture into the peritoneal cavity is even more uncommon, with less than 100 cases reported in literature so far.<sup>7</sup> Despite its rarity, a ruptured splenic abscess should always be considered in the differential diagnosis of acute abdomen, particularly in an immunocompromised patient. Common predisposing factors include neoplasia, diabetes, trauma, metastatic infection, splenic infarct or immunodeficiency.<sup>1</sup> Our patient suffered from type-2 diabetes mellitus, which led to the formation of a splenic abscess.

Patients commonly present with fever, left upper quadrant pain or tenderness, and left pleural effusion.<sup>2</sup> Although our patient had high grade fever for 10 days, there was only one day history of abdominal pain starting from the upper abdomen and later on becoming generalized. It implies that the splenic abscess caused pain to the patient only on rupture. This was probably due to decreased pain perception, which is a common phenomenon in diabetes mellitus.

Ultrasound and CT scan are reliable investigations for the diagnosis. X-ray findings are non-specific, including left pleural effusion, elevation of left diaphragm, or free air under the diaphragm.<sup>5</sup> X-rays showed no such abnormalities in our case. Typical ultrasound findings are splenomegaly and decreased echogenicity.<sup>4</sup> However, in our case, it only revealed free fluid. CT scan is the gold

standard investigation, characteristically showing low density lesions that fail to enhance on contrast administration.<sup>8</sup> It was not done in our case, due to non-availability in the emergency department.

Drained pus revealed the growth of *Escherichia coli*. This observation is in accordance with the literature, which reports aerobic microbes as the most common causative organisms, particularly *Staphylococci*, *Streptococci*, *Salmonella*, and *Escherichia coli*.<sup>2</sup>

The optimal treatment for splenic abscess is still a matter of debate. Options include parenteral antibiotic therapy, percutaneous aspiration, and splenectomy.<sup>1</sup> Laparoscopic splenectomy can be done in selected cases with the additional advantages of rapid recovery and a short hospital stay.<sup>9</sup> Open splenectomy is recommended in individual case reports for a ruptured splenic abscess because it facilitates adhesiolysis and abdominal lavage.<sup>5,8</sup>

High mortality is typically associated with an immunocompromised status and multiple abscesses.<sup>4</sup> Our patient was suffering from diabetes and presented to us in septic shock, having a high WBC count and metabolic acidosis. Thus, she could not survive despite the prompt surgery and broad spectrum antibiotic cover.

## Conclusion

Splenic abscess should be considered in the differential diagnosis of acute abdomen, particularly in an immunocompromised patient. The recommended treatment is open splenectomy and antibiotic therapy, which might provide a chance of survival.

**Disclaimer:** None.

**Conflict of Interest:** The Head of Department permitting the writing and publication of this case report is also a co-author.

**Funding Sources:** None.

## References

1. Lee WS, Choi ST, Kim KK. Splenic abscess: a single institution study and review of the literature. *Yonsei Med J.* 2011; 52:288–92.
2. Lee MC, Lee CM. Splenic Abscess: An Uncommon Entity with Potentially Life-Threatening Evolution. *Can J Infect Dis Med Microbiol.* 2018; 2018:8610657.
3. Kafadar MT, Teker İ, Gök MA, Uğurlu ET, Çetinkaya İ. Atraumatic splenic rupture secondary to abscess in a hemodialysis patient: a rare and fatal cause of acute abdomen diagnosed late. *J Surg Case Rep.* 2018; 2018:rjy103.
4. Waheed A, Mathew G, Zemaitis MR. Splenic Abscess. In: *Stat Pearls*. Treasure Island (FL): Stat Pearls Publishing, 2020.
5. Braat MN, Hueting WE, Hazebroek EJ. Pneumoperitoneum secondary to a ruptured splenic abscess. *Intern Emerg Med.* 2009; 4:349-51.

6. Agarwal N, Sharma A, Garg G. Non-traumatic ruptured splenic abscess presenting with pneumoperitoneum in an immunocompetent patient: a diagnostic dilemma. *BMJ Case Rep.* 2019; 12:e228961.
  7. Mc Clenathan J. Ruptured splenic abscess as a cause of acute abdomen: Report of two cases and review of literature. *Int J Surg.* 2009; 22:14-26.
  8. Datey SM, Charles N, Patidar H, Bandil S, Bajpai S, Gadodia M. Splenic abscess: Review article. *J Evol Med Dent Sci.* 2015; 4:5569-76.
  9. Bauman Z, Lim J. Pneumoperitoneum as a result of a ruptured splenic abscess. *J Surg Case Rep.* 2013; 2013:rjt111.
-