

## Unusual presentation of metastatic pancreatic carcinoma

Muhammad Khurram Salahuddin, Zeeshan Waheed, Asif Jan Muhammad

### Abstract

Pancreatic carcinoma is one of the most common and deadly cancers in the world. It typically presents with abdominal pain, vomiting and weight loss. Here, we report a case who presented with respiratory symptoms of cough, fever and decreased oral intake without any typical abdominal sign and symptoms. Later on, the patient's workup revealed that she had advanced/metastatic pancreatic carcinoma.

**Keywords:** Pancreatic Carcinoma, Miliary Nodules.

**DOI:** <https://doi.org/10.47391/JPMA.318>

### Introduction

Pancreatic cancer is one of the deadly cancers in the world. In the United States it is the fourth leading cause of cancer related deaths, and the seventh most common cause of cancer.<sup>1</sup> Among men it is the tenth, where as in women it is the ninth most common cancer. It accounts for 8% of all cancer related deaths.<sup>2</sup> Usually pancreatic carcinoma presents with abdominal pain, vomiting, anorexia and weight loss. We present a case of pancreatic carcinoma with respiratory symptoms without any classical abdominal symptoms.

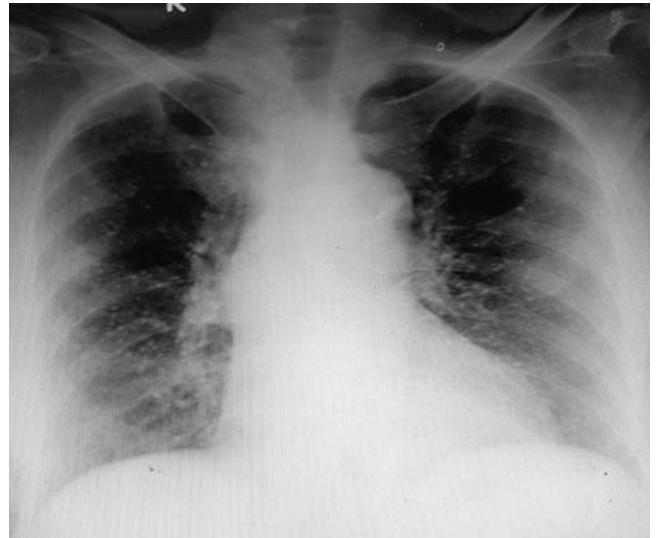
### Case Report

An 80-year-old lady presented in ER of Patel Hospital, Karachi on 27th December 2019, with complains of cough for five days, decreased oral intake for seven days, and low grade fever for 15 days. Cough was dry in nature with no phlegm. She denied any dysphagia and regurgitation. She also complained of fever which was low grade without rigors and chills, not occurring on any specific time. There was no abdominal pain and discolouration of the skin. She had history of weight loss of 8kg in the last three months. She had a past history of hypertension and Ischaemic heart disease. Her husband had pulmonary tuberculosis which had been completely treated. She denied any chest pain, orthopnoea and paroxysmal nocturnal dyspnoea. She was pale and dehydrated on admission. On chest auscultation, there was bilateral equal air entry with occasional crepitations.

.....  
Department of Medicine, Patel Hospital, Karachi, Pakistan.

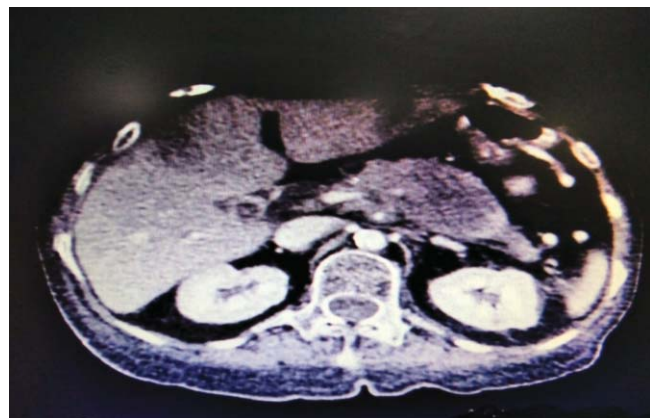**Correspondence:** Muhammad Khurram Salahuddin.

Email: drms12@gmail.com



**Figure-1:** Chest X-ray showing bilateral diffuse nodular infiltrates of military pattern.

Abdominal examination was normal, except for mild tenderness at the right hypochondriac region. Her other examination was normal. Her workup showed haemoglobin of 12 g/dl, WBC count of 21,000/uL and platelets count were 365,000/uL. Potassium was 2.7meq/dl. Chest X-ray showed bilateral, small, multiple nodules typical of miliary pattern (Figure-1). Sputum for culture and sensitivity and Acid Fast Bacilli was sent. Differential diagnosis of atypical pneumonia, pulmonary TB and metastatic disease were made. CT scan of the chest was ordered which revealed few well-defined soft



**Figure-2:** CT of the abdomen showing hypo dense area in the body of pancreas suggestive of pancreatic carcinoma.

tissue density nodules in the posterior segment of both upper lobes and apical segments of both lower lobes, measuring up to 4-5 mm, suggestive of pulmonary metastases. It also showed 3-4 soft-tissue density nodules in right and left lobe of the liver. As CT of the chest showed liver nodules, CT of the abdomen with contrast was done which revealed hypo dense area in the body of pancreas, measuring 3.9 x 5.1x 4.1cm, which is highly suggestive of pancreatic carcinoma. Multiple hypo dense necrotic areas were also identified in both the lobes of the liver suggestive of metastatic deposits. (Figure-2). Biopsy of the pancreatic lesion was planned but the family refused.

## Discussion

As stated earlier, pancreatic cancer is one of the most deadly cancers in the world, and in the US it is the fourth leading cause of cancer related deaths.<sup>1</sup> At the time of diagnosis, more than 80% of the patients with pancreatic cancer have distant metastasis along with unresectable primary tumour.<sup>3</sup> Among the diagnosed patients of pancreatic carcinoma, 74% of patients could not survive for more than a year, whereas 94% of them die within five years of their diagnosis. Therefore, their relative survival rate is lowest among all cancers.<sup>4</sup> Patients' survival from the time of presentation is usually very short and one-year survival rate is not greater than 20%, whereas six-month survival rate is not greater than 50%.<sup>5</sup>

Most of the patients with pancreatic carcinoma present with abdominal pain (usually upper abdomen), jaundice, anorexia and unexplained weight loss. However, in later or advanced stages of the disease, the patient can present with signs and symptoms of involvement of other organs because of metastases, along with typical abdominal symptoms.

Patients with pancreatic carcinoma usually present to clinicians when they have either locally advanced disease or distant metastasis. Pancreatic carcinoma most frequently metastasise in the liver (62%), lungs (55%) and bones (25%).<sup>6</sup>

As stated earlier, most common presentation of pancreatic carcinoma is abdominal pain (70 to 80%), followed by weight loss and anorexia (20%), and the most common sign is jaundice and/or hepatomegaly (up to 80%).<sup>7,8</sup> Most of the clinicians only suspect pancreatic carcinoma when the elderly patients present with abdominal pain, anorexia, weight loss and jaundice but those patients who present with signs and symptoms of involvement of other organs due to distant metastasis are often missed by the physicians; for example, when a

patient presents with respiratory symptoms or lymph node enlargement, etc.

Although, it is uncommon that pancreatic carcinoma presents with respiratory symptoms but cases have been reported in literature where pancreatic carcinoma presented with cough, dyspnoea and haemoptysis.<sup>7,9,10</sup> One study reported up to 50% lung metastasis in patients with metastatic pancreatic carcinoma.<sup>6</sup> Our case had unusual presenting symptoms as she developed respiratory complaints of cough and shortness of breath without any typical abdominal symptoms, which obscured the diagnosis of pancreatic carcinoma.

Family history of our patient was positive for pulmonary tuberculosis and chest x-ray showed bilateral, small, multiple nodules typical of miliary pattern; hence, miliary tuberculosis was suspected. HRCT of the chest revealed bilateral diffuse pulmonary nodule which is more suggestive of pulmonary metastases, which was a reason for performing a CT abdomen with contrast to search for primary malignancy and which revealed pancreatic carcinoma. Although histopathological confirmation of pancreatic carcinoma could not be done because of the refusal of the family, findings of CT of the abdomen were highly suggestive to confirm the diagnosis.

## Conclusion

Advanced pancreatic malignancy with pulmonary metastasis usually present with respiratory complaints, such as cough, shortness of breath and haemoptysis along with typical abdominal symptoms but it is rare that they present only with respiratory symptoms. We conclude that metastatic pancreatic carcinoma should be considered when any elderly patient presents with respiratory symptoms and metastatic findings on chest imaging.

**Informed Consent:** Informed written consent was taken from the patient's son to publish the case.

**Disclaimer:** None

**Conflict of Interest:** None

**Funding Sources:** None

## Reference

1. Siegel RL, Miller KD, Jemal A. Cancer statistics, 2018. *CA Cancer J Clin* 2018;68:7-30. doi: 10.3322/caac.21442.
2. Dragovich T. Pancreatic Cancer. [Online] 2020 [Cited 2020 January 31]. Available from URL: <https://emedicine.medscape.com/article/280605-overview>
3. Howlader N, Noone AM, Krapcho M, Neyman N, Aminou R,

- Waldron W, et al, eds. SEER Cancer Statistics Review, 1975-2009 (Vintage 2009 Populations). Bethesda, MD: National Cancer Institute; 2012.
4. Kaur S, Baine MJ, Jain M, Sasson AR, Batra SK. Early diagnosis of pancreatic cancer: challenges and new developments. *Biomark Med* 2012;6:597-612. doi: 10.2217/bmm.12.69.
  5. Cooperman AM. Pancreatic cancer: the bigger picture. *Surg Clin North Am* 2001;81:557-74. doi: 10.1016/s0039-6109(05)70143-2.
  6. Kamisawa T, Isawa T, Koike M, Tsuruta K, Okamoto A. Hematogenous metastases of pancreatic ductal carcinoma. *Pancreas* 1995;11:345-9. doi: 10.1097/00006676-199511000-00005.
  7. Richwine RT, Ahmed N, Mortensen M. Cough as the presenting symptom of pancreatic adenocarcinoma. *J Am Board Fam Pract* 2004;17:48-53. doi: 10.3122/jabfm.17.1.48.
  8. Barkin JS, Goldstein JA. Diagnostic approach to pancreatic cancer. *Gastroenterol Clin North Am* 1999;28:709-22. doi: 10.1016/s0889-8553(05)70083-2.
  9. Okabe T, Vranken LV, Seril DN. Hemoptysis as a Presenting Symptom for Metastatic Pancreatic Cancer. *The Medicine Forum* 2008;10:61-4. doi: 10.29046/TMF.010.1.027
  10. Cassiere SG, McLain DA, Emory WB, Hatch HB Jr. Metastatic carcinoma of the pancreas simulating primary bronchogenic carcinoma. *Cancer* 1980;46:2319-21. doi: 10.1002/1097-0142(19801115)46:10<2319::aid-cnrcr2820461033>3.0.co;2-z
-