

## Gastric volvulus in adults in a tertiary care hospital Karachi, Pakistan: A case series

Om Parkash,<sup>1</sup> Roger Christopher Gill,<sup>2</sup> Iman Qaiser,<sup>3</sup> Muhammad Sharoz Rabbani,<sup>4</sup> Tabish Chawala,<sup>5</sup> Hasnain Zafar<sup>6</sup>

### Abstract

Gastric volvulus is a rare surgical emergency which is rare in children and occasionally presents in adults. It results due to pathological malrotation of the stomach along its longitudinal or short axis. The condition, if not treated promptly, can result in increased morbidity and carries a high risk of death. Very few cases have been reported in literature regards this important clinical condition. Early decompression and repair of anatomical defects are the corner stone of its management. There is a dire need to develop guidelines and algorithms for management and treatment of this rare condition to improve patient outcome, prevent recurrence and facilitate early diagnosis by practicing physicians and surgeons. We report three such cases which presented to our setup in emergency along with a brief description of how they were successfully managed.

**Keywords:** Gastric Volvulus, Malrotation, Vomiting, Hiatal Hernia.

**DOI:** <https://doi.org/10.47391/JPMA.386>

### Introduction

Gastric Volvulus is a rare surgical emergency which results from a pathological rotation of the stomach of more than 180 degree around its longitudinal or short axis.<sup>1,2</sup> Primary gastric volvulus is a result of weak gastric support, while secondary volvulus is caused by any upset in anatomy or functioning of the stomach or its neighbouring viscera.<sup>3,4</sup> Besides the aforementioned subtype, gastric volvulus is also classified on the basis of time of presentation and axis of rotation.<sup>5</sup> To date 12 cases of gastric volvulus have been reported in our country.<sup>4,6,7</sup> Each of these cases belonged to the paediatric age group which is usually thought to be the norm. Although, its presentation in adults is scarce, we present a case series of three adult patients with gastric volvulus who presented to the Aga Khan University Hospital during the year 2016 and 2018.

### Case 1

A 95-year-old lady presented to the emergency department with complaints of vomiting and

.....  
<sup>1</sup>Department of Medicine, <sup>2,3,5,6</sup>Aga Khan University, Karachi, Pakistan, <sup>4</sup>Final Year Student, Southend University Hospital NHS Foundation Trust, United Kingdom. **Correspondence:** Om Parkash. Email: om.parkash@aku.edu

constipation for three days and raised blood pressure for one day. She had coffee ground vomitus. Other symptoms such as abdominal pain, jaundice or fever were not reported. She had a history of Deep Vein Thrombosis. She underwent endoscopy which revealed pan gastric erythema with retained gastric secretion of approximately 750 ml which was aspirated to relieve her symptoms. At presentation, she was taking Domperidone and Proton pump inhibitor prescribed by a local doctor. She was allergic to Penicillin and had no comorbidities or any family history of clinically significant diseases.

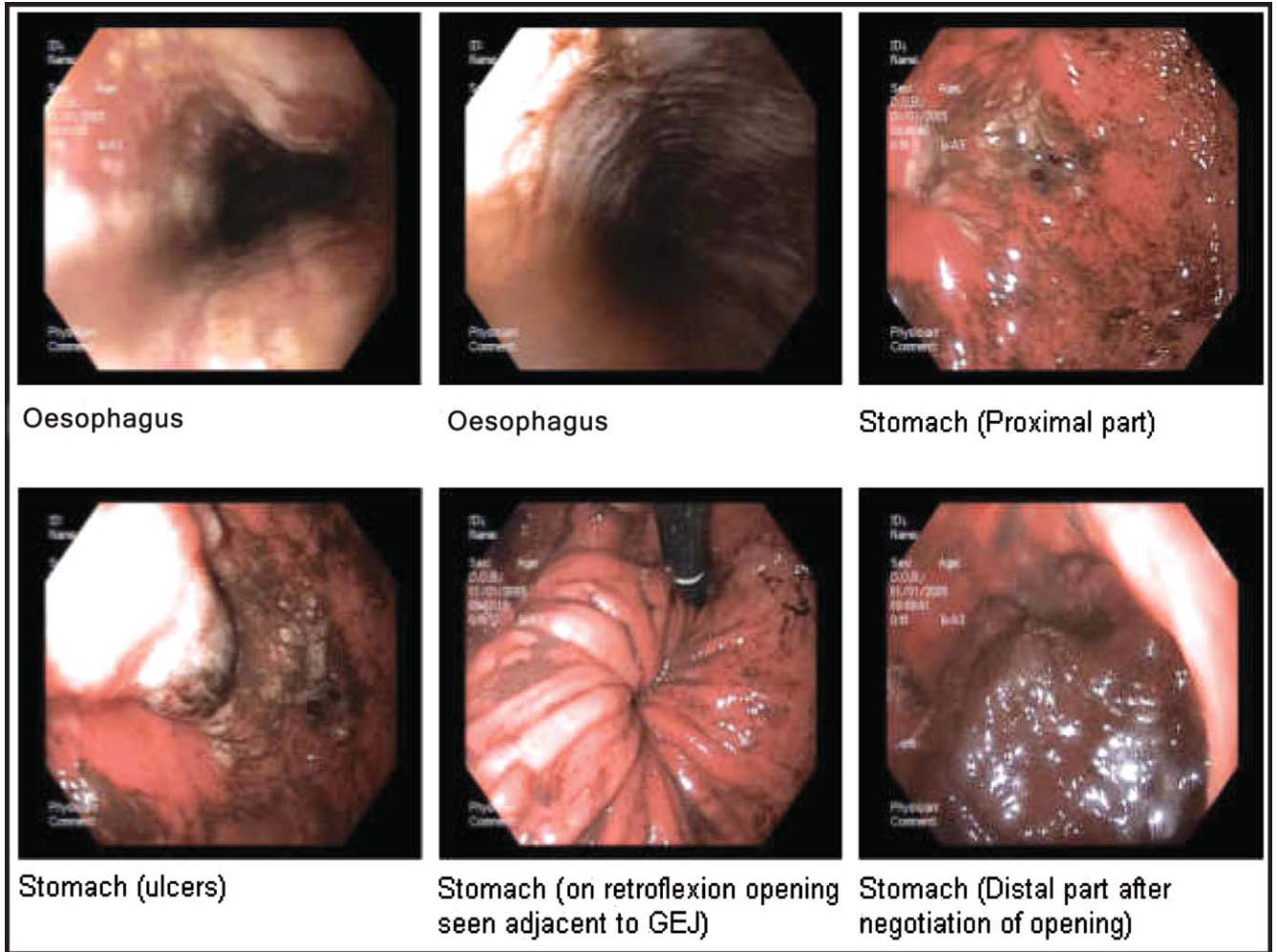
On examination, her blood pressure was raised around 158/125 mm of Hg, while on abdominal examination, gut sounds were sluggish, and she had non-tender abdomen. For evaluation of acute abdomen, she underwent blood work up which revealed raised total leucocyte count, while the rest of the work up, including ultrasound of the abdomen, was unremarkable. Based on strong suspicion, Computerized tomography (CT) scan of the abdomen was ordered which revealed a displaced gastro-esophageal junction (GEJ) above the diaphragm with antrum and pylorus lying superior to the fundus.

The proximal body of the stomach was pushed up into the thoracic cavity and no evidence of necrosis was found. Finally, diagnosis of Mesentero-axial gastric volvulus and hiatal hernia was made. She was taken for an emergency decompression procedure and underwent mini laparotomy. Her stomach was de-rotated and gastropexy was performed and the hernia reduced into the abdominal cavity without any fundoplication. Postoperatively she recovered very well and was discharged within a week. Her subsequent follow up at 10 months was uneventful.

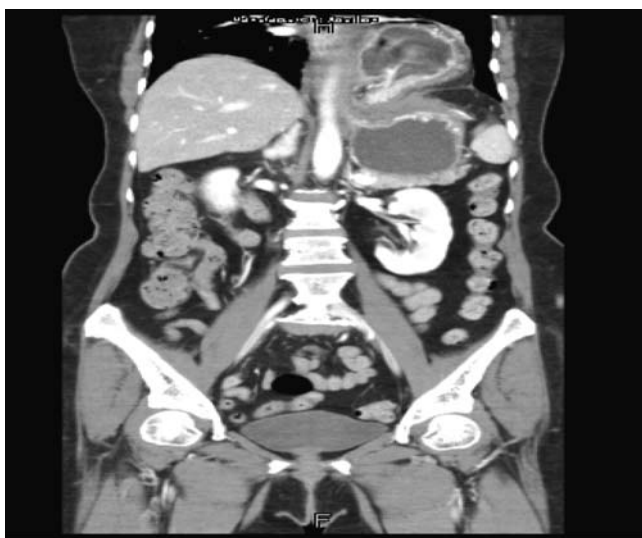### Case 2

A 53-year-old lady presented to the gastroenterology clinic with complaints of epigastric burning and vomiting for a week. There was obstipation and she had been experiencing occasional episodes of abdominal pain, nausea and vomiting for almost a year. The woman did not have any comorbidity and her medical and surgical history were insignificant. So was her family and psychosocial history.

On examination she was afebrile and vitally stable. Her

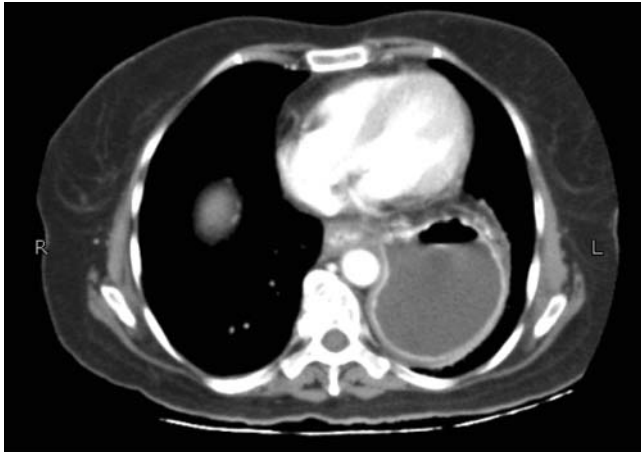


**Figure-1:** EGD images showing severe ulcerative oesophagitis and a high possibility of gastric volvulus in the retroflexed view as shown.



**Figure-2:** CT scan sagittal view showing Para-oesophageal hernia with Mesentero-axial gastric volvulus.

general physical, abdominal and cardio-pulmonary examinations were within normal limits. A provisional diagnosis of dyspepsia was made and an Esophagogastroduodenoscopy (EGD) was planned to rule out gastritis and other abnormalities. Endoscopic examination revealed severe ulcerative oesophagitis and a blind cavity on insufflation of air. Retro-flexion of the scope showed an opening with ulcerated margins adjacent to the gastroesophageal junction (Figure-1). The scope could not be negotiated beyond the body and antrum of the stomach and it was filled with liquid content. A diagnosis of gastric volvulus with possibility of hiatal hernia was made and the patient was admitted. Her blood workup was sent which revealed a Total Leucocyte Count of around 15.5 with neutrophils at 91.7% and lymphocytes at 4.7%, while the rest of the work up was unremarkable. CT scan revealed a left sided para-oesophageal hernia with herniation of antrum and part of the gastric body. Antrum of the stomach was found to be



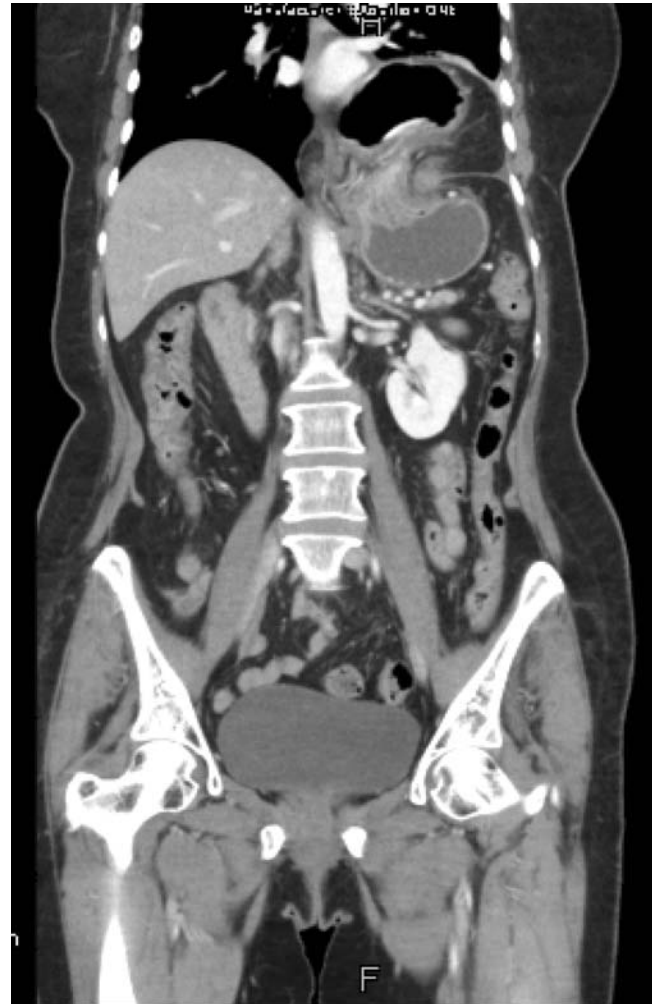**Figure-3:** Contrast enhanced CT scan Cross-sectional view showing stomach lying within the left thoracic cavity without any evidence of pneumatosis in the stomach wall. The stomach lumen is filled with high density material and the walls show adequate enhancement.

lying superior to the gastroesophageal junction while fundus was lying inferiorly (Figure-2). The findings were suggestive of mesenteroaxial gastric volvulus without any evidence of necrosis or pneumatosis (Figure-3).

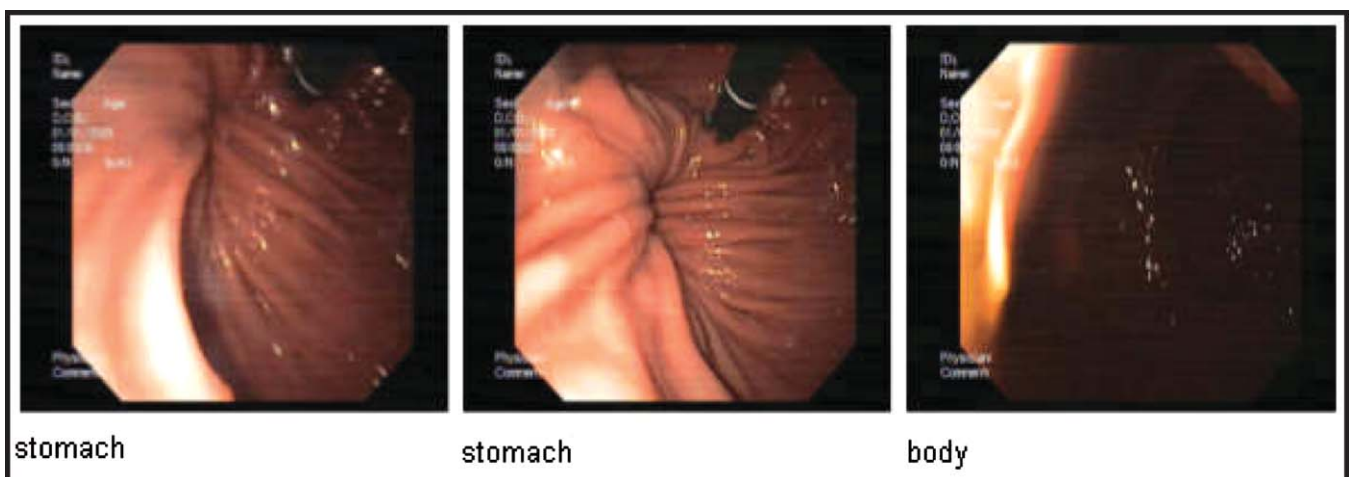
The surgical team was taken on board. The patient underwent laparotomy with para-oesophageal hernia repair and Nissen's fundoplication along with gastropexy. She recovered uneventfully, got discharged after four days and did well till the last follow up five months later.

### Case 3

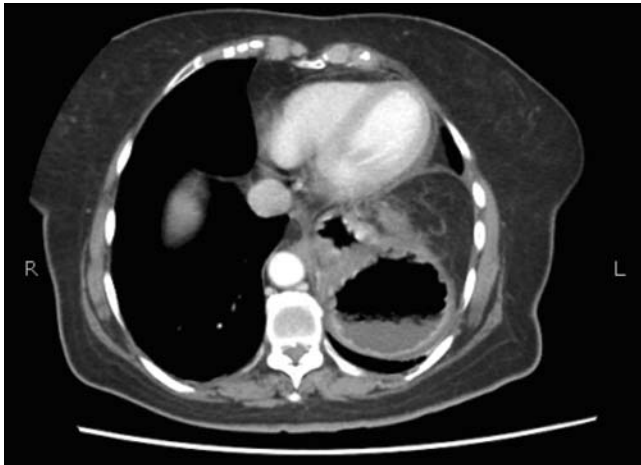A 62-years-old lady a known case of diabetes, hypertension and dyslipidaemia presented to the ER with complaint of vomiting in the past 15 days. Prior to this she had been feeling postprandial fullness for last two



**Figure-5:** CT scan chest abdomen and pelvis sagittal view showing a large 5cm defect in the left hemidiaphragm with a para-oesophageal hernia. Also seen is rotation of the stomach along its long axis with fundus lying in subdiaphragmatic location.



**Figure-4:** EGD showing parallel opening alongside of the GE junction raising the possibility of Gastric Volvulus / Para-oesophageal Hernia.



**Figure-6:** CT Scan Cross-sectional image showing the stomach in the left chest cavity.

months. There were no associated symptoms and her review of symptoms was impartial. She was taking Glucophage, Statin, Proton pump inhibitor and Angiotensin receptor blocker for her medical conditions.

On examination she was vitally stable and afebrile. Her physical examination was unremarkable and there was epigastric tenderness on deep palpation. An EGD was performed the next day, which showed a parallel stomach body opening containing food residues (Figure-4). The scope could not be negotiated through the duodenum. CT findings exhibited a large 5.5cm defect in the left hemi-diaphragm with a para-oesophageal hernia. Her stomach was rotated along its long axis and its body extended to hemi-thorax with surrounding free fluid (Figure-5). The fundus of the stomach was sub-diaphragmatic. A diagnosis of organoaxial gastric volvulus and type III hiatal hernia was made (Figure-6). She underwent laparotomy with hiatal hernia repair along with Nissen's fundoplication. Anterior gastropexy was done to fix the rotated stomach. Her recovery was uneventful and follow up visits were unremarkable up-to one year.

## Discussion

Gastric volvulus is a rare medical entity with roughly a thousand cases reported in literature till date. Its uniqueness attributes to its diverse classification schemes. Broadly it can be defined as acute if presenting with sudden onset or chronic if presenting with intermittent symptoms.<sup>6</sup> It has also been defined according to the cause of gastric de-rotation. A weakness in gastric anatomical support is referred to as primary volvulus, whereas pathologies like diaphragmatic hernia, tumour and malrotation leads to secondary gastric volvulus. On the basis of the axis of rotation gastric

volvulus can be divided into Mesenteroaxial or Organoaxial gastric volvulus.<sup>1,2</sup> Other, lesser known classifications of gastric volvulus have also been described by Anzilotti, Borchardt, Neumann, Thorek and Bazzano, in medical literature.<sup>8-12</sup>

Different subtypes have their own prevalence rates. For instance, based on the aetiology, secondary gastric volvulus are more common; whereas according to distribution on axis of rotation, Organoaxial are found to be more common.<sup>9,13</sup> There is no predilection of gender with incidence of gastric volvulus.<sup>10</sup> The peak incidence occurs in the fifth decade of life, and 20% of the patients comprise children less than one year of age and are often secondary to congenital diaphragmatic defects.<sup>14</sup>

The presenting symptoms due to gastric volvulus depend upon the degree of rotation, degree of obstruction and position of the stomach, i.e. type of volvulus. It presents with a triad of symptoms (epigastric pain, retching and inability to pass NG tube) known as Borchardt's triad seen in 70% of adult population who present with gastric volvulus.<sup>8,9,11</sup> Paediatric population symptoms differ from adults in their presentation. A literature review from Pakistan by Mirza and colleagues revealed the presence of Borchardt's triad in 50% of paediatric population.<sup>3</sup> Conversely, none of our patients had the typical features of Borchardt's triad, though two or three of the above-mentioned symptoms had been present. Gastric volvulus associated with hernia may present with symptoms such as epigastric burning, vomiting and hematemesis.<sup>1</sup> Epigastric burning and vomiting were universal symptoms in all our cases. A total of 12 cases have been affirmed from our country so far, all being paediatric and none above eight years of age. Astonishingly all three of our cases were adults. Only one of them was in her fifth decade of life which is the common age for incidence of gastric volvulus. All our cases presented with diaphragmatic hernias; two of them had hiatal hernia, while one had para-oesophageal hernia, all secondary to anatomical defect. The statement that secondary gastric volvulus are more common than primary ones is reflected in our cases.<sup>12</sup> Contrary to the aforesaid evidence, Darani and colleagues have reported primary gastric volvulus cases to be more common as compared to secondary.<sup>11</sup> Gourgiotis's published a 10-year experience with these cases and demonstrated that 80% of them are actually secondary gastric volvulus with age range over 60 years.<sup>1</sup> A common predisposing factor in 76% of his patients was diaphragmatic hernia. This relationship was like that found in our three patients. Some studies have described gastric volvulus as an advanced form of diaphragmatic hernia.<sup>13</sup> In these studies, all patients exhibited gastric volvulus resulting secondary

to diaphragmatic hernias. We hypothesise the link between increased age and weakening of muscles leading to diaphragmatic hernias and hence secondary gastric volvulus. Contrary to the previous case series, our cases depict more Mesenteroaxial gastric volvulus than Organoaxial Volvulus.<sup>9,11,15</sup> This finding can be a result of small number of our patient population. Another remarkable finding by Gourgiotis was the association between para-oesophageal hiatus hernia and Organoaxial gastric volvulus.<sup>1</sup> Unfortunately, we had just one patient with Organoaxial gastric volvulus to further consolidate this relationship.

Modalities used for diagnosis of gastric volvulus range from simple X-ray to contrast enhanced CT scans. Despite a vast range of diagnostic means, barium meal study has showed the highest (81%) yield in establishing diagnosis. Barium study has also been supported by other studies as a reliable test for making diagnosis of gastric volvulus.<sup>4,9,16</sup> Upper GI endoscopy yielded diagnosis in 71% cases of gastric volvulus as shown in a study by Gourgiotis.<sup>1</sup> Despite a lower yield (40%) by Gourgiotis, all our diagnoses were eventually confirmed by contrast enhanced CT scans. Though we were not able to confirm the diagnosis of gastric volvulus strictly based on the scope examination it however did raise suspicion for this condition. Thus, it did serve as an important adjunct to direct further imaging for establishing our diagnosis. Once the diagnosis of gastric volvulus is made, treatment should be immediate and this may range from simple gastric de-rotation to total gastrectomy.<sup>3,6</sup> Nasogastric tube is used acutely to decompress the stomach.<sup>4</sup> Post decompression of the stomach, repair of the inflicting entity (like repair of hernia) is done. To prevent recurrence, gastropexy and fundoplication are carried out.<sup>14</sup> We performed gastropexy in all and Nissen Fundoplication in two patients of these patients to prevent any recurrence of gastric volvulus.

## Conclusion

Gastric volvulus is a rare anomaly, which can prove lethal if not aptly diagnosed and treated. Investigations like barium meal study and CT scan prove beneficial for diagnostic purposes. Early decompression and repair of anatomical defects are the corner stone of its

management. There is a dire need to develop guidelines and algorithms for management and treatment of this rare condition which will improve patient outcome, prevent recurrence, and facilitate early diagnosis by practicing physicians and surgeons.

**Disclaimer:** None to declare.

**Conflict of Interest:** None to declare.

**Funding Sources:** None to declare.

## References

- Gourgiotis S, Vougas V, Germanos S, Baratsis S. Acute gastric volvulus: diagnosis and management over 10 years. *Dig Surg.* 2006; 23:169-72.
- Teague W, Ackroyd R, Watson D. Changing patterns in the management of gastric volvulus over 14 years. *Br J Surg.* 2000; 87:358-61.
- Mirza B, Ijaz L, Sheikh A. Gastric volvulus in children: our experience. *Indian J Gastroenterol.* 2012; 31:258-62.
- Rashid F, Thangarajah T, Mulvey D, Larvin M, Iftikhar S. A review article on gastric volvulus: a challenge to diagnosis and management. *Int J Surg.* 2010; 8:18-24.
- Karthikeyan VS, Sistla SC, Ram D, Rajkumar N. Gastric volvulus following diagnostic upper gastrointestinal endoscopy: a rare complication. *BMJ Case Rep.* 2014; 2014:bcr2013202833.
- Kayastha K, Sheikh A. Acute gastric volvulus secondary to malrotation of gut in a child with cerebral palsy. *APSP J Case Rep.* 2011; 2:12.
- Mirza B, Ijaz L, Qureshi A, Sheikh A. Massive air shadow in the abdomen. *Saudi J Gastroenterol.* 2010; 16:239-40.
- Chau B, Dufel S. Gastric volvulus. *Emerg Med.* 2007; 24:446-7.
- Cribbs RK, Gow KW, Wulkan ML. Gastric volvulus in infants and children. *Pediatrics.* 2008; 122:e752-e62.
- McElreath DP, Olden KW, Aduli F. Hiccups: a subtle sign in the clinical diagnosis of gastric volvulus and a review of the literature. *Digest Dis Sci.* 2008; 53:3033-6.
- Darani A, Sagaon MM, Reinberg O. Gastric volvulus in children. *J Pediatr Surg.* 2005; 40:855-8.
- Joshi M, Parelkar S, Sanghvi B, Agrawal A, Mishra P, Pradeep S. Gastric volvulus in children: experience of 6 years at a tertiary care centre. *Afr J Paediatr Surg.* 2010; 7:2-4.
- Landreneau RJ, Del Pino M, Santos R. Management of paraesophageal hernias. *Surg Clin North Am.* 2005; 85:411-32.
- Kshirsagar AY, Shinde S, Ahire M, Langade Y. Congenital paraesophageal hiatus hernia with gastric volvulus. *J Indian Assoc Pediatr Surg.* 2008; 13:36-7.
- Ayala JA, Mathuria NB, Olutoye OO. Delayed presentation of congenital diaphragmatic hernia manifesting as combined-type acute gastric volvulus: a case report and review of the literature. *J Pediatr Surg.* 2008; 43:e35-e9.
- Cardile AP, Heppner DS. Gastric volvulus, Borchardt's triad, and endoscopy: a rare twist. *Hawaii Med J.* 2011; 70:80-2.