

## Incidence of endophthalmitis following intravitreal anti VEGF injections at a tertiary care hospital in Pakistan

Fiza Shaheen,<sup>1</sup> Muhammad Amer Awan,<sup>2</sup> Aiman Hafeez,<sup>3</sup> Aqduus Haq,<sup>4</sup> Ramsha Zainab Malik<sup>5</sup>

### Abstract

**Objective:** To assess the rate of infectious endophthalmitis with anti-vascular endothelial growth factor injection, and to evaluate institutional procedure protocol in this regard.

**Methods:** The retrospective consecutive case series was conducted at Shifa International Hospital, Islamabad, Pakistan, from August 2018 to January 2019, and comprised 5-year data from August 2014 to July 2019 related to patients who underwent intravitreal anti-vascular endothelial growth factor injections. Data was analysed using SPSS 21.

**Results:** Of the 7,542 injections administered to 2,734 patients, 5,976(79.2%) were bevacizumab, 1,081(14.3%) ranibizumab and 485(6.4%) aflibercept. There was 1(0.01%) case of infectious endophthalmitis which was treated with 25 gauge pars plana vitrectomy.

**Conclusion:** The institutional procedure protocol was found to be effective as the rate of infectious endophthalmitis was lower than what is reported in literature.

**Keywords:** Bevacizumab, Endophthalmitis, Intravitreal injections, Ranibizumab, Sterilisation. (JPMA 71: 1184; 2021)

**DOI:** <https://doi.org/10.47391/JPMA.212>

### Introduction

Retinal hypoxia occurs in various ocular pathologies, including diabetic retinopathy (DR), wet-type age-related macular degeneration (AMD), retinal vein occlusion (RVO), retinopathy of prematurity (ROP) and ischaemic vasculitis leading to over-expression of a pro angiogenic cytokine called vascular endothelial growth factor (VEGF) which causes pathological angiogenesis. This in turn leads to visual deterioration because of retinal oedema, haemorrhage and fibro-vascular proliferation.<sup>1</sup>

Use of anti-VEGF injections into the vitreous cavity has now become a commonly performed ophthalmic procedure that has helped in the halting of the above-mentioned disease processes. Agents used for the purpose are ranibizumab, bevacizumab and aflibercept.

However, the use of these injections is associated with a risk of certain complications among which infectious endophthalmitis (IE) is the most serious one.<sup>2</sup> It is most commonly caused by bacteria<sup>3</sup> along with the flora of ocular surface and the adnexa. Media and instruments utilised during the procedure are considered also a potential source of IE.<sup>4</sup>

A retrospective study reported IE rate of 0.029% per

.....  
<sup>1,3-5</sup>Department of Ophthalmology, <sup>2</sup>Department of Vitreoretinal Surgery, Shifa International Hospital, Islamabad, Pakistan.

**Correspondence:** Muhammad Amer Awan. Email: [dramer\\_awan@yahoo.co.uk](mailto:dramer_awan@yahoo.co.uk)

injection.<sup>4</sup> Another study reported it to be 0.019%.<sup>5</sup> A local study reported it to be 0.027%.<sup>6</sup>

Despite the evidence, there are significant variations and a lack of consensus in clinical practice in each setup.<sup>4</sup>

The current study was planned to explore the post anti-VEGF injection rate of IE in a clean room in an hospital setting, and to compare the institutional procedure protocol in this regard with those being practised elsewhere.

### Patients and Methods

The retrospective consecutive case series was conducted at the Ophthalmology Department of Shifa International Hospital, Islamabad, Pakistan, from August 2018 to January 2019. After approval from the institutional ethics review committee, data related to patients who received intravitreal (IVT) anti-VEGF injections between August 2015 and July 2018 was collected, including demographics, co-morbidities, laterality, indication, name of the injection and the occurrence of post-injection IE. The patients were followed up for 4 weeks post-injection. Medical records of patients showing post-injection IE were further reviewed regarding the management, including IVT antibiotics, culture report, and pars plana vitrectomy surgery, and further complications, including raised intra-ocular pressure (IOP), retinal detachment and phthisis bulbi. Patients were labelled as having IE on the development of hypopyon and IVT inflammation within

4 weeks of the injection and requiring IVT antibiotics.<sup>2</sup> Data of patients who developed IE secondary to any other known aetiology during the 4 weeks post-injection was excluded.

Three types of anti-VEGF injections were used, including bevacizumab (Avastin) 1.25mg/0.05ml, ranibizumab (Patizra/ Lucentis) 0.5mg/0.05ml and aflibercept (Eylea) 2mg/0.05ml. They were administered for a variety of disorders by 5 ophthalmologists following the same pre- and post-injection protocols.

The patients were prepared for the injection after taking written informed consent. The affected eye of the patient was then marked with the skin marker after rechecking the progress notes. Eye of the patient was then instilled with topical anaesthetic proparacaine hydrochloride 0.5% (Alcaine) eye drops and moxifloxacin (Vigamox) eye drops briefly before shifting the patient to a clean room in a clinic-based setting at the ophthalmology clinic. The patient was made to wear a surgical cap and shoe covers before entry into the clean room.

Air filtration system was well maintained in the room. A new sterilised set, consisting of an eye drape, eye speculum, surgical solution bowl, kidney dish, sponge holder, tooth forceps, surgical gauzes and vernier callipers, was opened upon the arrival of each patient in the operating room by the staff nurse after sterilising her hands. The patient was asked to lie on the operating table. The surgeon did the recommended 2-minute scrubbing with povidone iodine 7.5% surgical scrub solution and donned the surgical gloves. All the surgeons wore the face mask.

Before applying the 5% diluted povidone solution over the marked eye of the patient, time out by the staff nurse was performed to confirm diagnosis, eye and type of the injection. Povidone was applied for a period of 1 minute followed by its cleaning and application of eye drape and eye speculum. Further, 1% lignocaine and 5% povidone were applied over the conjunctiva at the site of injection. Anti-VEGF injections were given at 3.5mm from limbus in pseudophakic eyes and 4mm in phakic eyes. All the injections were injected with a 30 gauge needle. The procedure was finished with one drop of moxifloxacin antibiotic instillation and speculum removal.

The patient was prescribed topical moxifloxacin 4 times daily for 5 days with the instruction to avoid water instillation in the eye for 3 days.

The post-injection IE diagnosis was made by the treating

ophthalmologist and it was managed accordingly.

The Primary outcome measure was IE incidence, while the secondary outcome was sterile inflammation or traumatic cataract.

Data was analysed using SPSS 21.

## Results

A total of 7,542 injections were administered to 2,734 patients; 1403 (51.3%) males and 1331(48.7%) females. The overall mean age was 61.14±13.22 years. Diabetic macular oedema (DME) was the most common indication 1,312(48%) followed by wet-AMD 741(27.2%) and retinal vein occlusion 176(20.7) (Table-1). Of all the injections administered, 5,976(79.2%) were bevacizumab, 1,081(14.3%) ranibizumab and 485(6.4%) were aflibercept (Figure). There was 1(0.01%) case of IE, while no patient developed sterile inflammation or traumatic cataract (0%).

The lone IE case was aged 65 years diabetic woman who presented on the third post-injection day. She had been given bevacizumab for DME in the left eye. She reported

**Table-1:** Demographics and indications of intravitreal injections.

Characteristics	
<b>Age</b>	
Mean	61.14y (13.22SD)
Range	1-89y
<b>Gender</b>	
Male	1403 (51.3%)
Female	1331 (48.7%)
<b>Co-morbid</b>	
Diabetes Mellitus	833 (30.5%)
Hypertension	366 (13.4%)
Both	1104 (40.4%)
Ischaemic heart disease	60 (2.2%)
Others	371(13.6%)
<b>Laterality</b>	
Left	820 (30%)
Right	902 (33%)
Both	1011 (37%)
<b>Indications</b>	
DME	1312 (48%)
Wet AMD	741 (27.2%)
CRVO	176 (6.4%)
BRVO	391 (14.3%)
Vitreous Haemorrhage	35 (1.3%)
Pre Vitrectomy	6 (0.2%)
ROP	6 (0.2%)
Myopic CNV	67 (2.4%)

SD: Standard deviation, DME: Diabetic macular oedema, AMD: Age-related macular degeneration, CRVO: Central retinal vein occlusion, BRVO: Branch retinal vein occlusion, ROP: Retinopathy of prematurity, CNV: Choroidal neovascularisation.

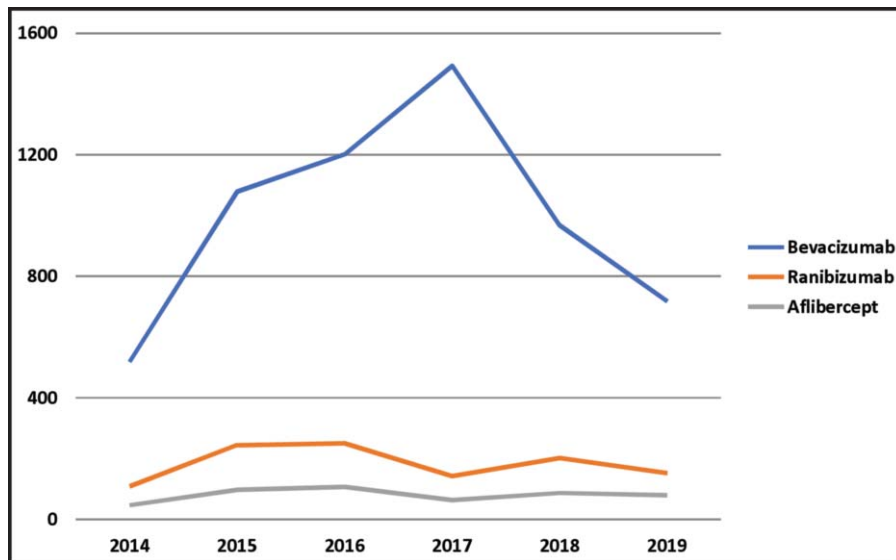


Figure: Type of injections along with its number injected each year from July 2014 to August 2019.

Table-2: Comparison of infectious endophthalmitis (IE) incidence rate among various studies along with sample size and injection setting.

Study with year of publication	Sample size	Incidence of IE	Setting
Pilli et al, <sup>9</sup> 2008	10,254	0.029%	Office room
Lyall et al, <sup>8</sup> 2012	186,972	0.025	Both
Mithal et al, <sup>10</sup> 2013	15,925	0.165	Both
Brynskov et al, <sup>11</sup> 2014	20,293	0.03%	Operative room
Nentwich et al, <sup>12</sup> 2014	20,173	0%	Operative room
Dossarps et al, <sup>2</sup> 2015	316,576	0.021%	Operative room
Haider et al, <sup>13</sup> 2017	1,047	0.19%	Office based clean room
Sarah et al, <sup>6</sup> 2018	11,128	0.028%	Operative room

sudden onset of pain, redness and loss of vision. On examination, her visual acuity (VA) was projection of light. There was anterior chamber reaction in the form of hypopyon 3mm with extensive fibrin and poor fundal view. She underwent pars plana vitrectomy with IVT antibiotic injections ceftazidime 2mg/0.1ml and vancomycin 1mg/0.1ml. Her vitreous culture report did not show any growth. The VA improved to 0.1 logarithm of the minimum angle of resolution (logMAR) at 3-month follow-up.

**Discussion**

With increasing knowledge about disease pathophysiology and refinements in pharmaceutical departments, indications of anti-VEGF injections have multiplied during the last few years so much that it is now considered a routine procedure in the ophthalmology departments of hospitals worldwide.

However, like every intraocular procedure, it also carries a certain risk of IE. The three largest meta-analysis have reported the incidence to be 0.025%, 0.056% and 0.021%<sup>2,7,8</sup> and a local study reported it to be 0.028%.<sup>6</sup> The post-injection IE rate in the current study was 0.01% which is lower than most studies<sup>2,6,8-13</sup> (Table-2). Four of such studies<sup>2,6,11,12</sup> specifically evaluated the IE risk with IVT injection in the operating room (OR) and reported it to be 0.03%, 0%, 0.021% and 0.028% which is close to the reported findings of 0.029% and 0.19% by studies conducted in clinic-based setups only.<sup>9,13</sup> Studies including both the setups<sup>8,10</sup> have reported it to

be 0.025% and 0.165%.

Even with considerable evidence, there is an absence of an integrated protocol for the delivery of these injections. Injection setting, use of physical barriers and prophylactic topical antibiotics is still a debatable topic.<sup>14</sup>

With growing indications, the procedure has shifted from surgical OR setting to a clinic-based setting in a number of hospitals.<sup>15-20</sup> Although a study reported no difference in the IE incidence between the two settings in a comparative study,<sup>21</sup> the superiority of a clinic-based setup over a surgical OR setting cannot be denied in terms of logistics and time. Locally, however, this is not yet widely practiced, especially because of deleterious conditions and low follow-ups.<sup>6</sup>

Only two local studies have assessed the IE rate with anti-VEGF injections.<sup>6,13</sup> One highlighted the safety of injection delivery in surgical OR setting, reporting it to be 0.027%,<sup>6</sup> while the other was carried out in a clinic-based setup and reported IE incidence to be 0.19%.<sup>13</sup> However, the latter study was limited by the use of only one specific type of anti-VEGF and a small sample size.<sup>13</sup> The current study had 7,542 injections and an IE incidence of 0.01% in a clinic-based clean room setting following standard sterilisation protocols. It is comparable to the IE rates reported in studies conducted worldwide in a clinic-based setting which is 0.029%.<sup>18</sup>

The current study also highlights the significance of the use of physical barriers in preventing IE. Facemask was worn by all the surgeons to protect against the oral and

nasal flora and its importance has been highlighted previously.<sup>22</sup> A sterile drape along with an eye speculum was used on the patients to provide protection against the patient's own eyelid flora, and that has been indicated earlier.<sup>23</sup> These barriers were found to be valuable in preventing IE in contrast to a study which reported the omission of sterile drape and eye speculum having no role in the prevention of IE.<sup>4</sup>

The current study used post-injection topical antibiotic in all the patients. Even though the only proven prophylaxis is povidone iodine,<sup>24</sup> we cannot comment if the use of antibiotics is unnecessary in the Pakistani context.

None of the patients in the current study had a bilateral same-day IVT injection. This practice is avoided by all the ophthalmologists in the study even though the proven incidence is relatively low.<sup>25</sup> This is because we think that it is unjustified to put the patient at the risk of bilateral IE than a unilateral one. Considering the results, we suggest that the practice of same-day bilateral IVT injections should be discouraged.

In the study protocol, all the four compartments of the eyeball were equally utilised for giving the injection. No relation was found of IE with any specific ocular compartment in contrast to a previous study which reported a preference for infero-temporal compartment, claiming it to be linked with a relatively low risk of IE.<sup>4</sup>

To our knowledge, the current study is the first to be reporting the incidence of infectious IE with anti-VEGF injections in a clinic-based clean room setting from southeast Asia with the inclusion of all the three types of anti-VEGF injections and a relatively large sample size.

However, the current study has limitations, including its retrospective nature and the absence of a control group. Also, with five different ophthalmologists, minor intraoperative details might have been lost. A larger prospective study should be conducted to assess the rate of IE.

## Conclusion

Even in a third world country where poor hygiene is a major concern, IVT injections can be administered safely in a clinic-based setting while following standardised sterilisation protocols. This will not only save time but is also likely to be economical.

**Disclaimer:** The study was presented at the 38th Lahore Ophthalmological Conference, held in December 2019 in Lahore, Pakistan.

**Conflict of Interest:** None.

**Source of Funding:** None.

## References

1. Al-Latayfeh M, Silva PS, Sun JK, Aiello LP. Antiangiogenic therapy for ischemic retinopathies. *Cold Spring Harb Perspect Med.* 2012; 2:a006411.
2. Dossarps D, Bron AM, Koehrer P, Aho-GléléLS, Creuzot-Garcher C, Berthon L, et al. Endophthalmitis after intravitreal injections: incidence, presentation, management, and visual outcome. *Am J Ophthalmol.* 2015; 160:17-25.
3. Kernt M, Kampik A. Endophthalmitis: pathogenesis, clinical presentation, management, and perspectives. *Clin Ophthalmol.* 2010; 4:121.
4. Englander M, Chen TC, Paschalis EI, Miller JW, Kim IK. Intravitreal injections at the Massachusetts Eye and Ear Infirmary: analysis of treatment indications and postinjection endophthalmitis rates. *Br J Ophthalmol.* 2013; 97:460-5.
5. Mason JO, White MF, Feist RM, Thomley ML, Albert MA, Persaud TO, et al. Incidence of acute onset endophthalmitis following intravitreal bevacizumab (Avastin) injection. *Retina.* 2008; 28:564-7.
6. Zafar S, Hamid A, Mahmood SU, Burq MA, Maqsood N. Incidence of endophthalmitis after intravitreal injections at a tertiary care hospital. *Can J Ophthalmol.* 2018; 53:94-7.
7. Fileta JB, Scott IU, Flynn HW. Meta-analysis of infectious endophthalmitis after intravitreal injection of anti-vascular endothelial growth factor agents. *Ophthalmic Surg Lasers Imaging Retina* 2014; 1:45:143-9.
8. Lyall DA, Tey A, Foot B, Roxburgh ST, Viridi M, Robertson C, et al. Post-intravitreal anti-VEGF endophthalmitis in the United Kingdom: incidence, features, risk factors, and outcomes. *Eye (Lond).* 2012; 26:1517-26.
9. Pilli S, Kotsolis A, Spaide RF, Slakter J, Freund KB, Sorenson J, et al. Endophthalmitis associated with intravitreal anti-vascular endothelial growth factor therapy injections in an office setting. *Am J Ophthalmol.* 2008; 145:879-82.
10. Mithal K, Mathai A, Pathengay A, Jalali S, Relhan N, Motukupally SR, et al. Endophthalmitis following intravitreal anti-VEGF injections in ambulatory surgical centre facility: incidence, management and outcome. *Br J Ophthalmol.* 2013; 97:1609-12.
11. Brynskov T, Kemp H, Sørensen TL. No cases of endophthalmitis after 20,293 intravitreal injections in an operating room setting. *Retina.* 2014; 34:951-7.
12. Nentwich MM, Yactayo-Miranda Y, Schwarzbach F, Wolf A, Kampik A, de Kaspar HM. ENDOPHTHALMITIS AFTER INTRAVITREAL INJECTION: Decreasing Incidence and Clinical Outcome-8-year Results from a Tertiary Ophthalmic Referral Center. *Retina.* 2014; 34:943-50.
13. Haider MA, Imtiaz U, Javed F, Haider Z. Incidence of acute endophthalmitis after office based intravitreal bevacizumab injection. *J Pak Med Assoc.* 2017; 67:1917-9.
14. Lau PE, Jenkins KS, Layton CJ. Current Evidence for the Prevention of Endophthalmitis in Anti-VEGF Intravitreal Injections. *J Ophthalmol.* 2018; 2018:8567912.
15. Eyetech Study Group. Anti-vascular endothelial growth factor therapy for subfoveal choroidal neovascularization secondary to age-related macular degeneration: phase II study results. *Ophthalmology.* 2003; 110:979-86.
16. Brown DM, Michels M, Kaiser PK, Heier JS, Sy JP, Ianchulev T. Ranibizumab versus verteporfin photodynamic therapy for neovascular age-related macular degeneration: two-year results of the ANCHOR study. *Ophthalmology.* 2009; 116:57-65.e5.
17. Heier JS, Antoszyk AN, Pavan PR, Leff SR, Rosenfeld PJ, CiullaTA, et

- al. Ranibizumab for treatment of neovascular age-related macular degeneration: a phase I/II multicenter, controlled, multidose study. *Ophthalmology*. 2006; 113:633.e1-4.
18. Pilli S, Kotsolis A, Spaide RF, Slakter J, Freund KB, Sorenson J, et al. Endophthalmitis associated with intravitreal anti-vascular endothelial growth factor therapy injections in an office setting. *Am J Ophthalmol*. 2008; 1:145:879-82.
  19. Rosenfeld PJ, Brown DM, Heier JS, Boyer DS, Kaiser PK, Chung CY, et al. Ranibizumab for neovascular age-related macular degeneration. *N Engl J Med*. 2006; 5:355:1419-31.
  20. Scott IU, Flynn Jr HW. Reducing the risk of endophthalmitis following intravitreal injections. *Retina* 2007; 27: 10-12.
  21. Tabandeh H, Boscia F, Sborgia A, Ciraci L, Dayani P, Mariotti C, et al. Endophthalmitis associated with intravitreal injections: office-based setting and operating room setting. *Retina*. 2014; 1:34:18-23.
  22. Schimel AM, Scott IU, Flynn HW. Endophthalmitis after intravitreal injections: should the use of face masks be the standard of care? *Arch Ophthalmol*. 2011; 129:1607-9.
  23. Park Y, Kim KS, Park YH. Acute endophthalmitis after intravitreal injection and preventive effect of preoperative topical antibiotics. *J Ocul Pharmacol Ther*. 2013; 29:900-5.
  24. Speaker MG, Menikoff JA. Prophylaxis of endophthalmitis with topical povidone-iodine. *Ophthalmology*. 1991; 98:1769-75.
  25. Merani R, Hunyor AP. Endophthalmitis following intravitreal anti-vascular endothelial growth factor (VEGF) injection: a comprehensive review. *Int J Retina Vitreous*. 2015; 1:9.
-