

## Proximal Subclavian artery injury managed without performing median sternotomy: A case report

Zia Ur Rehman

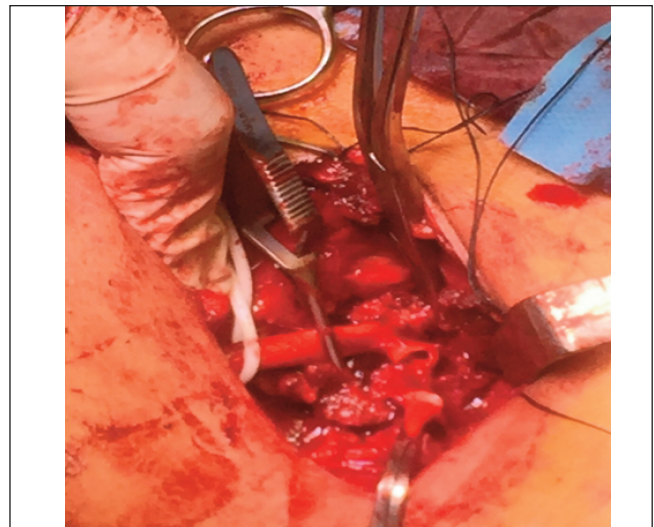
*Madam*, Subclavian artery runs from chest to upper arm and is in close proximity to many important structures in the limited space. Subclavian artery injuries are rare and tough to manage. It is challenging to achieve proximal arterial control which in most cases require median sternotomy with its associated morbidity. Iatrogenic injuries to subclavian artery can happen in a hostile operative field as with patients with large neck tumours. We present a 35-year-old male who had right subclavian artery injury during neck dissection which was repaired successfully via supra-clavicular approach.

Patient presented with gradually increasing mass in the neck for last 2 months. On FNAC it was reported as medullary cell carcinoma of thyroid. His preoperative CT scan showed tumour to be adherent to right carotid and subclavian arteries. Tumour was approached through right supraclavicular incision. While dissecting the right neck lymph nodes, there was troublesome bleeding. Bleeding was initially controlled by manual pressure and the tumour was dissected to improve exposure. Subclavian artery was noted to be disrupted from its junction with carotid artery (Figure 1). Through the same supraclavicular incision, with little more dissection, brachiocephalic artery was controlled thus avoiding sternotomy. Injured arterial edges were better defined, freshened and arterial defect was repaired with interposition polytetrafluoroethylene 6 mm graft (Figure 2). Patient recovered well after the procedure. He had functional limb with palpable pulses.

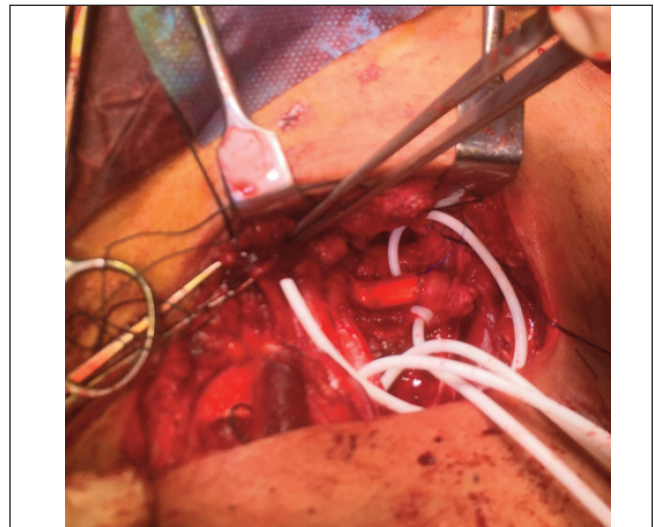
Traditionally, proximal control of right subclavian artery is achieved by median sternotomy and of left subclavian artery is achieved by left anterolateral thoracotomy.<sup>1</sup> Subclavian artery can be repaired both by open and endovascular means.<sup>2</sup> While open surgical repair has been the standard approach to date, endovascular approach is becoming more common which can be used both as therapeutic and as a 'bridge' to open repair.<sup>3</sup> Common surgical approaches include supraclavicular, infraclavicular, combined supra/infraclavicular, trap-door thoracotomy, median sternotomy and limited sternotomy. Supraclavicular approach is less morbid than sternotomy. This has been described for repairing these injuries.<sup>4</sup>

Department of Surgery, Aga Khan University Hospital, Karachi, Pakistan.

**Correspondence:** Zia Ur Rehman. e-mail: ziaur.rehman@aku.edu



**Figure-1:** Showing operating field, on the left is the head side of the patient while on the right is foot end of the patient. Clamps are placed on right subclavian artery (SCA), brachiocephalic trunk and Right Common Carotid Artery (CCA).



**Figure-2:** Showing repair of subclavian artery with interposition Polytetrafluoroethylene (PTFE) graft.

Subclavian artery can be repaired primarily, as patch repair or with interposition graft using either autologous or prosthetic graft.

Mortality with subclavian artery injuries range from 5% to 30% and is attributed to torrential bleeding and a high occurrence of associated injuries.

This case highlights that in 'selected' cases right subclavian artery can be controlled and repaired from supraclavicular approach, thus avoiding sternotomy and its morbidity.

**Disclaimer:** None.

**Conflict of Interest:** None.

**Funding Sources:** None.

## References

1. Trajbar T, Gverić T, Kosuta D, Ivkosić A, Pavić P, Zorčić I, et al. Iatrogenic injury of the brachiocephalic arterial trunk and its branches--case report. *Acta Med Croatica* 2006;60:497-9.
2. Elkbuli A, Shaikh S, McKenney M, Boneva D. Subclavian artery avulsion following blunt trauma: A case report and literature review. *Int J Surg Case Rep* 2019;61:157-60. doi: 10.1016/j.ijscr.2019.07.061.
3. Waller CJ, Cogbill TH, Kallies KJ, Ramirez LD, Cardenas JM, Todd SR, et al. Contemporary management of subclavian and axillary artery injuries-A Western Trauma Association multicenter review. *J Trauma Acute Care Surg* 2017;83:1023-31. doi: 10.1097/TA.0000000000001645.
4. Zhen P, Liu X, Li X. Surgical treatment of traumatic subclavian artery. *Zhongguo Xiu Fu Chong Jian Wai Ke Za Zhi* 2007;21:682-4.

<https://doi.org/10.47391/JPMA.1303>

---