

A new complication of femur head core decompression surgery: compartment syndrome

Sadettin Ciftci, Ali Gulec, Numan Mercan, Ahmet Yildirim

Abstract

The basic surgical treatment for avascular necrosis of the femur head is core decompression. In this report we discuss a case where the patient developed compartment syndrome after core decompression surgery with history of anticoagulant use. A 49-year-old man, who was using Coumadin 5 mg once daily due to aortic valve replacement and atrial fibrillation, had undergone core decompression surgery done due to stage 2 femur head avascular necrosis (AVN). He later developed isolated anterior thigh compartment syndrome for which fasciotomy was performed. Every surgical intervention to the extremities of patients with anticoagulant treatment should be considered high risk for compartment syndrome, even if appropriate precautions are taken. It is necessary to clinically observe for a sufficient duration to be able to identify symptoms.

Keywords: compartment syndrome, core de-compression, avascular necrosis.

DOI: <https://doi.org/10.5455/JPMA.36021>

Introduction

Femur head avascular necrosis (AVN) is a disease that progresses with necrotic areas and collapse of the femur head due to disrupted nutrition of the femur head. It finally results in degenerative arthritis of the hip joint, and most commonly affects people in their third to fifth decades of life.^{1,2}

Etiologic factors are divided into two basic groups: traumatic and non-traumatic. Steroid and alcohol use, coagulation disorders, hyperlipidaemia, smoking, storage diseases, autoimmune diseases and haematologic diseases may be encountered as causes of non-traumatic femur head avascular necrosis.¹

The Ficat-Arlet and Steinberg University staging systems are currently used, and may be helpful to estimate the progression of the disease and for selection of treatment.^{1,3}

Identification of the disease in the early stage is important to prevent collapse of the femur head. It is only possible to use non-surgical surveillance in the asymptomatic early

stage of femur head osteonecrosis.¹

Additionally, the optimal surgical treatment of femur head osteonecrosis has not been determined.¹ Surgical procedures to preserve femur-head include core decompression, vascularising and non-vascularising bone graft applications, rotational osteotomies, administration of stem-cells and assisting biological elements and tantalum rod applications.¹

In the period when the patient is symptomatic and positive on MRI before collapse, the basic surgical procedure that can be done is core decompression.¹ It may be performed along with vascular or non-vascular graft applications.⁴

Core decompression is a procedure of drilling the femur neck at an appropriate angle distal of the trochanter major. This intervention, recommended for young patients without collapse and with sturdy joint cartilage, ensures cleaning of the necrotic field up to the subchondral region, lowers intraosseous pressure and provides perfusion of the region.^{1,5}

Compartment syndrome is a clinical situation formed by increased interstitial fluid pressure in closed osseofascial cavities which results in disruption of microcirculation and tissue necrosis.⁶

Thigh compartment syndrome is a rare but serious condition for life and limb.⁷ When the compartment pressure is higher than 30 mmHg, the definite treatment for acute compartment syndrome is fasciotomy, that is performed to decompress the compartments and prevent critical ischaemia.⁸⁻¹⁰

Case Report

A 49-year-old man had core decompression procedure planned due to stage 2 avascular necrosis in the right femur head in September 2018 at Selçuk University School of Medicine (Figure 1-3). The patient's history included aorta valve replacement (AVR), aorta aneurysm and cerebral infarctus. He was on 5 mg Warfarin which was stopped 10 days prior to the operation and subcutaneous Enoxaparin was started. The patient was operated and a drain was inserted intraoperatively. On the third day after surgery monitoring of the drain was stopped. It was thought that haemorrhage control had been ensured and

Department of Orthopaedics, Selçuk University, Konya, Turkey
Correspondence: Sadettin Ciftci e-mail: dr.sadettinciftci@gmail.com

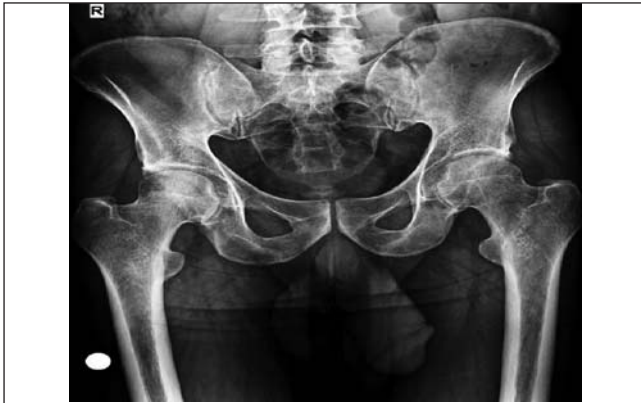

Figure-1: X-ray image of the patient with stage 2 avascular necrosis in the right femur head.

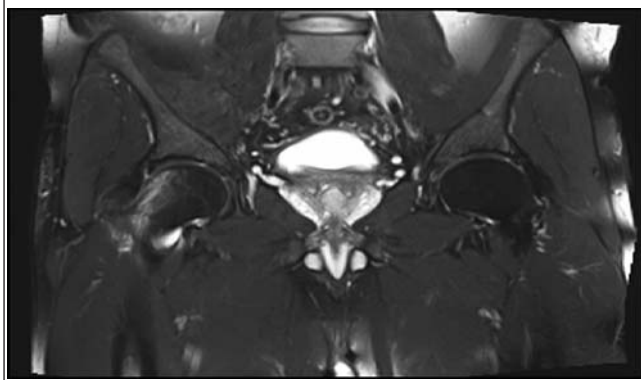


Figure-2: MR image of the patient with stage 2 avascular necrosis in the right femur head.

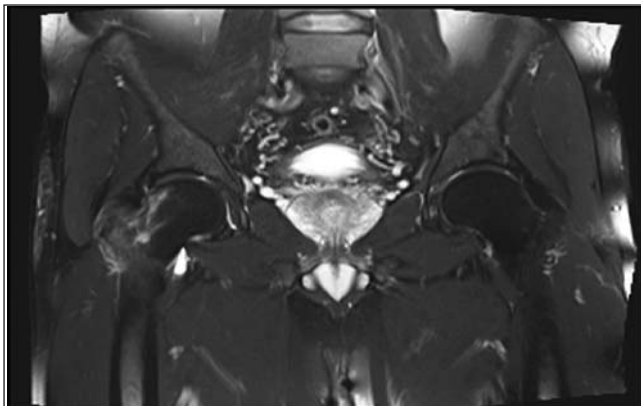


Figure-3: MR image of the patient with stage 2 avascular necrosis in the right femur head.

Warfarin was restarted. On the same day, the patient had increased swelling of the anterolateral thigh. With severe pain and tension, the patient underwent fasciotomy with a diagnosis of isolated thigh anterior compartment syndrome. After surgery a dramatic improvement occurred in the patient. After wound care for fasciotomy, as tension in the thigh was normal for three days, the incision line was

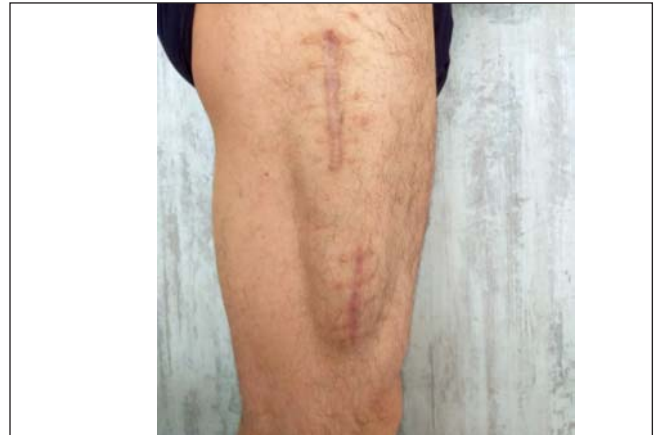

Figure-4: Fasciotomy incision scar with bulging vastus lateralis

sutured. The patient was discharged without problems for follow-up. After 10 months follow-up, the patient had no loss of muscle power, and problems related to avascular necrosis and pain had fully resolved. There were no problems besides fasciotomy incision scar and bulging of the vastus lateralis muscle linked to the fascia being open (Figure 4).

Discussion

There are three compartments in the thigh: the anterior, medial and posterior. These three compartments have larger dimensions than the lower leg and forearm and the degree of haemorrhage or oedema required to cause compartment syndrome in interstitial tissue is very high.¹¹ Compartment syndrome is rarely observed in the thigh compared to the lower leg and forearm.¹¹ It is reported to be most commonly observed in the anterior compartment of the thigh.

The susceptibility of patients treated with anticoagulants for haemorrhage is high with more chances of developing acute compartment syndrome.¹² The bioavailability of oral Warfarin is high and it reaches high blood concentrations about 90 minutes after administration.¹³ After the basic surgical treatment for femur head avascular necrosis of core decompression, patients are generally discharged early. However, no matter how much care was taken in our case, complication of compartment syndrome, which we did not find in the literature, occurred after core decompression and this situation was associated with Warfarin administration. Early treatment of patients with compartment syndrome with fasciotomy may prevent major complications and residual deficits.¹²

Conclusion

The risk of encountering aggressive complications like compartment syndrome after every intervention to the extremities of patients receiving Warfarin should be

considered. If possible, drainage should be inserted and we believe it is necessary to ensure sufficient duration of clinical observation to identify clinical symptoms after the drain is removed.

Disclaimer: None to declare.

Conflict of Interest: None to declare.

Funding Sources: None to declare.

References

1. Zalavras CG, Lieberman JR. Osteonecrosis of the femoral head: evaluation and treatment. *J Am Acad Orthop Surg.* 2015; 23:69-70.
2. Lee MS, Hsieh PH, Shih CH, Wang CJ. Non-traumatic osteonecrosis of the femoral head-from clinical to bench. *Chang Gung Med J.* 2010; 33:351-60.
3. Steinberg ME, Hayken GD, Steinberg DR. A quantitative system for staging avascular necrosis. *J Bone Joint Surg Br.* 1995; 77:34-41.
4. Plakseychuk AY, Kim SY, Park BC, Varitimidis SE, Rubash HE, Sotereanos DG. Vascularized compared with nonvascularized fibular grafting for the treatment of osteonecrosis of the femoral head. *J Bone Joint Surg Am.* 2003; 85:589-96.
5. Warner JJ, Philip JH, Brodsky GL, Thornhill TS. Studies of nontraumatic osteonecrosis. The role of core decompression in the treatment of nontraumatic osteonecrosis of the femoral head. *Clin Orthop Relat Res.* 1987; 225:104.
6. Tiwari A, Haq A, Myint F, Hamilton G. Acute compartment syndromes. *Br J Surg.* 2002; 89:397-412.
7. Mithöfer K, Lhowe DW, Vrahas MS, Altman DT, Altman GT. Clinical spectrum of acute compartment syndrome of the thigh and its relation to associated injuries. *Clin Orthop Relat Res.* 2004; 425:223-9.
8. Fouasson-Chailloux A, Menu P, Dauty M. Evaluation of Strength Recovery after Traumatic Acute Compartment Syndrome of the Thigh. A Case Study. *Ortop Traumatol Rehabil.* 2017; 19:379-82.
9. Von Keudell AG, Weaver MJ, Appleton PT, Bae DS, Dyer GS, Heng M, et al. Diagnosis and treatment of acute extremity compartment syndrome. *Lancet.* 2015; 386:1299-310.
10. Mauser N, Gissel H, Henderson C, Hao J, Hak DJ, Mauffrey C. Acute lower-leg compartment syndrome. *Orthopedics.* 2013; 36:619-24.
11. Wardi G, Görtz S, Snyder B. A case of delayed presentation of thigh compartment syndrome. *J Emerg Med.* 2014; 46:e145-8.
12. Titolo P, Milani P, Panero B, Ciclamini D, Colzani G, Artiaco S. Acute compartment syndrome of the arm after minor trauma in a patient with optimal range of oral anticoagulant therapy: a case report. *Case Rep Orthop.* 2014; 2014:980940.
13. Ansell J, Hirsh J, Poller L, Bussey H, Jacobson A, Hylek E. The pharmacology and management of the vitamin K antagonists: the Seventh ACCP Conference on Antithrombotic and Thrombolytic Therapy. *Chest.* 2004; 126:204S-33S.